Am J Hum Genet 32:396–413, 1980

Taurodontism, an Isolated Trait Associated with Syndromes and X-Chromosomal Aneuploidy

MARK T. JASPERS[1] AND CARL J. WITKOP, JR.[2]

SUMMARY

A review of the literature on teeth with enlarged pulp chambers and apical displacement of the bifurcation or trifurcation of roots (taurodontism) and investigation of the association of this trait with X-chromosomal aneuploidy shows that: (1) Taurodontism is not a rare trait in modern man, as indicated by the majority of recent reports, but occurs in approximately 2.5% of adult Caucasians. (2) Taurodontism occurs in syndromes, particularly in those having an ectodermal defect. (3) Among 12 patients showing taurodontic teeth radiographically, all had normal karyotypes. (4) Among 12 patients showing various combinations of X-chromosomal aneuploidy, 11 had taurodontic molars. (5) Patients with a female habitus and X-chromosomal aneuploidy as well as patients with a male habitus and X-chromosomal states have taurodontic teeth. (6) There is no simple association of the degree of taurodontism and the number of X chromosomes, but, in general, patients with the more severe forms of the trait—meso- or hypertaurodontism—are more likely to have X-chromosomal aneuploidy. While taurodontism may be viewed as an extension of a continuous trait of pulp chamber size, the extreme shape may arise when conditions disturbing the epithelial-derived root sheath produce a generalized amplified instability of development, as has been suggested from tissue culture studies of X-chromosomal aneuploid cells.

Received June 29, 1979.

This work was supported in part by grants GM-22167-04 and GM-24558-07 from the National Institutes of Health.

[1] Division of Oral and Maxillofacial Surgery, School of Dentistry, University of Minnesota, Minneapolis, MN 55455.

[2] Division of Human and Oral Genetics, School of Dentistry, University of Minnesota.

© 1980 by the American Society of Human Genetics. 0002-9297/80/3203-0008$01.50

REVIEW OF THE LITERATURE

Unusually shaped teeth having a cylindrical or prismatic form were described in remnants of prehistoric hominids in 1903 by de Terra [1], in 1907 by Gorjanovic-Kramberger [2] and Adloff [3], and in modern man in 1909 by Pickerill [4]. These observers noted that this tooth form was different from that usually seen in modern human dentitions, but no attempt was made by any of these authors to name these peculiar teeth.

In 1913, Keith [5] coined the term "taurodontism" to describe this unusual tooth form. Keith defined taurodontism as "a tendency for the body of the tooth to enlarge at the expense of the roots. It is a tendency to assume the condition seen in the ox." The term's origin is from the Greek *tauros*, which means "bull," and *odontos*, which refers to "tooth." Keith termed the "opposite condition"—that seen in the teeth of carnivora, where the body of the tooth is above the alveolar border: "cynodontism" or doglike teeth (fig. 1). Shaw [6], in 1928, classified subtypes of the condition as "hypotaurodontism," "mesotaurodontism," and "hypertaurodontism" to more accurately define the degree to which this condition is manifest (fig. 2). Witkop [7] defined taurodontism thus: "Taurodont teeth have pulp chambers in which the bifurcation or trifurcation is displaced apically, so that the chamber has a greater apico-occlusal height than in cynodont teeth and lacks a constriction at the level of the cementoenamel junction. The distance from the bifurcation or trifurcation of the roots to the cementoenamel junction is greater than the occlusal-cervical distance."

The first report of taurodontism in modern man's dentition was published in 1909 by Pickerill [4], who used the term "radicular dentinoma" to describe the condition. He described two maxillary first molars exhibiting an overall cuboidal or "bale" shape with normal crowns, and one central quadrilateral-shaped pulp cavity instead of individual root canals.

Following this initial case report, no other reports of taurodontism appeared in the literature for approximately 50 years. Since Lunt's [8] description of a single tooth in

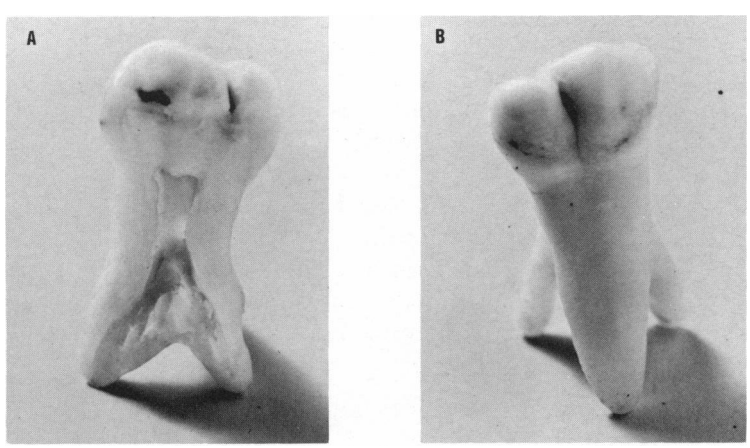

FIG. 1.—Taurodontic maxillary molar tooth. Note elongated pulp chamber (*A*) and apically positioned trifurcation (*B*).

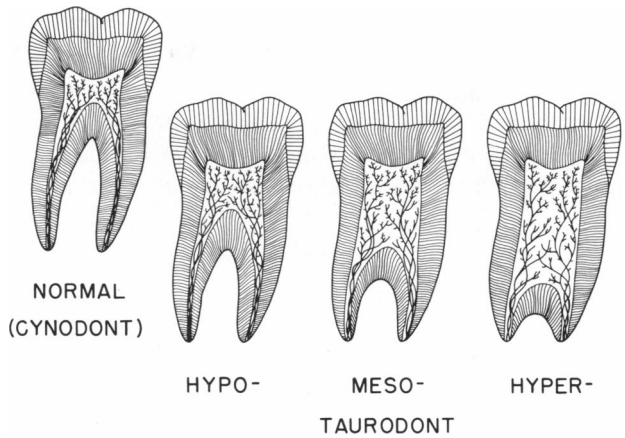

FIG. 2.—Diagrammatic representation of normal (cynodontic) tooth and three subclasses of taurodontic teeth as proposed by Shaw [6].

1954, the recent literature contains not infrequent reports of taurodontism as an isolated oddity, a familial trait, a trait with high frequency in Eskimos [9, 10], and associated with several types of other systemic disturbances [11]. These case reports are summarized in table 1.

Etiology and Pathogenesis

Theories concerning the etiology of taurodontism have varied: "a specialized or retrograde character" [3]; a primitive pattern [66, 67]; a Mendelian recessive [6, 25]; an atavistic feature [68]; and, "without doubt, a mutation" [69]. Other theories include: a continuous trait without discrete modes of expression [32, 70], an "X-linked" system [21], "familial in nature" [30], and an autosomal dominant trait, at least when associated with amelogenesis imperfecta or the trichodentoosseous (TDO) syndrome [32, 44, 46, 48, 51–53]. Witkop [7, 11] and Witkop and Sauk [71] stated that while some kindreds exhibiting taurodontism associated with amelogenesis imperfecta or the TDO syndrome indicate an autosomal dominant mode of inheritance, the inheritance of taurodontism as an isolated trait is less clear. Ackerman et al. [32] feel that the morphology of the roots of teeth is primarily determined genetically but that it may be modified environmentally.

Explanations of the pathogenesis of taurodont formation include "an unusual developmental pattern" [72]; a delay in calcification of the pulp chamber floor [72, 73]; an odontoblastic deficiency [69]; an alteration in Hertwig's epithelial root sheath, with an apparent failure of the epithelial diaphragm to invaginate at the normal horizontal level [16]; and "a delayed or incomplete union of the horizontal flaps of the epithelial diaphragm" [30].

Objective Measurement of Taurodontism

Several attempts have been made to define the term "taurodontism" objectively. These attempts followed Shaw's subclassification of taurodont teeth into hyper-.

meso-, and hypo- types. Keene [74] attempted to define certain radiographic features of mandibular root morphology in biometric terms in a study of 247 white males. He developed a "taurodontism index" by comparing the vertical height of the pulp chamber to the vertical height of the tooth portion containing the pulp. Using this index, Keene [74] was able to biometrically define Shaw's hypo-, meso-, and hypertaurodont teeth. Keene's "taurodontism index," however, was criticized by Stenvik et al. [38], who felt that a biometric description of taurodontism such as Keene's did not consider the changes in the size of the pulp chamber brought about by physiological aging.

Blumberg et al. [70] attempted to define taurodontism by the use of metrical attributes which were considered not likely to be influenced by environmental factors. From a population sample of 200 individuals, a discriminant analysis was developed. Through this analysis, the authors were able to distinguish certain tooth dimensions that permitted distinguishing between taurodontic and nontaurodontic molars. The analysis found no influence on the sample from caries, sex, or age, but did find differences due to race. The dimensions utilized are constant throughout life and are unaffected by aging or wear.

In their work with this discriminant analysis, however, Blumberg et al. [70] initially selected teeth with elongated pulp chambers from their population using subjective criteria. These teeth were termed taurodontic; teeth subjectively considered normal were classified nontaurodontic. These two populations formed the basis for the development of the discriminant analysis. Since the precise point at which a tooth must be considered taurodontic had not been established, the discriminant method relied upon the subjective criteria utilized by the authors.

It seems reasonable, then, to suggest that since pulp chamber elongation is probably a continuum, the point at which a tooth is termed taurodontic must rely on arbitrary criteria. This reliance on arbitrary criteria fosters disagreement among various studies of this dental trait.

Prevalence of Taurodontism

The prevalence of taurodontism reported in modern-day populations has varied from 0.54% in the primary dentitions of Japanese children [28] to as high as 5.6% in the permanent dentitions of Israeli adults [35]. The criteria for the diagnosis of taurodontism and the criteria for patient selection differed in all of the studies. Daito and Hieda [28] examined the dental radiographs of the primary dentitions of 2,300 boys and 3,800 girls in Japan. Thirty-three (0.54%) of the children had taurodontic primary molars (11 boys, 22 girls). They found 14 hyper-, 45 meso-, and 18 hypotaurodontic molars among the 33 children. The primary mandibular first molar was the tooth most frequently involved. Keene [74] found hypotaurodontic teeth in 2.8% and meso-taurodontic teeth in 0.4% of 247 male navy recruits. All examples of the trait were found in mandibular second molars. Blumberg et al. [70] found approximately 2.5% (295 of 11,905) of the patients in their study had the trait. Studt [75] found the condition in 0.9% (46 of 5,000) of dental patients from 7 to 90 years. Shifman and Chanannel [35] examined the dental radiographs of Israeli adults ages 20 to 30 and found that 5.6% (68 of 1,200) had the trait: 62 (5.2%) had hypotaurodontism, 12 (1%)

TABLE 1

PATIENTS FROM LITERATURE WITH (A) ISOLATED TAURODONTISM, (B) TAURODONTISM ASSOCIATED WITH SYNDROMES, OR (C) CHROMOSOMAL ANOMALIES

(A) Isolated taurodontism

AUTHOR	NO. AND TYPE OF PATIENTS				EVIDENCE FOR GENETIC OR FAMILIAL ASSOCIATION (ONLY EXAMINED PATIENTS SHOWN)
	No.	Age	Sex	Country or race	
Lunt (1954) [8]	1 (tooth)	...	...	Caucasian	Not indicated
Miles (1954) [12]	1 (tooth)	...	...	Caucasian	" "
Tobias (1955) [13]	1 (skull)	...	...	Bantu	" "
Mangion (1962) [14]	2	20+	M	Maltese	Unrelated
Manson-Hing (1963) [15]	1	Adult	M	Afro-American	Not indicated
Hamner et al. (1964) [16] (Metro, same case, 1965) [17]	1	13	F	Caucasian	" "
Lysell (1965) [18]	1	Child (primary molars)	M	...	" "
Tennant (1966) [19]	1	Adult	...	...	None
Pettenella (1966) [20]	1	Adult	M	Caucasian	Not indicated
	2	Adult	M/F	Caucasian	" "
Gamer & Zusman (1967) [21]	2	(Kindred)	...	Caucasian	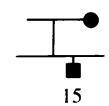
Haunfelder (1967) [22]	1	22	M	Caucasian	Not indicated
Miller (1969) [23]	1	9	F	Welsh	" "
Bernick (1970) [24]	2	(Kindred)	...	...	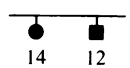
Mena (1971) [25]	5	(Kindred)	...	Afro-American	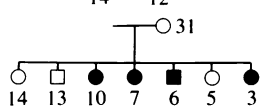
Lehtinen (1971) [26]	3	(Kindred)	...	Finnish	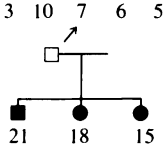

Webster (1971) [27]	1	3	M	Caucasian	Not indicated
Daito and Hieda (1971) [28]	11 (M) 22 (F)	Children (primary teeth)	M/F	Japanese	" "
Regattieri and Llewellyn (1972) [29]	1	7	F	Afro-American	" "
Goldstein and Gottlieb (1973) [30]	···	(Kindred)	···	Afro-American	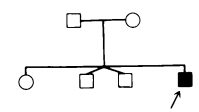
	1	8½	M	Caucasian	Not indicated
	···	(Kindred)	···	Caucasian	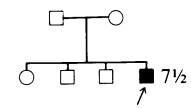
	···	(Kindred)	···	Caucasian	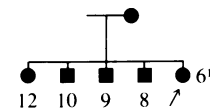
	···	(Kindred)	···	Caucasian	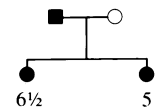
Mednick (1973) [31]	1	7	F	Caucasian	Not indicated
Ackerman et al.* (1973) [32]	···	(Kindred)	···	Caucasian	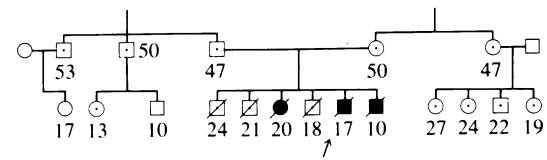
Shifman and Buchner (1976) [33]	16	?	?	Israeli	Unrelated
Barker (1976) [34]	1	12	F	Caucasian	Not indicated
Shifman & Chanannel (1978) [35]	68	···	M5/F6 ratio	Israeli	" "

(TABLE 1 continued on next page)

TABLE 1 (*continued*)

(B) Taurodontism associated with syndromes

Syndrome	Author	No. patients	Familial association	Inheritance
Oral-facial-digital syndrome 11 (Mohr)	Goldstein and Gottlieb (1973) [30] also, Goldstein and Medina (1974) [36]	2	Sibs	Autosomal recessive
Scanty hair, oligodontia, taurodontia (SOT syndrome)	Stoy (1960) [37]	2	Unrelated	Unknown; possibly autosomal recessive
	Haunfelder (1967) [22]	2	Sibs	"
	Stenvik et al. (1972) [38]	3	Sibs	"
	Moller et al. (1973) [39]	1	None	"
Microdontia, taurodontia, dens invaginatus (Casamassimo syndrome)	Casamassimo et al. (1978) [40]	2 + 4 by History	Kindred 4 generations	X-linked
Microcephalic dwarfism, taurodontism, root resorption (Sauk syndrome)	Sauk and Delaney (1973) [41]	1	None	Unknown (X-linked or autosomal recessive?), Two other unreported cases are male
	Gardner and Girgis (1977) [42]	1	...	
Amelogenesis imperfecta, hypomaturation—pitting hypoplastic with taurodontism	Fischer (1961) [43]	...	Kindred 3 generations	Autosomal dominant
	Winter et al. (1969) [44]	10	Kindred 4 generations	"
	Widerman and Serene (1971) [45]	1	...	"
	Congelton and Burkes (1979) [46]	4	Kindred	"
		3	Kindred	"
		4	Kindred	"
Amelogenesis imperfecta, hypomaturation type	Gage (1978) [47]	1	Kindred	X-linked
Trichodentoosseous syndrome (TDO syndrome)	Robinson et al. (1966) [48]	1	Kindred	Autosomal dominant
	Crawford (1970) [49]	2	Sibs	"
	Mjör (1972) [50]	1	...	"
	Lichtenstein and Warson (1971) [51]; also, Lichtenstein et al. (1972) [52] and Jorgenson and Warson (1973) [53]	9	Kindred	"
	Parker et al. (1975) [54]	3	Sibs	"
	Gulmen and Pullon (1976) [55]	3	Kindred	"
	Melnick et al. (1977) [56]	19	Kindred	"
Trichoonychodental syndrome (TOD syndrome)	Siirila and Heikinheimo (1962) [57]	4	Kindred	"
	Koshiba et al. (1978) [58]	3	Kindred	"

(C) Taurodontism associated with chromosomal anomalies

Author	No. associated characteristics	Age	Country or race	Karyotype
Melosky (1966) [59]	6	...	Caucasian	Klinefelter
Hieda and Daito (1971) [60]	1	Primary teeth	Japanese	47,XXY
Witkop (1971) [7]	1	29	Caucasian	49,XXXXY
Mednick (1973) [31]	1	9½	Afro-American	47,XXY
Keeler (1973) [61]	6: shovel-shaped incisors	24	Caucasian	47,XXY
		17	Caucasian	47,XXY
		25	Caucasian	47,XXY
		24	Negro	48,XXXY
		24	Caucasian	48,XXYY
		25	Negro	49,XXXXY/48,XXXY
Stewart (1974) [62]	2	16	Caucasian	47,XXY
		8	Caucasian	49,XXXXY
Feichtinger and Rossiwall (1977) [63]	1	14	Caucasian	47,XXY/48,XXXY
	(Taurodontism not found in seven patients)			
		20	Caucasian	47,XXY
		23	Caucasian	47,XXY
		16	Caucasian	47,XXY
		26	Caucasian	47,XXY
		20	Caucasian	47,XXY
		19	Caucasian	47,XYY/48,XXYY
		13	Caucasian	47,XXX
Gage (1978) [47]	2: hypomature/hypoplastic enamel	20	Caucasian	47,XXY
	hypoplastic pitting enamel	30	Caucasian	47,XXY
Gardner and Girgis (1978) [64]	3: shovel-shaped incisors	27	Caucasian	49,XXXXY
	T-shaped maxillary central incisor	10	Caucasian	49,XXXXY
	shovel-shaped incisor	22	Caucasian	49,XXXXY
Stewart et al. (1971) [65]	1: dyschondrosteosis	5½	Caucasian	45,XX,−G,18q+

* Kindred may represent syndromal association or homozygous state if single gene is assumed for taurodontism.

† ⊙ Taurodont cuneiform or fused roots, ■ cuneiform, ⊘ lip anomalies —other defects.

had mesotaurodontism, and 3 (0.2%) had hypertaurodontism. Of 10,204 molar teeth in the 1,200 patients, 1.5% were taurodontic. The mandibular second molar was involved in two-thirds of all cases. Witkop [11] found hypertaurodontism in 16 of 2,800 (0.57%) of patients ages 15 to 35 admitted for treatment at the Clinical Center, National Institutes of Health. A conservative interpretation of the results of these studies combined suggests that taurodontism occurs in approximately 2.5% of the adult Caucasian population and that the mandibular second molar is the most frequently involved tooth in the dentition.

A summary of the literature indicates that taurodontism occurs as an isolated trait with predilection for association in certain familial groups with common racial, geographical, and ethnic backgrounds; in certain syndromes with greater than expected frequency; and in patients with a male habitus and aneuploidy of the X chromosome.

To date, there has been no published work regarding the occurrence of taurodontism in females exhibiting aneuploidy of the X chromosome or any data on the occurrence of taurodontism in the genotypically normal patient. The purpose of this study was to investigate the occurrence of X-chromosomal aneuploidy in a population of patients selected for taurodontism, to determine the occurrence of taurodontism in a randomly selected population of dental patients, to study further the occurrence of this trait in phenotypic males exhibiting aneuploidy of the X chromosome, and to investigate the occurrence of taurodontism in phenotypic females exhibiting aneuploidy of the X chromosome.

MATERIALS AND METHODS

Materials

To determine the occurrence of chromosomal abnormalities in patients selected for taurodontism. A subjective evaluation of radiographs from patients randomly presenting for dental treatment at the dental clinic was conducted. Teeth exhibiting elongated pulp chambers were examined to determine if these teeth represented taurodontic types. Those patients found to exhibit taurodontism in one or more molars were examined for evidence of syndromal disease and karyotyped to determine the presence of chromosomal abnormalities, particularly X-chromosomal aneuploidy. Twelve individuals (four males and eight females) were thus examined.

To determine the occurrence of taurodontism in a randomly selected population. Dental records on 100 individuals were randomly withdrawn from the patient files of the University of Minnesota School of Dentistry and of the University of Minnesota Student Health Service. Dental radiographs on these 100 individuals were subjectively analyzed for the presence of teeth with enlarged pulp chambers.

To study the occurrence of taurodontism in phenotypic males exhibiting aneuploidy of the X chromosome. Male patients previously diagnosed as exhibiting aneuploidy of the X chromosome were evaluated radiographically for taurodontic molars. Nine such patients were examined.

To study the occurrence of taurodontism in phenotypic females exhibiting aneuploidy of the X chromosome. Female patients previously diagnosed as exhibiting aneuploidy of the X chromosome were evaluated radiographically for taurodontic molars. Three such patients were examined.

Methods

Radiographs of the individual dentitions were examined independently by the senior author and three additional dentists. These individuals were requested to classify each dentition as normal, hypo-, meso-, or hypertaurodontic, each being supplied with a diagram illustrating

Shaw's classification of taurodontic teeth. Any dentition containing one or more mandibular molar teeth exhibiting a form of taurodontism was considered a taurodontic dentition. These four independent judgments were used as follows: If three of the four judges considered a dentition as taurodontic, it was accepted as such. Subclasses of taurodontism were determined by accepting the major opinion or, in case of a tie, the lesser degree of the trait. Karyotypic examinations were performed on cultured leukocytes using standard methods* by the Cytogenetic Laboratory, Oral Pathology and Human and Oral Genetics, School of Dentistry, University of Minnesota.

RESULTS

Occurrence of Chromosomal Abnormalities in Patients Screened for Taurodontism

Individual patient data for all patients included in this study are summarized in tables 2 and 3. Figures 3, 4, and 5 illustrate the radiographic appearance of the taurodontic types.

All 12 individuals with radiographic evidence of elongated pulp chambers (table 2) were judged to exhibit taurodontism: nine (three males and six females) were found to exhibit hypotaurodontism and three (one male and two females) exhibited at least mesotaurodontism. None had evidence of amelogenesis imperfecta, ectodermal defects, or other syndromal associations. Subsequent chromosomal examination of these twelve individuals revealed normal karyotypes in all cases.

Occurrence of Taurodontism in a Randomly Selected Population

Of the 100 individuals whose dental radiographs were subjectively examined by the senior author, two were found to exhibit taurodontic teeth.

Occurrence of Taurodontism in Phenotypic Males Exhibiting Aneuploidy of the X Chromosome

Nine phenotypic males exhibiting a variety of X-chromosomal anomalies were examined. Two patients (nos. 15 and 17, table 3) exhibited a 47,XXY karyotype; one patient (no. 13) exhibited a translocation defect; one patient (no. 14) was a mosaic 47,XXY/48,XXYY; one patient (no. 16) exhibited a karyotype of 46,XX (also called "XX male"); two patients (nos. 19 and 21) were 48,XXYY Klinefelter variants; one patient (no. 18) was a mosaic 48,XXXY/49,XXXXY; and one patient (no. 20) had an XXXY karyotype.

The dental radiographs of these nine phenotypic males were examined for taurodontism. Eight individuals exhibited taurodontism: six were judged hypo-, one meso-, and one hypertaurodontic. One individual was judged to exhibit a nontaurodontic dentition.

Occurrence of Taurodontism in Females Exhibiting Aneuploidy of the X Chromosome

Three phenotypic females (patients nos. 22, 23, and 24; table 3) were examined. Of these, one was mosaic 46,XX/47,XXX; one was 48,XXXX; and one was 47,XXX-ring 21. Dental radiographs of these three individuals were examined as outlined above. Two were judged hypo- and one was judged mesotaurodont (fig. 4).

---

* Hypotonic treatment by KCl solution and fixation by Carnoy fixative. Slides flame dried and Giemsa stained. Karyotypes constructed without banding.

TABLE 2

PATIENT DATA SUMMARY (TAURODONT SELECTED PATIENTS)

Patient no.	Race	Phenotype	Genotype	Subjective analysis
1	Caucasian	Female	46,XX	Hypo-
2	Caucasian	Male	46,XY	Hypo-
3	Caucasian	Female	46,XX	Meso-
4	Caucasian	Female	46,XX	Hypo-
5	Caucasian	Female	46,XX	Hypo-
6	Caucasian	Female	46,XX	Meso-
7	Caucasian	Male	46,XY	Meso-
8	Caucasian	Male	46,XY	Hypo-
9	Caucasian	Male	46,XY	Hypo-
10	Caucasian	Female	46,XX	Hypo-
11	Caucasian	Female	46,XX	Hypo-
12	Caucasian	Female	46,XX	Hypo-

DISCUSSION

Taurodontism, while an unusual dental variation from the normal cynodontic tooth, is probably not as rare as formerly thought. Taurodontism occurs in approximately 2% of the Caucasian population as indicated by a study of 11,905 persons by Blumberg et al. [70] and by the much smaller sample in the present study.

Whether the isolated trait has a polygenic or a single gene inheritance (dominant or recessive) is unknown, since studies and kindreds from the literature (table 1) are compatible with both. Further studies are required to resolve this point and to address the possibility that isolated taurodontism is a genetically heterogeneous trait.

Taurodontism, in and by itself, cannot be considered a hallmark of X-chromosome aneuploidy. Twelve patients selected for taurodontism had normal karyotypes. Any screening procedure for aneuploidy of the X chromosome which utilizes taurodontism as a criterion must consider that a significant proportion of the karyotypically normal Caucasian population has this trait. However, in two incidences, not included in this study, we have found patients with aneuploidy of the X chromosome (47,XXY/

TABLE 3

PATIENT DATA SUMMARY (ANEUPLOID-X SELECTED PATIENTS)

Patient no.	Race	Phenotype	Genotype	Subjective analysis
13	Caucasian	Male	X,t(X,22)Y	Hypo-
14	Caucasian	Male	47,XXX/48,XXYY	Hyper-
15	Caucasian	Male	47,XXY	Hypo-
22	Caucasian	Female	46,XX/47,XXX	Hypo-
23	Negro	Female	48,XXXX	Meso-
16	Caucasian	Male	46,XX	Hypo-
24	Caucasian	Female	47,XXX-Ring 21	Hypo-
17	Negro	Male	47,XXY	Hypo-
18	Negro	Male	48,XXXY/49,XXXXY	Meso-
19	Caucasian	Male	48,XXYY	Hypo-
20	Negro	Male	48,XXXY	Hypo-
21	Negro	Male	48,XXYY	Normal

FIG. 3.—Hypotaurodontic mandibular second molar (patient no. 4), 46,XX

48,XXXY and 48,XXXY/49,XXXXY) who were initially suspected on the basis of the extreme form—hypertaurodontism—seen on dental radiographs.

Patients with aneuploidy of the X chromosome with either a male or female habitus frequently show some degree of taurodontic configuration of their molar teeth. Eleven of 12 patients exhibiting X-chromosomal aneuploidy in this study were considered to have one or more taurodontic molars by judges with no knowledge of their karyotypic status. All three of the patients with a female habitus manifested the trait.

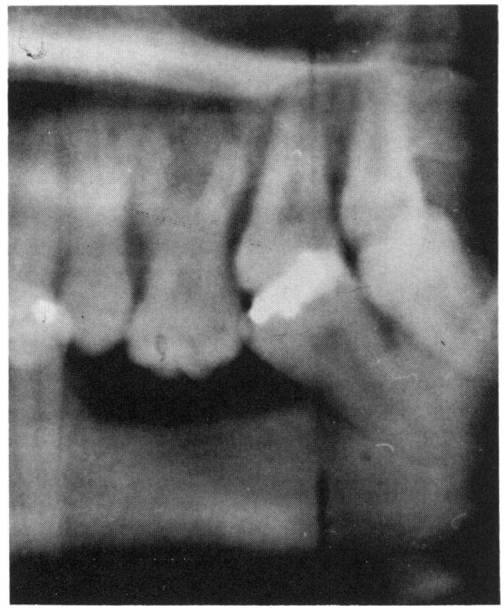

FIG. 4.—Mesotaurodontic maxillary first molar (patient no. 23), 48, XXXX

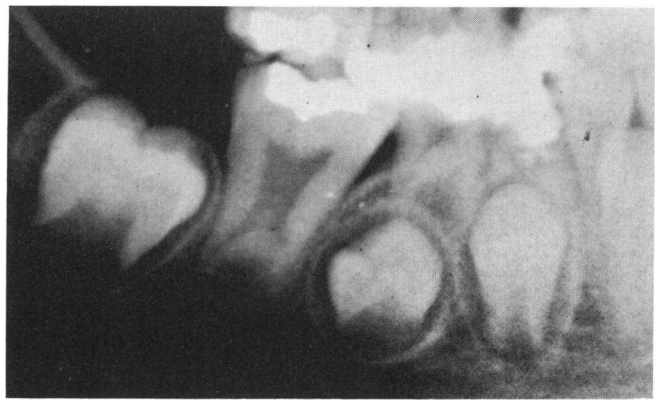

FIG. 5.—Hypertaurodontic mandibular second molar (patient no. 14), 47,XXX/48,XXYY

The relatively constant association of taurodontic teeth in X-chromosomal aneuploidy in the present study and in the studies of Keeler [61], Stewart [62], Gage [47], and Gardner and Girgis [64] has not been observed by other investigators. Melosky [59] found the trait in only six of 12 patients investigated, and Feichtinger and Rossiwall [63] found only one patient (47,XXY/48,XXXY) with taurodontic teeth among eight patients with X-chromosomal aneuploidy (table 1). Our study and a review of the published radiographs of patients with X-chromosomal aneuploidy seem to show that the nonsyndromal patient with the extreme form—hypertaurodontism—is more likely to be found to have X-chromosomal aneuploidy.

Close examination of the our results reveals no simple relationship between aneuploidy of the X chromosome and taurodontism. Since only one X chromosome of each somatic cell is genetically active (Lyon hypothesis), the expected prevalence of taurodontism in Klinefelter variants should be similar to the prevalence in the general population if the trait were determined by genetic material on a single X chromosome. If one assumes additive effects (through partial or late inactivation of the X chromosome) of the genetic material contained on the X chromosome, the degree of pulp chamber enlargement should increase in direct proportion to the number of X chromosomes. Our results seem to support this concept in seven of nine of the aneuploid-X male subjects and in all three of the aneuploid-X females. Two of the Klinefelter variants, however, manifest degrees of taurodontism not in keeping with this concept. Additionally, one would expect to find only relatively slight degrees of taurodontism in the karyotypically normal individuals. As noted above, three of the 12 (25%) karyotypically normal individuals in our study exhibited moderate (mesotaurodontism) degrees of pulp chamber enlargement.

The failure of these results to verify conclusively any additive or non-additive effects of sex chromosomal material, or to explain the relatively high percentage of taurodontism in the karyotypically normal population, leads us to consider an alternate explanation.

The frequent observance of enlarged pulp chambers in the dentition of individuals exhibiting aneuploidy of the X chromosome may not be due to the qualitative gene dosage effects but, rather, to a quantitative gene imbalance which disrupts developmental homeostasis.

The concept of developmental homeostasis was termed "canalization" by Waddington [76] when he suggested that developmental reactions in organisms are buffered or "canalized" to result in one end product regardless of minor variations in the environment. Shapiro [77] stated that developmental pathways are stabilized within standard developmental tracts by stabilizing or buffering systems. These systems rest ultimately on the evolved genic constitution of the individual.

Investigations into the disturbance of these stabilizing and buffering systems has been primarily concerned with autosomal trisomic conditions. Hall [78] in 1965, following a study of the abnormalities found in different trisomy syndromes, suggested that the quantitative genetic imbalance caused by the extra chromosome may be more important than its qualitative gene content. Shapiro [77] in 1970 suggested that the additional chromosome in trisomics upsets the stabilizing or buffering systems, resulting in a decreased buffering of the established developmental pathways. He termed this upset in the buffering systems "generalized amplified instability of development."

A possible mechanism for this "generalized amplified instability of development" was suggested by Hall [78] to be a factor such as delayed development. Mittwoch [79] also points out that delayed growth is characteristic in Down syndrome and other human trisomies. Recent findings by Mittwoch [79] indicate that cultured cells from patients with Down syndrome showed a slowing down of the mitotic cycle in vitro. This slowing implies fewer cells in the resultant organ. Subnormal numbers of cells in different organs have been reported not only in trisomy 21 but also in trisomies 13 and 18 [79].

When the sex chromosomes are considered, the same situation is suggested. Polani [80] found that the mitotic cycle time in 45,X cells may be shorter than in normal male and female cells. Barlow [81] obtained evidence which supports this possibility. Using fibroblast cultures grown from females mosaic for two different X-chromosome constitutions, cells with one X chromosome exhibited shorter mitotic cycle times than cells with either two or three X chromosomes. Barlow [81], working with X-chromosomal aneuploid conditions, maintained that each additional X chromosome reduces the total fingertip ridge count by about 29. He felt that the observed slowing of cell proliferation rate causes changes in cell behavior and, therefore, in the resultant phenotype. Mittwoch [80] stated that an X chromosome may affect growth processes in the embryo, as well as in later stages of development, even though all, or most, of its contained genes are genetically inactive. The presence of the additional X chromosome(s) has a quantitative effect on all proliferation and related processes, thereby producing an effect on the phenotype. Perhaps the slowing effect on cell reproduction of extra X chromosomes relates to the necessity of the heteropyknotic inactive chromosomes to unwind, replicate, and recondense, thus delaying the cell cycle.

A consideration of the foregoing findings suggests the following as a possible explanation of the increased incidence of taurodontism in X-chromosomal aneuploid

states. (1) Dental pulp chamber morphology is a continuous trait, lacking a "normal" discrete configuration or size. The point to which the pulp chamber must vertically enlarge to permit the tooth to be termed taurodontic is ill defined and based on subjective criteria alone. If pulp chamber morphology is indeed a continuous trait, it is probably subject to various environmental influences. Pulp chamber morphology is, therefore, subject to environmental variance and is less "canalized" than other, more buffered systems. (2) The presence of greater-than-normal sex chromosomal material, even though at least partially genetically inactive, can cause variations in the phenotype through its influence of the intracellular milieu. (3) The relatively high frequency of taurodontism in X-chromosomal aneuploid states may be a manifestation of developmental instability.

According to Shapiro [83], those traits in the "normal" population which possess relatively large environmental contributions to variability (in this case, pulp chamber morphology) are generally less stable than those traits with smaller environmental contributions. If this instability is amplified by surplus chromosomal material, it is expected that the less stable trait would be more deviant than more stable ones.

The particular mechanism of this instability or environmental variance may be an alteration or slowing of cell proliferation rates at least at certain stages of development. This alteration may result, therefore, in altered development and subsequent morphological changes.

Hamner et al. [16] stated that a taurodontic tooth results when the epithelial diaphragm fails to invaginate at the proper time in root formation. If this happens later than normal, a tooth with an elongated pulp chamber results. If, in the case of surplus sex chromosome conditions, cell proliferation rates are slower, it seems feasible that the invagination of the epithelial diaphragm would be delayed.

The concept of developmental instability may also explain the frequent occurrence of taurodontism with other ectodermal disturbances. The ectodermal cells establishing the outline form of the root and the induction of dentin, and, hence, secondarily, the pulp chamber form are probably also affected by the same changes which cause the other ectodermal disturbances. The frequent association of taurodontism with ectodermal disturbances and, particularly, with various forms of amelogenesis imperfecta may be through an alteration of the ectodermal cells which are involved in amelogenesis and, indirectly, in establishing pulp chamber morphology. The relative developmental instability of the configuration of pulp chambers indicates that this trait would be expected to exhibit alteration more frequently than other, more stable traits. Thus, enlarged pulp chambers may be expected to occur more frequently in the presence of ectodermal cell alterations.

ADDENDUM

Since this article was submitted, we obtained an additional case report from a foreign journal,* describing taurodontism in the primary and permanent dentitions of six individuals. Two of these individuals exhibit hypertaurodontism of the mandibular premolars, a condition not frequently seen.

* García-Godoy F, Armach FJ: Taurodontismo en Dentición Temporal y Permanente. Reporte de Casos. *Rev Dent (Santo Domingo)* 20:48–53, 1977.

ACKNOWLEDGMENTS

We wish to express our gratitude to Drs. Alyse Leyland, John J. Sauk, Jr., and Heddie O. Sedano for their assistance in the evaluation of dental radiographs, and to Drs. David Bixler, Hans Zellweger, Saburo Hara, and Clyde Keeler for information on patients with X-chromosomal aneuploidy.

REFERENCES

1. DE TERRA M: Mitteilungen zum Krapina-Fund unter besonderer Berücksichtigung der Zähne, Schweiz. *Vierteljahrschr Zahnheilk* 13:11–23, 1903
2. GORJANOVIC-KRAMBERGER ⌂: Die Kronen und Wurzeln der Mahlzähne des Homo primigenius und ihre genetische Bedeutung. *Anat Anz* 31:97–134, 1907
3. ADLOFF P: Die Zähne des Homo primigenius von Krapina. *Anat Anz* 31:273–282, 1907
4. PICKERILL HP: Radicular aberrations: bilateral radicular dentomata. *Proc Roy Soc Med (Odont Sec)* 2:150–152, 1909
5. KEITH A: Problems relating to the earlier forms of prehistoric man. *Proc Roy Soc Med (Odont Sec)* 6:103–119, 1913
6. SHAW JC: Taurodont teeth in South African races. *J Anat* 62:476–498, 1928
7. WITKOP CJ: Manifestations of genetic diseases in the human pulp. *Oral Surg* 32:278–283, 1971
8. LUNT DA: A case of taurodontism in a modern European molar. *Dent Rec* 74:307–312, 1954
9. PEDERSEN PO: *The East Greenland Eskimo Dentition, Meddeleser Om Grønland* 142:1–256. Copenhagen, CA Reizels Forlag, 1949
10. MOORREES CF: *A Correlative Study of Dental Characteristics in an Eskimoid People*. Cambridge, Mass., Harvard Univ. Press, 1957
11. WITKOP CJ JR: Clinical aspects of dental anomalies. *Int Dent J* 26:378–390, 1976
12. MILES AEW: Malformation of the teeth. *Proc Roy Soc Med (Odont Sec)* 47:817–826, 1954
13. TOBIAS P: Taurodontism in a Bushman skull from Kimberley. *Br Dent J* 98:352–355, 1955
14. MANGION JJ: Two cases of taurodontism in modern human jaws. *Br Dent J* 113:309–312, 1962
15. MANSON-HING LR: Taurodontism. *Oral Surg* 16:305, 1963
16. HAMNER JE, WITKOP CJ JR, METRO PS: Taurodontism. *Oral Surg* 18:409–418, 1964
17. METRO PS: Taurodontism: a dental rarity in modern man. *Oral Surg* 20:236–237, 1965
18. LYSELL L: Taurodontism in both dentitions. *Odont Revy* 16:359–362, 1965
19. TENNANT R: Taurodontism. *Dent Dig* 72:355–357, 1966
20. PETTENELLA L: Contributo allo studio del taurodontismo. *Mondo Odontostomatol* 8:40–46, 1966
21. GAMER S, ZUSMAN SH: Taurodontism in a 15-year-old boy and his mother. *J South Calif Dent Assoc* 35:441–444, 1967
22. HAUNFELDER D: Ein Beitrag zu den Molaren mit prismatischen Wurzeln (sog. Taurodontismus). *Dtsch Zahnaerzbl* 21:419–423, 1967
23. MILLER WA: Pulp calcifications in a taurodont tooth. *Br Dent J* 126:456–459, 1969
24. BERNICK SM: Taurodontism. *Oral Surg* 29:549, 1970
25. MENA CA: Taurodontism. *Oral Surg* 32:812–823, 1971
26. LEHTINEN R: Taurodontism. A report of a case with familiar occurrence. *Suom Hammaslääk Toim* 67:71–73, 1971
27. WEBSTER GM: Taurodontism in the primary dentition—a case report. *Chron Omaha Dist Dent Soc* 34:153–154, 1971
28. DAITO M, HIEDA T: Taurodont teeth in primary dentition. *Jpn J Pedodont* 9:94–106, 1971

29. REGATTIERI LR, LLEWELLYN JS: Taurodontism. *Oral Surg* 34:691, 1972
30. GOLDSTEIN E, GOTTLIEB MA: Taurodontism: familial tendencies demonstrated in eleven of fourteen case reports. *Oral Surg* 36:131–144, 1973
31. MEDNICK GA: Taurodontism and taurodontism in Klinefelter's syndrome. *J Mich Dent Assoc* 55:212–215, 1973
32. ACKERMAN JL, ACKERMAN AL, ACKERMAN AB: Taurodont, pyramidal, and fused molar roots associated with other anomalies in a kindred. *Am J Phys Anthropol* 38:681–694, 1973
33. SHIFMAN A, BUCHNER A: Taurodontism. *Oral Surg* 41:400–405, 1976
34. BARKER B: Taurodontism: the incidence and possible significance of the trait. *Aust Dent J* 21:272–276, 1976
35. SHIFMAN A, CHANANNEL I: Prevalence of taurodontism found in radiographic dental examination of 1,200 young adult Israeli patients. *Community Dent Oral Epidemiol* 6:200–203, 1978
36. GOLDSTEIN E, MEDINA JL: Mohr syndrome or oral-facial-digital II: report of two cases. *J Am Dent Assoc* 89:377–382, 1974
37. STOY PJ: Taurodontism associated with other dental abnormalities. *Dent Pract Dent Rec* 10:202–205, 1960
38. STENVIK A, ZACHRISSON BU, SVATUN B: Taurodontism and concomitant hypodontia in siblings. *Oral Surg* 33:841–845, 1972
39. MOLLER KT, GORLIN RJ, WEDGE B: Oligodontia, taurodontia, and sparse hair growth—a syndrome. *J Speech Hear Disord* 38:268–271, 1973
40. CASAMASSIMO PS, NOWAK AJ, ETTINGER RL, SCHLENKER DJ: An unusual triad: microdontia, taurodontia, and dens invaginatus. *Oral Surg* 45:107–112, 1978
41. SAUK JJ JR, DELANEY JR: Taurodontism, diminished root formation and microcephalic dwarfism. *Oral Surg* 36:231–235, 1973
42. GARDNER DG, GIRGIS BCHD: Taurodontism, short roots, and external resorption, associated with short stature and a small head. *Oral Surg* 44:271–273, 1977
43. FISCHER H: Die "prismatichen" Molaren von Krapina/Kroatien im Lichte rezenter Funde. *Dtsch Zahnaerztl Z* 16:8–15, 1961
44. WINTER GB, LEE KW, JOHNSON NW: Hereditary amelogenesis imperfecta, a rare autosomal dominant type. *Br Dent J* 127:157–164, 1969
45. WIDERMAN FH, SERENE TP: Endodontic therapy involving a taurodontic tooth. *Oral Surg* 32:618–620, 1971
46. CONGELTON JE, BURKES EJ: Amelogenesis imperfecta with taurodontism. *Oral Surg* 48:540–544, 1979
47. GAGE JP: Taurodontism and enamel hypomaturation associated with X-linked abnormalities. *Clin Genet* 14:159–164, 1978
48. ROBINSON GC, MILLER JR, WORTH HM: Hereditary enamel hypoplasia: its association with characteristic hair structure. *Pediatrics* 37:498–502, 1966
49. CRAWFORD JC: Concomitant taurodontism and amelogenesis imperfecta in the American Caucasian. *J Dent Child* 37:171–175, 1970
50. MJÖR IA: The structure of taurodont teeth. *J Dent Child* 39:459–463, 1972
51. LICHTENSTEIN JR, WARSON RW: Syndrome of dental anomalies, curly hair and sclerotic bones. *Birth Defects* 7(7):308–311, 1971
52. LICHTENSTEIN J, WARSON R, JORGENSON R, DORST JP, MCKUSICK VA: The trichodento-osseous (TDO) syndrome. *Am J Hum Genet* 24:569–582, 1972
53. JORGENSON RJ, WARSON RW: Dental abnormalities in the tricho-dento-osseous syndrome. *Oral Surg* 36:693–700, 1973
54. PARKER JL, REGATTIERI LR, THOMAS JP: Hypoplastic-hypomaturation amelogenesis imperfecta with taurodontism: report of case. *J Dent Child* 42:379–383, 1975
55. GULMEN S, PULLON PA: Tricho-dento-osseous syndrome. *J Endodont* 2:117–120, 1976
56. MELNICK M, SHIELDS ED, EL-KAFRAWY AH: Tricho-dento-osseous syndrome: a scanning electron microscopic analysis. *Clin Genet* 12:17–27, 1977

57. SIIRILA HS, HEIKINHEIMO O: Odontogenesis imperfecta. *Suom Hammaslääk Toim* 58:35–47, 1962
58. KOSHIBA H, KIMURA O, NAKATA M, WITKOP CJ JR: Clinical, genetic, and histologic features of the trichoonychodental (TOD) syndrome. *Oral Surg* 46:376–385, 1978
59. MELOSKY LC: A study of dentofacial aspects in individuals with X-chromosome aberrations. MSD thesis, Seattle, University of Washington, 1966
60. HIEDA T, DAITO M: Klinefelter's syndrome in a case of taurodontism. *Jpn J Pedodont* 9:79–85, 1971
61. KEELER C: Taurodont molars and shovel incisors in Klinefelter's syndrome. *J Hered* 64:234–236, 1973
62. STEWART RE: Taurodontism in X-chromosome aneuploid syndromes. *Clin Genet* 6:341–344, 1974
63. FEICHTINGER C, ROSSIWALL B: Taurodontism in human sex chromosome aneuploidy. *Arch Oral Biol* 22:327–329, 1977
64. GARDNER DG, GIRGIS BChD: Taurodontism, shovel-shaped incisors and the Klinefelter syndrome. *J Can Dent Assoc* 44:372–373, 1978
65. STEWART RE, LOVRIEN EW, WYANDT HE: Unusual dental findings in a patient with a rare bone dysplasia (dyschondrosteosis) and a chromosomal anomaly. *Oral Surg* 32:596–604, 1971
66. GREGORY WK: Origin and rise of man, the origin and evolution of the human dentition. *J Dent Res* 3:87–228, 1921
67. TRATMAN EK: A comparison of the teeth of people of Indo-European racial stock with the mongoloid racial stock. *Dent Rec* 70:31–53, 63–88, 1950
68. HRDLICKA A: The most ancient remains of man. *Rep Smithsonian Inst,* no. 2300, 1914 (cited by Mangion in [14])
69. BRABANT H, KOVACS I: *Bull Grp Int Rech Sci Stomat* 4:232, 1961 (cited by Mangion, in [14])
70. BLUMBERG JE, HYLANDER WL, GOEPP RA: Taurodontism: a biometric study. *Am J Phys Anthropol* 34:243–256, 1971; erratum 36:307–308, 1972
71. WITKOP CJ JR, SAUK JJ JR: *Dental and Oral Manifestations of Hereditary Disease*. Washington, D.C., Am Academy of Oral Pathology, 1971, pp 28–29
72. GLEISER I, HUNT EE: The permanent mandibular first molar, its calcification, eruption, and decay. *Am J Phys Anthropol* 13:253–284, 1955
73. KEITH A: *The Antiquity of Man*, 2nd ed. London, Williams and Norgate, 1925
74. KEENE HJ: A morphologic and biometric study of taurodontism in a contemporary population. *Am J Phys Anthropol* 25:208–209, 1966
75. STUDT KH: Taurodontism. A statistical survey of a dental clinic population. MSD thesis, Ames, University of Iowa, May, 1972
76. WADDINGTON CH: Canalization of development and the inheritance of acquired characters. *Nature* 150:563–565, 1942
77. SHAPIRO BL: Prenatal dental anomalies in mongolism: comments of the basis and implications of variability. *Ann NY Acad Sci* 171:562–577, 1970
78. HALL B: Delayed ontogenesis in human trisomy syndromes. *Hereditas* 52:334–344, 1967
79. MITTWOCH U: Mongolism and sex: a common problem of cell proliferation? *J Med Genet* 9:92–95, 1972
80. POLANI PE: Growing points in cell biology: cytogenetic aspects. *Proc Roy Soc Med* 63:955–959, 1970
81. BARLOW PW: X-chromosomes in human development. *Dev Med* 15:205–208, 1973
82. MITTWOCH U: *Genetics of Sex Differentiation*. New York, Academic Press, 1973
83. SHAPIRO BL: Amplified developmental instability in Down's syndrome. *Ann Hum Genet* 38:429–437, 1975