



# Effective Health Care Program

---

Technical Brief Number 11

## **Noninvasive Diagnostic Techniques for the Detection of Skin Cancers**



Agency for Healthcare Research and Quality  
Advancing Excellence in Health Care • [www.ahrq.gov](http://www.ahrq.gov)

## **Noninvasive Diagnostic Techniques for the Detection of Skin Cancers**

**Prepared for:**

Agency for Healthcare Research and Quality  
U.S. Department of Health and Human Services  
540 Gaither Road  
Rockville, MD 20850  
[www.ahrq.gov](http://www.ahrq.gov)

**Contract No. 290-2007-10055-1**

**Prepared by:**

Tufts University Evidence-based Practice Center  
Boston, MA

**Investigators:**

Susan K. Parsons, M.D., M.R.P., Project Lead  
Jeffery A. Chan, B.S.  
Winifred W. Yu, M.S., R.D.  
Ndidiamaka Obadan, M.D., M.Sc.  
Sara J. Ratichek, M.A.  
Jounghee Lee, Ph.D.  
Snila Sen, M.A., Editor  
Stanley Ip, M.D.

**AHRQ Publication No. 11-EHC085-EF  
September 2011**

This report is based on research conducted by the Tufts University Evidence-based Practice Center (EPC) under contract to the Agency for Healthcare Research and Quality (AHRQ), Rockville, MD (Contract No. 290-2007-10055-1). The findings and conclusions in this document are those of the author(s), who are responsible for its contents; the findings and conclusions do not necessarily represent the views of AHRQ. Therefore, no statement in this report should be construed as an official position of AHRQ or of the U.S. Department of Health and Human Services.

The information in this report is intended to help health care decisionmakers—patients and clinicians, health system leaders, and policymakers, among others—make well-informed decisions and thereby improve the quality of health care services. This report is not intended to be a substitute for the application of clinical judgment. Anyone who makes decisions concerning the provision of clinical care should consider this report in the same way as any medical reference and in conjunction with all other pertinent information, i.e., in the context of available resources and circumstances presented by individual patients.

This report may be used, in whole or in part, as the basis for development of clinical practice guidelines and other quality enhancement tools, or as a basis for reimbursement and coverage policies. AHRQ or U.S. Department of Health and Human Services endorsement of such derivative products may not be stated or implied.

This document is in the public domain and may be used and reprinted without permission except those copyrighted materials that are clearly noted in the document. Further reproduction of those copyrighted materials is prohibited without the specific permission of copyright holders.

Persons using assistive technology may not be able to fully access information in this report. For assistance contact [EffectiveHealthCare@ahrq.hhs.gov](mailto:EffectiveHealthCare@ahrq.hhs.gov).

None of the investigators has any affiliations or financial involvement that conflicts with the material presented in this report.

**Suggested citation:** Parsons SK, Chan JA, Yu WW, Obadan N, Ratichek SJ, Lee J, Sen S, Ip S. Noninvasive Diagnostic Techniques for the Detection of Skin Cancers. Technical Brief No. 11. (Prepared by the Tufts University Evidence-based Practice Center under Contract No. 290-2007-1055-1.) AHRQ Publication No. 11-EHC085-EF. Rockville, MD: Agency for Healthcare Research and Quality. September 2011. Available at: [www.effectivehealthcare.ahrq.gov/reports/final.cfm](http://www.effectivehealthcare.ahrq.gov/reports/final.cfm).

## Preface

The Agency for Healthcare Research and Quality (AHRQ) conducts the Effective Health Care Program as part of its mission to organize knowledge and make it available to inform decisions about healthcare. As part of the Medicare Prescription Drug, Improvement, and Modernization Act of 2003, Congress directed AHRQ to conduct and support research on the comparative outcomes, clinical effectiveness, and appropriateness of pharmaceuticals, devices, and healthcare services to meet the needs of Medicare, Medicaid, and the Children’s Health Insurance Program (CHIP).

AHRQ has an established network of Evidence-based Practice Centers (EPCs) that produce Evidence Reports/Technology Assessments and Comparative Effectiveness Reviews to assist public- and private-sector organizations in their efforts to improve the quality of health care. Technical Briefs are the most recent addition to this body of knowledge.

A Technical Brief provides an overview of key issues related to a clinical intervention or health care service—for example, current indications for the intervention, relevant patient population and subgroups of interest, outcomes measured, and contextual factors that may affect decisions regarding the intervention. Technical Briefs generally focus on interventions for which there are limited published data and too few completed protocol-driven studies to support definitive conclusions. The emphasis, therefore, is on providing an early objective description of the state of science, a potential framework for assessing the applications and implications of the new interventions, a summary of ongoing research, and information on future research needs.

Transparency and stakeholder input are essential to the Effective Health Care Program. Please visit the Web site ([www.effectivehealthcare.ahrq.gov](http://www.effectivehealthcare.ahrq.gov)) to see draft research questions and reports or to join an e-mail list to learn about new program products and opportunities for input. Comparative Effectiveness Reviews will be updated regularly, while Technical Briefs will serve to inform new research development efforts.

Carolyn M. Clancy, M.D.  
Director  
Agency for Healthcare Research and Quality

Jean Slutsky, P.A., M.S.P.H.  
Director, Center for Outcomes and Evidence  
Agency for Healthcare Research and Quality

Stephanie Chang, M.D., M.P.H.  
Director  
Evidence-based Practice Program  
Agency for Healthcare Research and Quality

Elisabeth U. Kato, M.D., M.R.P.  
Task Order Officer  
Center for Outcomes and Evidence  
Agency for Healthcare Research and Quality

## **Acknowledgments**

The team gratefully acknowledges the assistance of James Gaylor and Lina Kong Win Chang in completing this technical brief, and the participation of our key informants in framing the research.

# Noninvasive Diagnostic Techniques for the Detection of Skin Cancers

## Structured Abstract

**Background.** Cancers of the skin are the most common forms of cancer. Timely diagnosis and treatment are critical to reducing the rates of morbidity and mortality. Newer noninvasive imaging technologies may assist with earlier detection.

**Objective.** To provide an objective description of noninvasive imaging modalities in diagnosing cancerous tumors of the skin, to proffer an analytic framework for assessing the applications of the imaging modalities, to summarize the state of ongoing research, and to delineate future research needs.

**Methods.** We searched the MEDLINE<sup>®</sup> database for English-language literature published between 1990 and March 2011 for selected noninvasive imaging technologies. We included all publications types and study designs. We extracted data solely from relevant abstracts. Our search also included grey literature (manufacturers' Web sites, Food and Drug Administration's relevant databases, and ClinicalTrials.gov), and incorporated expert input from our key informants. Devices were classified as in general clinical use, limited clinical use, or investigational use, based on all available information.

**Findings.** We screened in 629 abstracts that were relevant to the noninvasive imaging technologies of interest. Only 11 abstracts were on randomized controlled trials. Of the devices in general clinical use, we found a total of 51 abstracts on photography and 433 on dermoscopy. Of note, only one abstract reported clinical outcomes. None of the abstracts reported adverse events. Photography is principally used in specialty and subspecialty settings (i.e., oncology) and while widely used by dermatologists, dermoscopy is still not used in primary care. We did not identify any consistent guidelines for the assessment of suspicious skin lesions. Devices in limited clinical use are principally used in research settings. Available literature was limited for these devices as well as those still considered investigational.

**Summary.** A review of the literature reveals predominant use of noninvasive devices by dermatologists with limited diffusion of this technology in primary care. When compared with the use of biopsy, future research is needed to evaluate the test accuracies, clinical impact, and the potential adverse events associated with the use of noninvasive imaging technologies.

# Contents

<b>Background</b> .....	1
Current and Emerging Modalities of Assessment and Diagnosis.....	1
Statement of Work/Objectives.....	2
<b>Guiding Questions</b> .....	3
Analytic Framework .....	4
<b>Methods</b> .....	6
Systematic Searches of the Published Literature .....	6
Searches of the Grey Literature .....	6
Interviews With Key Informants .....	7
Data Collection .....	7
Data Organization and Presentation.....	8
<b>Findings</b> .....	9
Devices in General Clinical Use .....	13
Photography .....	13
Available Literature .....	13
Description of Technique.....	13
Variations of Technique.....	15
Clinical Context of Use.....	15
FDA Status.....	16
Summary .....	16
Dermoscopy .....	16
Available Literature .....	16
Description of Technique.....	17
Variations of Technique.....	19
Clinical Context of Use.....	19
FDA Status.....	21
Summary .....	21
Devices in Limited Clinical Use .....	22
Confocal Microscopy.....	22
Available Literature .....	22
Description of Technique.....	22
Variations of Technique.....	23
FDA Status.....	24
Summary .....	24
Ultrasound/Laser Doppler.....	24
Available Literature .....	24
Description of Technique.....	24
Variations of Technique.....	25
FDA Status.....	26
Summary .....	26
Photodynamic Diagnosis .....	26
Available Literature .....	26
Description of Technique.....	27
Variations of Technique.....	27
FDA Status.....	27

Summary .....	28
Investigational Devices .....	28
Multiphoton Laser Scanning Microscopy.....	28
Electrical Bio-Impedance.....	28
Optical Coherence Tomography.....	29
Tape Stripping.....	29
Thermography.....	30
Multispectral Imaging and Fully Automated Computer-Based Analysis.....	30
<b>Summary and Implications</b> .....	31
<b>Next Steps</b> .....	33
<b>References</b> .....	34

## Tables

Table 1. Data Availability To Address the Elements of the Guiding Questions for the Different Diagnostic Technologies.....	10
Table 2. Algorithms Used in Dermoscopy .....	21

## Figures

Figure 1. Analytic Framework.....	5
Figure 2. Literature Flow Diagram .....	11
Figure 3. Distribution of All Abstracts by Study Type.....	12
Figure 4. Distribution of All Abstracts by Skin Cancer Type .....	13

## Appendixes

Appendix A. Search Strategies
Appendix B. Inclusion and Exclusion Criteria
Appendix C. FDA Clearance and Clinical Trials Status
Appendix D. Evidence Maps and Outcome Measures
Appendix E. Abbreviations



## Background

Cancers of the skin are the most common forms of cancer in men and women, and account for nearly half of all malignancies. In 2009, more than 1 million cases were expected in the United States.<sup>1</sup> Basal cell carcinoma (BCC) and squamous cell carcinoma (SCC), two types of nonmelanomatous lesions associated with aging and sun exposure, are responsible for more than 800,000 cases per year.<sup>1</sup> Recent studies have also linked nonmelanoma skin cancer (NMSC) to prior cancer therapy, especially radiation therapy.<sup>2</sup> While NMSC is rarely lethal, these lesions are associated with other malignancies (including hematologic and respiratory tract cancers).<sup>3</sup> In contrast, melanoma accounts for approximately 4 percent of all skin cancer cases, but causes the majority of skin cancer deaths.<sup>4</sup> One study found that melanoma incidence rates had doubled in all socioeconomic groups over a 10-year period.<sup>5</sup> Another study found that melanoma incidence rates have increased by 3 percent per year in white Hispanic and white non-Hispanic populations, and both white Hispanic and Black populations had more advanced disease at presentation.<sup>6</sup> Melanoma is associated with significant morbidity, and late stage melanoma with significant mortality due to the likelihood of metastatic spread.<sup>7,8</sup>

Therefore, timely diagnosis and treatment are critical to reducing rates of morbidity and mortality of all skin cancers. However, suboptimal diagnostic accuracy of current methods of lesion assessment (such as visual inspection) may lead to misleading false positives or conversely missed diagnoses, and the existing protocol of excisional biopsy of suspected lesions is an invasive, costly, and time-intensive procedure. Newer noninvasive screening and diagnostic modalities are available that may provide more precise imaging of suspected lesions and more accurate detection, thereby improving *in vivo* diagnosis. These newer technologies may, therefore, assist with earlier detection, eliminate unnecessary biopsies, and reduce costs and patient time spent in the physician's office.

## Current and Emerging Modalities of Assessment and Diagnosis

Several groups in Europe, North America, Australia, and New Zealand have developed guidelines for the screening and prevention of skin cancer.<sup>9-12</sup> According to a 2009 Guideline Synthesis, while there is general agreement that there is insufficient evidence to support screening of the general population for skin cancer, increased surveillance for individuals at higher risk is generally recommended.<sup>13</sup>

According to Goodson 2009, most dermatologists would agree that the goals of monitoring of nevi and detection of melanoma include the identification of high-risk patients, early biopsy of suspected melanomas, monitoring of nevi, and the avoidance of unnecessary biopsies.<sup>14</sup> High-risk patients in the case of melanoma include those patients with a personal history of melanoma, family history, suspicious skin lesions (e.g., atypical nevi), and other risk factors (e.g., age  $\geq$  50 years, prior history of cancer). For patients with suspected SCC or BCC, a goal of management is to reduce potentially disfiguring biopsies.

The assessment of suspicious skin lesions typically begins with a physical examination and visual inspection of the skin with the naked eye. Full body and digital photography, which augments visual inspection, are used across different practice settings and specialty groups. In addition, many dermatologists use dermoscopy (also known as dermatoscopy, epiluminescence microscopy, or surface microscopy) to better examine the lesion. The dermoscope is a

magnifying lens equipped with a polarized or nonpolarized light source (to deflect surface reflection) that is held near the suspicious lesion. Other diagnostic techniques include confocal microscopy, which produces images of skin lesions at various depths and is primarily used in research centers. Some of these devices have been approved or cleared by the FDA; others are in general use (e.g., photography). In addition, a number of imaging modalities are emerging to help improve the diagnostic accuracy of visual inspection of pigmented skin lesions. These include epidermal genetic tape stripping, ‘scent’/‘odor’ ultraviolet photography, fluorescence, ultrasound, laser Doppler, bio-electrical impedance, polarized light photography, 3-D histograms of color mapping, multispectral imaging and fully automated computer-based analysis, and thermography.<sup>15</sup> To evaluate these newer techniques, several comparators have been used. In addition to the direct comparison with the “gold standard,” the biopsy, several studies have highlight comparisons between the newer devices and the clinical exam, as well as head-to-head comparisons between these devices.

## **Statement of Work/Objectives**

The objectives of this technical brief are to provide a description of the state of the science of noninvasive imaging modalities in diagnosing cancerous tumors of the skin, proffer an analytic framework for assessing the applications of the devices, provide a summary of ongoing research, and to delineate future research needs.

Three principal forms of skin cancer will be considered: basal cell carcinoma (BCC) and squamous cell carcinoma (SCC), the more prevalent forms of skin cancer, and melanoma, among the most virulent. While the focus of this brief will be on modalities currently in general or limited clinical use and/or FDA approved or cleared, we also will consider investigational technologies based on available data and input from our key informants particularly the potential importance of these technologies and where they might fit into the care process.

For the purpose of the present discussion, we considered these modalities according to the degree of resolution of the skin lesions, ranging from clinical inspection (quaternary and tertiary) to delineation of cellular and subcellular structures (secondary and primary), adapted from Marghoob 2003.<sup>16</sup> We also examine whether there are indications of differing effectiveness among techniques for the early detection of skin cancers among Whites, Blacks, and Hispanics, and whether that should be a focus of future comparative effectiveness research. Whenever possible, we stratify the findings by whether or not the patients had a previous history of skin cancer and whether or not patients have a history of other malignancies. The rationale for this is the growing recognition of skin cancer as a leading form of second malignancy.<sup>1,11</sup> We also sought to assess the clinical application of these modalities and their diffusion across specialty/subspecialty groups.

## Guiding Questions

Our analysis of the current literature was based on the following guiding questions. These guiding questions are partly derived from the hierarchical model of technology assessment first proposed by Thornbury and Fryback in 1992.<sup>17</sup> According to this hierarchical model, there are six sequential levels to be considered in the evaluation of a technology assessment. They are: (1) technical efficacy, (2) diagnostic accuracy efficacy, (3) diagnostic thinking efficacy, (4) therapeutic efficacy, (5) patient outcome efficacy, and (6) societal efficacy. Each level is built upon the previous level. The guiding questions posed to the different technologies will be addressed to the extent that they have satisfied the sequential levels (e.g., some of the modalities have not progressed beyond the first level of technical efficacy stage and therefore it makes little sense to assess the second level questions like diagnostic accuracy).

**Guiding Question 1. What are the different noninvasive techniques/modalities that have been proposed to be used for the early detection of skin cancer?**

- i. What are the postulated advantages and disadvantages of these noninvasive diagnostic techniques compared with biopsy, among individuals who should be considered for these technologies?
- ii. What are the potential safety issues and harms associated with the use of noninvasive diagnostic techniques for the evaluation of suspicious skin lesions?
- iii. What is the current FDA clearance status of these modalities?
- iv. What kinds of training and certifications are needed to use these techniques/modalities?
- v. What are some of the newer techniques/modalities in development?

**Guiding Question 2. What is the current clinical context in which these new noninvasive modalities are used—who uses them, in what setting, for which cancers, with which patients?**

- i. Are there reasons to consider that some techniques may be more or less effective for the early detection of skin cancers in those patients who had a previous history of skin cancer, previous history of any cancer, or no history of cancer?
- ii. Are there reasons to consider that some techniques may be more or less effective for the early detection of skin cancers among Whites, Blacks, and Hispanics?

**Guiding Question 3. What published and unpublished studies have reported on the use and safety of these noninvasive modalities? Provide a synthesis of the following information:**

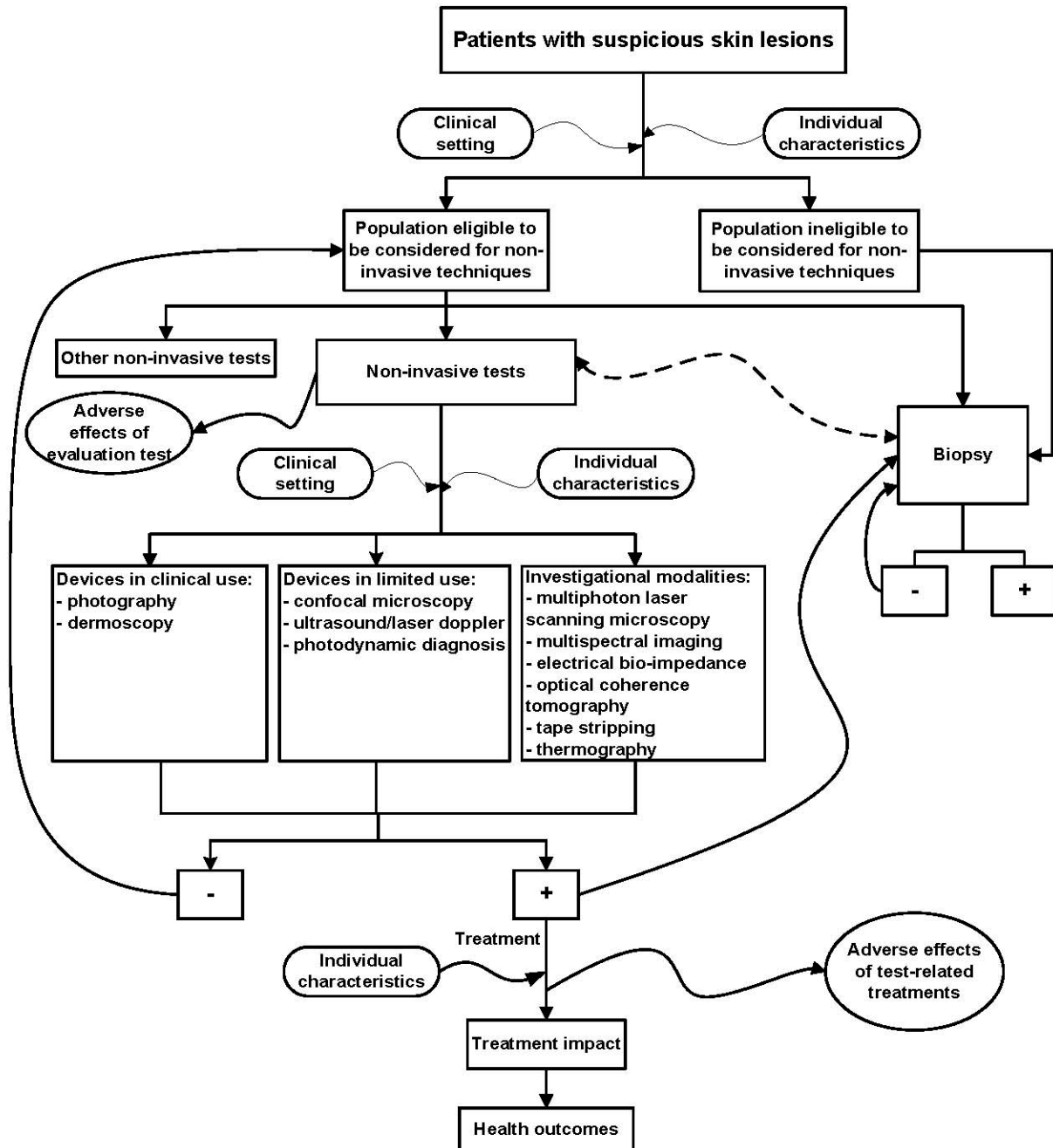
- i. Indication/patient inclusion criteria
- ii. Study design and size
- iii. Role of the test in patient management
- iv. Outcomes assessed
- v. Adverse events, harms, and safety issues reported
- vi. Comparators used (applicable only to comparative studies)
- vii. Length of follow-up (applicable only to longitudinal studies)

Guiding Question 4. What is the projected diffusion of these different techniques/modalities in the near future? What are potential areas for future research that are most meaningful given the current state of the evidence and the projected diffusion of these techniques/modalities?

## **Analytic Framework**

The analytic framework addresses the evaluation of patients with suspicious skin lesions, who, based on their own characteristics (such as prior history or other risk factors) or the setting in which they seek care (primary, specialty, or subspecialty care), may be considered as candidates for assessment with noninvasive techniques. Eligible patients would be considered for one or more of the noninvasive techniques prior to or in lieu of biopsy. The specific device(s) selected could be those in general clinical use (i.e., photography and dermoscopy), limited clinical use or investigational, based on availability and suitability of the device to address the clinical problem. The framework is designed to include a feedback loop that leads to biopsy if either the evaluation were positive or referred back for further followup. The importance of clinical setting (availability of the device and suitable levels of training/competency) and the patient's individual characteristics are considered at multiple junctures within the framework. Solid wiggly lines generally indicate associations/relationships that are present, but not direct or not of our interest. They can be impact of effect modifiers, or adverse effects of interventions. The dotted wiggly line between the noninvasive test box and the biopsy box indicates that we were comparing between the two tests.

Figure 1. Analytic framework



# Methods

## Systematic Searches of the Published Literature

We conducted an electronic literature search in MEDLINE<sup>®</sup> for articles published between 1990 and March 2011. Our search strategy utilized both National Library of Medicine Medical Subject Headings (MeSH<sup>®</sup>) and search terms. The identification of search terms for noninvasive modalities was guided by information from the earlier Topic Refinement phase of this project. To develop search terms for skin cancer, we used a previously published skin cancer systematic review as a reference.<sup>18</sup> Search terms for noninvasive modalities were crossed with search terms for skin cancer. We restricted our search to literature published within the last 20 years because all noninvasive modalities of interest are fairly new. We also restricted our search to English-language human subject studies. Because the specific focus of the search was not screening and detection for specific types of skin cancer, (e.g., melanoma or nonmelanoma), we did not seek to identify or formally evaluate existing guidelines. Selected examples from the National Guideline Clearinghouse ([www.guideline.gov](http://www.guideline.gov)) are included for background information only. The details of our search strategies are listed in Appendix A. In particular, we noted that while ‘dermoscopy’ has been used in MEDLINE<sup>®</sup> since 2005 as an inclusive term for dermatoscopy, epiluminescence microscopy, or surface microscopy, studies prior to 2005 needed to be identified by the alternative terminologies. The first 200 abstracts were screened jointly by all project investigators to ensure that screening criteria were well understood and applied uniformly. Thereafter, investigators screened non-overlapping sets of the remaining citations. In general, abstracts served as the primary source of information, which were supplemented by full-text review of systematic reviews (n=5) and all randomized controlled trials (RCTs) (n=11). We did not do a pre-MEDLINE<sup>®</sup> search.

Because our report primarily focused on the use of noninvasive modalities for the early diagnosis of skin cancer, we excluded studies of metastases detection, therapeutic interventions, or modalities used exclusively for pre-surgical planning. Specifically, we did not consider <sup>18</sup>F-FDG positron emission tomography (PET), computed tomography (CT), single photon emission computed tomography (SPECT), and lymphoscintigraphy in this technology brief because these techniques are not generally used in initial screening of suspicious skin lesions or establishing the diagnosis of skin cancer, but rather, in delineating loco-regional or distance spread of disease. In addition, given our focus on the evaluation of primary cutaneous lesions, we also excluded evaluation of subungual, ocular, and visceral sites of disease. Appendix B, Table 1 summarizes our inclusion and exclusion criteria.

## Searches of the Grey Literature

We performed an Internet search for key words to identify more recent noninvasive techniques/modalities not in current widespread use, such as fluorescence, high-resolution ultrasound, laser Doppler, bio-electrical impedance, polarized light photography, 3-D histograms of color mapping, and thermography. For these searches, unless otherwise advised, we used the Google search engine, and, for each search string entered, we perused the first 10 pages to identify relevant links.

In addition to our Internet search, we reviewed major vendors or manufacturers’ Web sites for information pertaining to the different noninvasive modalities. To identify major vendors or

manufacturers and to obtain FDA clearance status of relevant devices (see Appendix C, Table C1), we searched the FDA Center for Devices and Radiological Health (CDRH) database. We compiled a list of noninvasive devices using information from published reviews as well as information gleaned from our Technical Experts. For potential harms with the relevant devices, we queried the FDA Manufacturer and User Facility Device Experience (MAUDE) database for any reported harms with the use of the relevant devices.

Also, we searched the ClinicalTrials.gov registry for any ongoing or completed relevant trials involving the various noninvasive modalities of interest. We used both device categories and name of device (such as MoleMax and Vivascope<sup>®</sup>) and device category when searching the registry (see Appendix C, Table C2).

## **Interviews With Key Informants**

A representative panel of Key Informants was identified through the earlier Topic Refinement phase of this project. These individuals included medical experts/practitioners in dermatology, oncology, and family medicine, a patient with skin cancer and a representative of patient advocacy group, as well as scientists and representatives of professional societies.

Technical experts within the Key Informant group were individually interviewed by phone or email for their responses to Guiding Questions 1, 2, and 4. Interview questions were tailored to the unique perspective and expertise of each Technical Expert. The final structure of the brief in reference to classification of technologies by degree of clinical use was also reviewed. All external participants completed disclosure of interest forms and any conflicts were considered and balanced.

## **Data Collection**

Data from abstracts of qualified studies were extracted into an Excel spreadsheet. We extracted information on items of interest (population, intervention, comparator, outcome [PICO]), using customized forms, including information specific to the particular noninvasive modality. We also extracted data on the citation (first author name, journal, and year of publication), condition being evaluated, study size and setting, particular noninvasive modality, and details relevant to the technical specification of the particular noninvasive modality. We categorized, wherever possible, qualified studies into the two major categories: reviews, which included systematic review, general or narrative review, and technical report; or primary studies, which included RCTs, comparative cohort, non-comparative cohort or case series, diagnostic tests, or single case reports. Studies that did not fit into one of these two groups were considered “other.” An abstract was classified as a systematic review if it described the study as a meta-analysis, pooled analysis, or systematic review. An abstract was also classified as a systematic review if it reported that there were inclusion or exclusion criteria in selecting the studies. We documented the outcomes as test accuracy (e.g., sensitivity, specificity, false positive rate, false negative rate), clinical outcomes (e.g., survival), characterization of the skin lesion (e.g., lesion size, lesion color), and other. The “other” category pertained to intermediate outcomes (e.g., number of lesion) or process outcomes (e.g., patient satisfaction, healthcare utilization), training for optimizing the use of device, or description of use.

## **Data Organization and Presentation**

To address the guiding questions, we combined our systematic review of abstracts of current published literature with key informant interviews and a perusal of grey literature. Devices were classified as those in general clinical use, limited clinical use, or investigational use, based on all available information; the results are organized to reflect this. For devices in general or limited clinical use, we have presented information based on available literature on: description of technique; theoretical advantages and disadvantages; variations of technique; clinical context of use, FDA status, as well as ethical, privacy, equity, and cost considerations when this information is available. For investigational devices, given the scarcity of published literature, we have provided a summary paragraph, including a description of the device and its potential future applications. For each diagnostic modality, technical descriptions were synthesized using information extracted from the most recent and most comprehensive narrative review(s) available.



## Findings

The MEDLINE® database search for primary studies yielded 10,743 citations published between 1990 and 2011 (Figure 2). Including suggestions from experts, abstract screening processes identified a total of 629 abstracts meeting inclusion criteria. Among all included abstracts, 231 were reviews, 348 were primary studies, and 48 were categorized as other publication type (such as guidelines and commentaries). Of the 231 reviews, 5 were systematic reviews (< 1 percent of all abstracts), 118 were narrative reviews (21 percent), and 108 were technical reports (18 percent). Among the 350 abstracts of primary studies, there were 11 abstracts representing 10 distinct RCTs (3 percent), 77 diagnostic tests (22 percent), 64 comparative cohort studies (18 percent), 143 noncomparative cohort studies (41 percent), and 55 case reports (16 percent). The screening results are displayed in Figure 2. Whether or not data were available in the literature to address the guiding questions is tabulated in Table 1. The details of the evidence map by device are presented in Appendix D, Tables D1 and D2. Of note, as seen in Figure 3, while the majority of abstracts reported on primary studies (56 percent), only 3 percent of the primary studies were RCTs. The details of these trials (e.g., objective, setting, populations) are presented in Appendix D, Table D3.

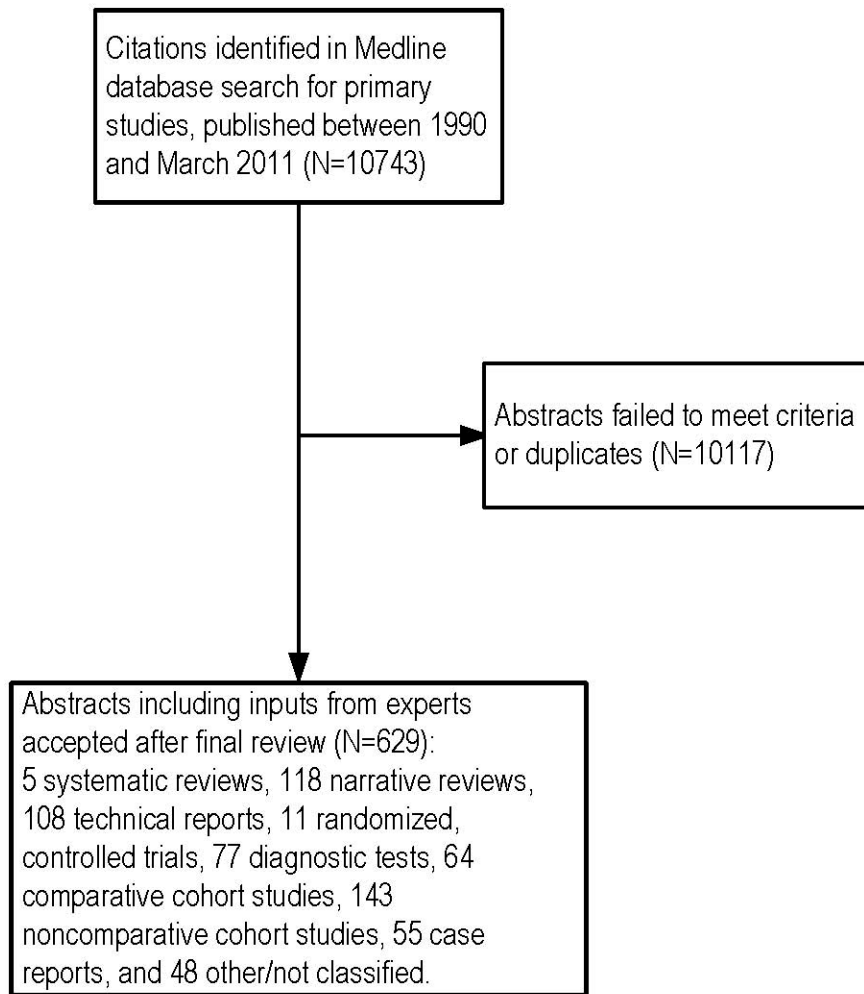
**Table 1. Data availability to address the elements of the guiding questions for the different diagnostic technologies**

	Modalities in general clinical use		Modalities in limited clinical use			Investigational					
	Photography	Dermoscopy	Confocal Microscopy	Ultrasound/ Laser Doppler	PDD	Multiphoton Laser Scanning Microscopy	Electrical Bio-Impedance	OCT	Tape Stripping	Multispectral imaging	Thermography
<b>GQ1: What are the techniques?</b>											
a. Type of techniques/modalities	✓	✓	✓	✓	✓	✓	✓	✓	✓	✓	✓
b. Postulated advantages and disadvantages?	✓	✓	✓	✓	✓	✓	✓	✓	✓	✓	✓
c. Potential safety issues and harms?	nd	✓	nd	✓	✓	nd	nd	nd	nd	nd	nd
d. FDA status <sup>1</sup> ?	✓	✓	✓	✓	✓	✓	✓	✓	✓	✓	✓
e. Training and certifications?	✓	✓	nd	nd	nd	nd	nd	nd	nd	nd	nd
f. Newer techniques in development?	✓	✓	nd	✓	✓	nd	nd	✓	nd	nd	✓
<b>GQ2: Clinical context: setting, which cancers, which patients?</b>											
a. Setting where the technique/modality was used	✓	✓	✓	✓	nd	nd	nd	✓	nd	✓	nd
b. Suspect different effectiveness for different cancer types?	✓	✓	✓	✓	✓	✓	✓	✓	✓	NA	✓
c. Suspect different effectiveness for patients with different histories?	✓	✓	nd	nd	✓	nd	nd	✓	nd	nd	nd
d. Suspect different effectiveness for different race/ethnicity?	nd	✓	nd	nd	✓	nd	nd	nd	nd	nd	nd
<b>GQ3: What published and unpublished studies? Synthesis of:</b>											
a. Indication/patient inclusion criteria	✓	✓	✓	✓	✓	✓	✓	✓	✓	✓	✓
b. Study design and size	✓	✓	✓	✓	✓	✓	✓	✓	✓	✓	nd <sup>2</sup>
c. Role of the test in patient management	✓	✓	✓	✓	✓	✓	✓	✓	✓	✓	✓
d. Outcomes assessed	✓	✓	✓	✓	✓	✓	✓	✓	✓	✓	✓
e. Comparators used	✓	✓	✓	✓	✓	nd	nd	✓	nd	✓	nd
f. Length of follow-up	nd	✓	nd	✓	nd	nd	✓	nd	nd	nd	nd

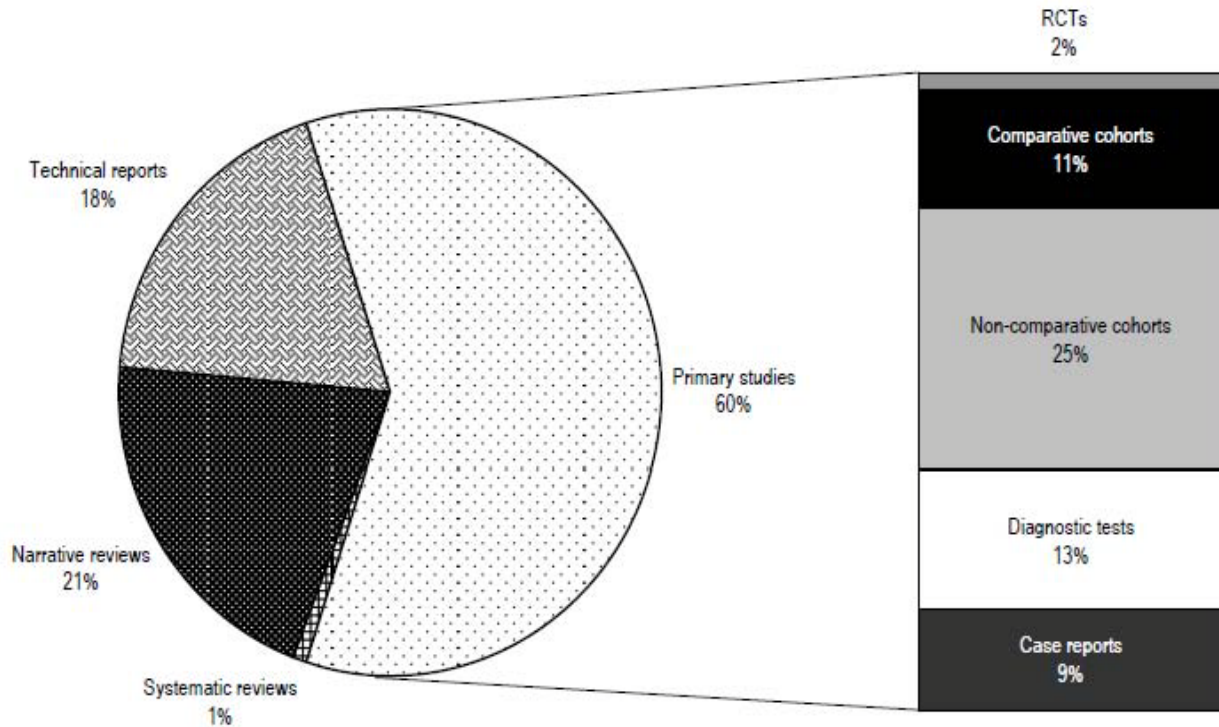
<sup>1</sup> FDA status is addressed for each diagnostic modality regardless of the presence of clearance status information on the FDA CDRH database.

<sup>2</sup> No primary studies on Thermography were identified.

**Figure 2. Literature flow diagram**



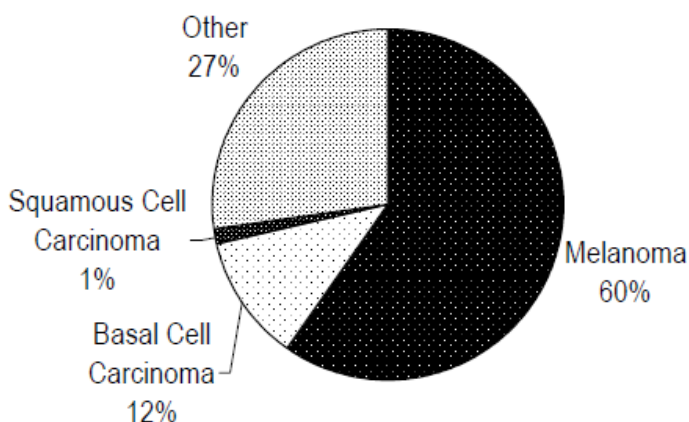
**Figure 3. Distribution of all abstracts by study type**



RCT = randomized, controlled trial

Over half of the abstracts addressed melanoma detection and diagnosis (60 percent) and 13 percent addressed BCC or SCC (see Figure 4). The remainder covered skin cancer combinations or did not specify the type of skin cancer lesion (see Appendix D, Table D2). In considering devices in current use, we reviewed the classification system presented by Marghoob 2003<sup>16</sup> in which the devices are compared by skin imaging depth. This classification system helped to clarify the type of information gleaned from the imaging device as well as alternative devices designed to capture similar information. For example, photography is considered a quaternary device, providing information at the superficial level, while dermoscopy helps to characterize lesions at the tertiary level (e.g., cellular aggregates or blood vessels). Neither of these devices is designed to delineate specific cellular and subcellular structures. Investigational devices, such as confocal microscopy may provide that level of resolution. In general, issues of access, availability, and degree of required training, increase with tissue depth. Outcome measures reported in the published primary studies are presented in Appendix D, Table D4.

**Figure 4. Distribution of all abstracts by skin cancer type**



## **Devices in General Clinical Use**

### **Photography**

This technique involves using photographic devices to capture surface images of the skin in order to primarily identify suspicious and pigmented lesions in high-risk patients.

### **Available Literature**

Our search revealed 51 abstracts on photography, representing 8.5 percent of the total number of abstracts reviewed (see Appendix D, Table D1). With respect to the types of skin cancer, 55 percent (28/51) pertained to melanoma diagnosis and 2 percent (1/51) to basal cell carcinoma. The other abstracts were on a combination of skin cancers, or skin cancer type was not specified (see Appendix D, Table D2). Of the 30 abstracts of primary studies, the most commonly reported outcomes were test accuracy (n=7), and lesion characterization (n=5). No current trials on photography were found in ClinicalTrials.gov.

A majority of the abstracts (60 percent) addressed information on photography features, device variations, algorithms/image classifications/checklists, privacy issues, diagnostic accuracy and training. Twenty-six percent of the abstracts included data assessing at-risk populations and treatment settings. The remaining abstracts addressed information on longitudinal followup and diffusion, as well as general introduction and view/opinion articles. Abstracts for photography lacked data assessing effectiveness for different racial/ethnic groups or information on safety/adverse events.

### **Description of Technique**

The use of photography to capture specific suspicious skin lesions or the entire body skin surface for monitoring purposes is commonly used in dermatology practices, but not typically in a primary care setting. Three studies identified by our search assessed the utilization of photography in U.S. dermatology settings.<sup>19-21</sup> Technical advances in and the affordability and adaptability of digital cameras have rendered the use of film-based devices obsolete; a myriad of

digital cameras and models are commercially available. In this review, photography refers only to those images that were captured or stored using digital technologies.

Total body photography (TBP), also known as whole body photography, surveillance photography, or total body mapping, involves the acquisition of clinical head-to-toe images of the entire skin surface. In TBP, a series of 25 to 40 segmental baseline images are captured.<sup>22</sup> Images may be stored electronically and used for side-by-side comparisons at future visits, or may be analyzed by algorithms to make computer-assisted diagnoses of skin cancer. Copies of pictures may be handed to patients for assistance during skin self examination. The success of this technique depends on ease and standardization of image acquisition, quality of photographs, and the availability of photographs for clinical use.<sup>23-25</sup> Standardized poses and accessories like pose frames aid in minimizing non-lesional differences during follow up examinations.<sup>24</sup>

### **Theoretical Advantages**

TBP is useful in detecting new lesions since the entire skin surface is captured. Entire regions of nevus and nevus-free zones are captured as opposed to lesion-specific images as captured by other noninvasive techniques. It is also useful in generating a baseline pictorial record of skin surfaces for comparison with subsequent changes. This aids in physicians' ability to detect morphological changes of individual lesions over time and appreciate subtle changes in them, and in patients' ability to objectively assess changes in their own lesions—especially on hard-to-reach skin surfaces.

Digital photography for specific areas aids in the monitoring of size, shape, or color of lesions to detect subtle changes that may be missed by the naked eyes. Photography can focus on specific areas that generated concerns from patients or healthcare providers. For instance, photographs were taken of 109 skin lesions at an outpatient clinic, and subsequently evaluated by a group of dermatologists.<sup>26</sup> In another study of 421 school-aged children, photographs of children's back were taken.<sup>27</sup> Agreement among counts of melanocytic nevi made by parents, dermatologist, and assessment of photographs were assessed.<sup>27</sup> Three studies, including 1 RCT, assessed the use of photography in conjunction with mole mapping techniques.<sup>28-30</sup>

Studies have shown that baseline photography improves the sensitivity of malignant melanoma diagnosis by facilitating early detection of new and subtly changed malignant moles, even before the development of classical clinical ABCD (Asymmetry, Border, Color, and Differential structure) features in high-risk patients.<sup>23,31-34</sup> However, one study did not find that having total digital body photographs affected the biopsy rates of suspicious skin lesions during the first year of followup of patients at high risk for melanoma.<sup>35</sup> A 2007 narrative review by Halpern<sup>36</sup> reported that for early diagnosis of melanoma “general consensus supports opportunistic screening and identification of high-risk individuals who may benefit from specialized surveillance with dermoscopy and whole-body photography”.

In addition, given the scarcity of specialized dermatologists in rural areas, the use of digital photography may aid tele-dermatology in improving healthcare access and delivery. With digital photography, long-distance consultation is made possible, reducing time to specialty evaluation and/or unnecessary clinic visits.

### **Theoretical Disadvantages**

A commonly cited disadvantage of TBP is the poor resolution of images, which could limit its ability to detect subtle changes over time. The use of more recent technologies including high resolution digital cameras and polarized filters may have resolved this issue. Loss to followup in

noncompliant patients is another issue since TBP requires regular followup sessions.<sup>37</sup> Privacy issues, such as imaging of the perineum, gender preference of photographers, and data storage, have also been raised.<sup>38</sup>

## Variations of Technique

- Total body imaging systems. These generally consist of a digital camera for image acquisition and a computer storage and retrieval system. They include the MIRROR™ DermaGraphix, FotoFinder BodyStudio LITE, and MoleMap surveillance program.
- Photography with automated image analysis. Several devices like MoleMax 1 Plus, DermAssist™, Molemax 3 and Melanoscan® have built-in software that allow real-time comparisons of total body baseline and followup pictures, automatic mole counting to detect new lesions, and diagnostic algorithms.<sup>32,39,40</sup> Other techniques utilize 3D differential forms of skin surfaces to “realize automatic recognition of melanoma”<sup>41</sup> or computer-based algorithms to evaluate pigmented skin lesions.<sup>42</sup>
- Total body photography combined with devices for lesion evaluation.<sup>16,34,43-45</sup> An example of such a device is a dermoscope/camera combination (see Dermoscopy section for further details).
- Teledermatology. In this technique, acquired digital images are transmitted virtually through the Internet via mobile devices, such as 3G phones and personal digital assistants, and e-mail or specific Web applications.<sup>46</sup> The images are transferred either from other practitioners (teleconsulting) or directly from the patient to the clinician (telediagnosis).<sup>46</sup> Description of the use of digital photo images in developing dermatological diagnosis and medical management is available.<sup>47</sup> This technique confers the advantages to both physicians and patients by eliminating the need for clinic appointments or reducing long waiting lists for the receipt of results while maintaining expert management, although data privacy and physician training issues have been raised.
- The use of ultraviolet light photography, (e.g., Canfield Visia System), is discussed under Photodynamic Diagnosis, as it relies on the photodynamic properties of melanin in the skin.

## Clinical Context of Use

TBP is recommended for screening patients at high risk of skin cancer (specifically melanoma).<sup>48,49</sup> High-risk patients are defined as those with more than 10 dysplastic nevi, a previous history of melanoma, a family history of melanoma in a first degree relative (parent, sibling, or child). However, the age of onset and frequency at which photographic surveillance should be performed is unclear.

In terms of setting, our technical experts also suggested that these techniques may be useful in the primary care setting and in rural areas with no access to specialists. Although TBP is widely used by dermatologists and oncologists in the U.S., it is not routinely used by primary care practitioners. The literature describes a wide range of practices of TBP. While some clinical practices have dedicated professional medical photographers, others depend on existing dermatologists, oncologists, or general practice physicians to use these devices. Various training modules on the use of specific devices are available on the manufacturers’ Web sites.

## **FDA Status**

The cameras used during total body photography are not considered medical devices. They are therefore not regulated by the FDA. Similarly, the imaging systems used to store, analyze, and transmit images are not under the FDA purview.

## **Summary**

Overall, photography included 7 abstracts from 6 unique RCTs—accounting for 64 percent of all RCTs included in this technical brief (Appendix D, Table D1). The RCTs evaluated outcomes including diagnostic accuracy, excision rates, patient satisfaction, cost savings and treatment adherence and followup (Appendix D, Table D1). Outcomes were measured at both the patient level (5 trials) and provider level (2 trials), with study participant numbers ranging from 88 to 5784. Almost all of the trials were conducted in a primary care setting (2 in the United States); only one was set in dermatology. Four of the RCTs were conducted outside of the U.S.: 3 in Australia, 1 in the United Kingdom. Abstracts from non-randomized studies consisted of mostly comparative and non-comparative cohorts (47 percent)—the remaining abstracts included review articles and data from diagnostic test studies. We found that the use of photography to capture suspicious skin lesions of the entire body for monitoring purposes is commonly used in dermatology practices, but not typically in a primary care setting. Photographic surveillance is recommended for patients at high risk of skin cancer, based on family history, history of dysplastic nevi, or history of prior malignant lesions.<sup>48,49</sup> However, the age of onset and frequency at which it should be performed is unclear. The affordability and adaptability of digital imaging permit the increased ease of electronic image storage and allow for side-by-side comparisons at future visits. The evolution of computerized imaging systems has also enhanced the ability to convey these lesions from patients to providers and across provider types. The available data are limited on the role of photography in changing clinical outcomes, including confirmation that baseline photographs in specialty clinics improve the detection of melanoma, resulting in detection of earlier stage lesions or recurrent lesions. While there are some studies, principally from Australia, addressing the impact of photography in primary care settings, no similar studies have been conducted in the U.S. Furthermore, data are limited on the role of photography for specific racial/ethnic groups. No current trials on photography were found in ClinicalTrials.gov.

## **Dermoscopy**

Dermoscopy shows subsurface structures of the skin with the use of handheld devices that extend optical light ray penetration beyond the skin surface and minimize surface reflection. In contrast, naked eye examination limits visualization of certain skin structures because the stratum corneum has reflective properties.

## **Available Literature**

The majority of the included abstracts addressed dermoscopy (69 percent) (see Appendix D, Table D1). Our search identified 433 abstracts on dermoscopy from the following types of studies: 3 trials, 39 comparative cohort studies; 96 noncomparative cohort studies/case series; 52 diagnostic test reviews/studies; 49 case reports; 78 narrative reviews; 5 systematic reviews; 74 technical reports; 37 guidelines, opinion pieces, or commentaries, and others. Of these, 324 abstracts provided information on the type of malignancy studied; 238 on melanoma, 22 on



BCC, 5 on SCC, and 59 were combinations. Three non-randomized studies were identified in the ClinicalTrials.gov registry (see Appendix C, Table C2).

The main topics covered in these abstracts were: (1) dermoscopic features including lesion characterizations and histopathological correlations (94 abstracts); (2) general introduction and how-to articles (71 abstracts); (3) digital dermoscopy including automation and computer analysis (42 abstracts); (4) dermoscopy algorithms/image classification/checklist (39 abstracts); (5) other aspects of digital dermoscopy including teletransmission of digital images (23 abstracts); (6) general diagnostic accuracy (24 abstracts); and (7) follow up studies to monitor the change in pigmented lesions (15 abstracts); and (8) training (19 abstracts). No more than 6 percent of the total abstracts reported on the following: (1) other technical aspects of dermoscopy; (2) guidelines or proposals; (3) dermoscopy in nonwhites; (4) pregnancy; (5) and other miscellaneous variables. For the 15 abstracts that reported on longitudinal follow up (ranged from 3 months to 4 years) using dermoscopy, the outcome of interest was mainly the change in the number and the characteristics of pigmented lesions. No change in survival outcome was reported.

## **Description of Technique**

Dermoscopy (also known as surface microscopy or epiluminescent microscopy or dermatoscopy) provides at least a 10-fold magnification of skin lesions by using either nonpolarized or polarized light.<sup>50</sup> There is generally good agreement for overall dermoscopic patterns between polarized and nonpolarized dermoscopy (kappa 0.88 to 1.00).<sup>51</sup> Differences between the two are detailed below. Dermoscopy is used to differentiate between benign and malignant pigmented skin lesions, and aids in the overall assessment of pigmented lesion morphology. Types of dermoscopy devices are as follows:

- Nonpolarized light contact dermoscopy.<sup>14,16,52-54</sup> This device uses a nonpolarized light source (a halogen light source at a 45° angle), and requires the use of an oil or gel interface on the lesion to prevent surface reflection. It provides better illumination and resolution than polarized dermoscopy. The colors of lesions appear sharper in nonpolarized dermoscopy compared with polarized dermoscopy; the former is therefore useful in visualizing milia-like cysts and comedo-like openings, peppering, lighter colors, and blue-light areas. Its cost is approximately \$150.00.
- Polarized contact/noncontact dermoscopy.<sup>14,16,52-54</sup> Polarized dermoscopy devices do not need a liquid interface and are equipped with a cross-polarized lens that absorbs scattered light waves. Polarized contact dermoscopy can attain the images of vascular and other deeper structures, and is a useful tool in visualizing melanin, blue nevi, and shiny white streaks. Polarized noncontact dermoscopy is better used for imaging mucous membranes. Since direct skin contact is not required for visualization, the use of noncontact dermoscopy minimizes the risk of nosocomial infection. These devices (contact or noncontact) cost approximately \$300.00 or more.
- Combined polarized and nonpolarized dermoscopy.<sup>53</sup> These devices incorporate the desirable characteristics of both types of dermoscopy. Clinicians can choose to use either polarized or nonpolarized lights. Its cost is approximately \$1200.00.

## **Theoretical Advantages**

Because of its ability to magnify lesions and reveal subsurface structures, dermoscopy is expected to have higher sensitivity and specificity than the naked eye in detecting malignancies,

thus increasing the number of melanomas that are identified and sent for biopsy, while reducing the number of unnecessary biopsies. It may even allow melanomas to be identified at earlier stages which could lead to better outcomes.

Only one RCT examined this posited advantage of increased diagnostic accuracy of dermoscopy compared with naked eye examination. This RCT compared dermoscopic evaluation and naked-eye examination in 73 primary care physicians in Italy and Spain and inferred the effect of the addition of dermoscopy on the likelihood that a primary care physician would fail to refer a patient with suspicious skin lesions for a second expert opinion.<sup>55</sup>

One RCT of 913 patients in Italy examined the downstream effect on the number of skin lesion excised for diagnostic verification with the addition of dermoscopy in a pigmented lesion clinic.<sup>56</sup>

The use of dermoscopy may help to allay patient anxiety as one survey reported that more than half of the dermatologists queried responded that dermoscopy was effective in reducing patients' anxiety.<sup>57</sup>

One author suggested that followup examination using digital dermoscopy would allow for the detection of early stage melanoma.<sup>58</sup> We did not identify any controlled studies examining the use of dermoscopy to increase the detection rate of early stage melanoma. The studies on early melanoma identified by this brief were largely confined to the use of algorithms or classifiers of dermoscopic images to differentiate early melanoma from other stages of melanoma.

## **Theoretical Disadvantages**

The use of dermoscopy requires training and this may be considered a theoretical disadvantage for those who are not willing to invest in the time and effort to learn and master this technique. Based on our key informant interviews, we were informed that one of the main challenges to the use of dermoscopy lies in the training of nonexperts in its technique. The level of training and experience of the user may well determine the effectiveness of dermoscopy. A review paper recommended that dermoscopy should be used by experts to increase test accuracy.<sup>58</sup>

The time necessary to complete an examination using the technique may be considered a negative factor in its use. In one study, almost one-third of dermatologists thought that the use of dermoscopy was too time consuming.<sup>57</sup> An RCT found that performing a complete skin examination with dermoscopy took significantly longer compared with a complete skin examination without dermoscopy (median time was 142 vs. 72 seconds, respectively;  $P < 0.001$ ).<sup>59</sup> Although one key informant suggested that since the total time required for a thorough complete skin examination (with or without dermoscopy) was generally less than 3 minutes, it is not an reasonable amount of time considering that it could potentially prevent the morbidity and mortality associated with skin cancer. Another comparative study found that the use of dermoscopy is more time consuming compared with total body photography. The time spent at initial visit was 30 to 50 minutes for dermoscopic photographs and 20 to 30 minutes for TBP. Follow-up visit time was also longer with dermoscopic photographs lasting 30 to 50 minutes compared with 10 to 20 minutes for TBP.<sup>14</sup>

No study systematically assessed harms to either the patients or the operators from the use of dermoscope. Unintended effects from the use of dermoscope were described in two case reports. One case report described a patient who developed allergic contact dermatitis after exposure to dermoscopy immersion oil contaminated with cedarwood oil.<sup>60</sup> The other described a

dermatologist who developed tonic pupil (Adie's pupil) after intensive use of a dermoscope.<sup>61</sup> There has been some concerns that dermoscope could serve as a potential source of nosocomial infection because *Staphylococcus aureus* had been isolated from dermoscopes that used mineral oil as immersion fluid;<sup>62</sup> although another group of investigators felt that the potential risk of nosocomial infection related to the routine use of dermoscopes in an outpatient setting was small.<sup>63</sup> Disinfecting dermoscopes with 70-percent isopropyl alcohol<sup>62</sup> or using alcohol-based antibacterial gel as immersion fluid were reportedly effective in reducing or eradicating potential pathogens.<sup>63,64</sup> One key informant informed us that most dermatologists today who practice dermoscopy use alcohol as an immersion fluid.

Binder and colleagues, in a 1999 letter, cautioned the use of standard immersion oil for use in contact dermoscopy because it may contain chlorinated paraffin and dibutyl phthalate, both of which could be teratogenic and carcinogenic.<sup>65</sup> The authors suggested the use of olive oil, glycerin, or ultrasonic conduction gel instead.

## Variations of Technique

- Dermoscopy without image capture features.<sup>14,66</sup> The DermLite<sup>®</sup> handheld dermoscopic device is comparatively inexpensive (\$300-\$1000). Test accuracy varies depending on a user's experience. This device does not identify "featureless" or very early melanomas.
- Dermoscopy with image capture features.<sup>14,66</sup> These devices are equipped with a digital camera that captures dermoscopic images, and can store the digital images of pigmented lesions and identify changes over time.
- Dermoscopy with image capture features and analytical capability.<sup>14,66,67</sup> These devices are equipped with both a digital camera and computer software. They can extract and save clinical and dermoscopic information. Purported advantages are that these devices can be used by nonexperts, and they provide objective and reproducible results. Some of the systems provide computerized diagnostic results.

## Clinical Context of Use

Dermoscopy may have different intended purposes depending on the clinical setting. In a primary care setting, dermoscopy could be used primarily to help a clinician decide whether to refer a patient's suspicious skin lesion(s) for dermatology consultation. In a dermatology setting, dermoscopy could be primarily used to help improve the diagnosis of melanocytic and non-melanocytic nevi and help monitor patients with multiple nevi.

Clinical settings in the abstracts reviewed were almost all based in dermatology offices or pigmented lesion clinics. Of the 400 plus abstracts, only seven were based in primary care settings.

A 2009 survey reported that 48 percent of U.S. dermatologists (1555/3209) are dermoscopy users (n=1555), while 52 percent are nonusers (n=1654).<sup>68</sup> Among 1555 dermoscopy users, the types of dermoscopy used are: polarized light noncontact dermatoscope (54.7 percent), nonpolarized light immersion dermatoscopes (30.0 percent), and polarized light contact dermatoscopes (21.8 percent).<sup>68</sup> Dermoscopy was principally used in the assessment of patients with pigmented lesions (70.7 percent of patients); the remainder of patients had nonpigmented lesions (28.6 percent) or papulosquamous conditions (8.8 percent).<sup>68</sup> Another 2009 survey reported that 88 percent (81/92) of dermatology residents were using dermoscopy and the authors concluded that the use of dermoscopy has increased significantly during the last decade.<sup>21</sup> One cohort study suggests that a dermoscopic followup program, tailored to the

individual risk profile of a patient (e.g., familial atypical mole and multiple melanoma (FAMMM) syndrome, atypical mole syndrome (AMS), previous melanoma), would be effective in detecting melanoma.<sup>69</sup>

One study evaluated the following factors associated with the use of dermoscopy: sex and age of dermatologists, teaching setting, years graduated from residency, and patients' geographic residence.<sup>68</sup> Reimbursement issues may limit its widespread use. Marchionda 2010 indicated that the lack of reimbursement from an insurance company would result in unwillingness to use dermoscopy among U.S. practitioners.<sup>53</sup>

One cohort study on non-whites in Brazil evaluated the effectiveness of dermoscopy in individuals with darker pigmentation.<sup>70</sup>

### **Primary Care Setting**

One study examined the difference in accuracy between dermatologists and primary care physicians in diagnosing melanoma.<sup>71</sup> One RCT evaluated the effect of training versus no training in the use of dermoscopy in primary care physicians.<sup>72</sup> One nonrandomized intervention study evaluated the effect of training primary care physicians in the use of dermoscopy and short-term sequential digital dermoscopy.<sup>73</sup>

Although dermoscopy has not been evaluated for patient self use, a recent report described two patients who used dermoscopy themselves to help identify suspicious skin lesions during skin self-examination.<sup>74</sup>

### **Diagnostic Accuracy**

A total of 86 primary studies and five systematic reviews evaluated general and digital dermoscopy; specific dermoscopic image features; particular classification schemes and/or algorithms; teledigital dermoscopy; and/or computer-aided analyses for diagnostic accuracy.

One systematic review compared the diagnostic odds ratios for melanoma across the different algorithms of dermoscopy.<sup>75</sup> (Table 1) Three systematic reviews investigated the diagnostic accuracy of dermoscopy compared with naked eye examination for melanoma.<sup>76-78</sup> Most of the primary studies did not address the issue of potential verification bias as it was likely that only those patients with clinically suspicious lesions received biopsies. One systematic review examined the diagnostic accuracy of conventional dermoscopy compared with computer-aided dermoscopy for the diagnosis of melanoma.<sup>75</sup>

**Table 2. Algorithms used in dermoscopy**

Type of algorithm	Description
ABCD rule	lesion asymmetry, border, color, differential structure
A(A)BCD	lesion asymmetry, (differential structures in $\geq 1$ axis), border, color, differential structure
ABCDE	lesion asymmetry, border, color, differential structure, elevation
A(A)BCDE	lesion asymmetry, (differential structures in $\geq 1$ axis), border, color, differential structure, elevation
7FFM	7 features of melanoma: pseudopods, radial streaming, regression-erythema, gray-blue veil, non-homogeneity, irregular pigment network, sharp margin
Pattern analysis	specific patterns, colors, intensities of pigmentation, configuration, regularity, characteristics of margin and surface of pigmented lesions
3-point checklist score	asymmetry of color/structure, atypical network, blue-white structures
7 point-checklist score	atypical pigment network, blue-whitish veil, atypical vascular pattern, irregular streaks, irregular pigmentation, irregular dots and globules, regression structures
Menzies score	not present: symmetry and single color; at least one feature: blue-white veil, brown dots, pseudopods, radial streaming, scar-like depigmentation, peripheral black dots/globules, 5-6 colors, blue/gray dots, broadened network

**Training to increase accuracy.** Seven studies analyzed pre-post training in the use of dermoscopy to increase the accuracy of detection of melanoma. Most training programs were relatively short in duration (1 day to 2 weeks (1 hour per day for 2 weeks in a Web-based course)) and consisted of didactic sessions and/or interactive sessions with experienced instructors.

## FDA Status

The following devices have received Class I FDA approval status: EpiScope<sup>®</sup> Skin Surface Microscope (Model 47300) [Welch Allyn, USA; decision year 1992], NevoScope (TransLite USA; decision year 1996), Dermoscope (American Diagnostic Corp, USA; decision year 1999), and MoleMax (Derma Medical Systems; decision year 1999). The following is a Class II device: microDERM<sup>®</sup> (Visiomed AG, USA; decision year 2004).

## Summary

Of the 431 abstracts reviewed in this brief, only three were RCTs. Almost all of the primary studies on dermoscopy were non-randomized. The non-randomized studies tended to focus on features of dermoscopic image that would be of diagnostic interest; digital dermoscopy and the use of computer-based analyses; and evaluations of different algorithms and classification schemes. We did not identify any controlled studies examining the use of dermoscopy to increase the detection rate of early stage melanoma. The primary studies that reported patient outcomes largely focused on number of new lesions and how lesions had evolved. No study reported on how the addition of dermoscopy affected survival from melanoma.

One RCT did compare dermoscopic evaluation and naked-eye examination in 73 primary care physicians in Italy and Spain and inferred the effect of the addition of dermoscopy on the likelihood that a primary care physician would fail to refer a patient with suspicious skin lesions for a second expert opinion. A second RCT of 913 patients in Italy examined the downstream effect on the number of skin lesion excised for diagnostic verification with the addition of dermoscopy in a pigmented lesion clinic.

## Devices in Limited Clinical Use

The devices described in this section include those that are not in general use, those for which we were unable to identify any RCTs to evaluate patient or health outcomes, or those for which we found no evidence of FDA approval/clearance for use in the evaluation of suspicious skin lesions. Some of these technologies have been used in other clinical context over several years (e.g., ultrasound and photodynamic diagnosis). Recent modifications increase their potential (or future) application to skin cancer detection.

## Confocal Microscopy

Confocal scanning laser microscopy (CSLM) aids in the evaluation of skin lesions by providing high resolution skin tissue images that are similar to histopathological images.<sup>79</sup> This technique works by first projecting a low-power laser beam through a lens on a specific point on the skin, and then detecting the light reflected from the focal point through a confocal pinhole filter. The reflected light is transformed into an electrical signal, which is recorded as an image by a computer.<sup>79-81</sup> Although there is some variability by manufacturer, these devices allow the user to evaluate the lesion at the cellular level.

## Available Literature

Our systematic literature search of MEDLINE<sup>®</sup> identified 72 abstracts relevant to confocal microscopy from the following types of studies: 17 narrative reviews, 12 technical reports, 7 diagnostic tests, 6 comparative cohorts, 26 noncomparative cohorts, and 4 case reports (see Appendix D, Table D1). Reported clinical settings included 14 dermatology, 2 primary care, and 1 oncology practice. Identified studies addressed the use of confocal microscopy in patients with suspected melanoma (n=29, 40.2%) and NMSC (n=15, 20.8%). Several studies (n=28, 39%) addressed its use in a combination of skin cancer types. (See Appendix D, Table D2) The most commonly reported outcome was lesion characterization (27 studies), followed by test accuracy (17 studies) (see Appendix D, Table D4). No clinical outcomes were identified.

We identified eight observational studies of confocal microscopy on the ClinicalTrials.gov registry (see Appendix C, Table C2). Five of these studies specified the use of reflectance confocal microscopy; the rest did not specify the type of technique. Although three studies were completed and one was suspended, results for these studies were not posted.

Topics covered in these abstracts included: (1) features of microscopic images histopathological correlates (36 abstracts); (2) general overview of the technology and its use (20 abstracts); (3) test accuracy including sensitivity and specificity data (10 abstracts); (4) technical report and glossary (3 abstracts); (5) diagnostic algorithms and automation (2 abstracts); and (6) other 2 abstracts). Out of the 36 studies that reported features of images and histopathological correlates, only 6 studies had more than 100 participants. All 10 studies that provided test accuracy data were done out of the US (6 in Austria, 1 in Australia, 1 in Germany, 1 in England, 1 in Sweden).

## Description of Technique

Resolution of CSLM images is specific to each device, and is determined by the wavelength of the laser beam, the topical aperture of the lens, and the size of the pinhole.<sup>80</sup> The maximum depth of imaging is 350  $\mu\text{m}$ . The uniqueness of CSLM lies in its imaging of not only the epidermis, but also underlying structures and the papillary dermis. With its high resolution,

CSLM images can be evaluated in detail for the diagnosis of skin cancer and characterization of lesions.<sup>79</sup>

Confocal microscopy images are in grayscale, therefore structures with higher reflectance are bright over a dark background. Standardized terminology for the evaluation of reflectance of confocal microscopy images was developed at an online consensus meeting between 2004 and 2005 and subsequently published.<sup>82</sup> Although initial models of CSLM were bulky, hand held confocal devices are now available.

### **Theoretical Advantages**

Compared with other noninvasive modalities, the major strength of CSLM is the capability to produce high resolution images of cellular components with precision close to that of histology. Several studies in lentigo maligna melanoma, amelanotic melanoma and diagnostic accuracy in equivocal lesions by dermatoscopy pointed out the clinical use of confocal microscopy in the examination of suspicious lesions.<sup>83-86</sup> Our key informants remarked that this technology may present an opportunity to obtain the same information as a histopathological diagnosis without performing a biopsy, especially for initial screening.

At long wavelengths, papillary dermis can be accessed. In addition, the images can be used in tele-pathology with certain commercially available data storage and transfer systems. Furthermore, confocal microscopes do not have direct contact with the skin under evaluation.

### **Theoretical Disadvantages**

Despite its various theoretical advantages, CSLM is not without limitations. First, the high cost of confocal microscopes is an obstacle to the widespread diffusion of this technique.<sup>87</sup> Second, compared with conventional histology, CSLM images have poorer resolution of microscopic structures including chromatin patterns, nuclear contours, and nucleoli, and therefore, deeper structures, located in the reticular dermis, cannot be examined.<sup>39</sup> Third, CSLM images allow evaluation of micro-anatomical structures of about 300  $\mu\text{m}$  only, again limiting examination to the upper dermal layers.<sup>39</sup>

### **Variations of Technique**

- Confocal scanning laser microscopy. This type can be in either reflectance or fluorescence mode. In reflectance CSLM, laser-illuminated tissue structures and melanin reflect light toward the confocal microscope detector.<sup>88</sup> It is more commonly used in a clinical setting, and can be either diffuse or polarized.<sup>39</sup> In fluorescence CSLM, a laser beam excites the endogenous or exogenous fluorescent molecules, which emit the signals to the confocal microscope detector.<sup>39</sup> Fluorescence CSLM is used primarily in research.
- One manufacturer, Lucid, Inc., produced three models of confocal microscopes. The newest model, called VivaScope<sup>®</sup> 3000, is a handheld device, which overcomes the size limitations in the previous models. Lucid also developed the VivaNet<sup>®</sup> Digital Imaging and Communications in Medicine, which allows storage and transfer of confocal microscopy images among healthcare providers in different geographic locations. According to a general review, Optiscan Pty. Ltd. also manufactures confocal microscopes, named Optiscan.<sup>TM39</sup>

## **FDA Status**

We identified the confocal microscopy devices from both Lucid, Inc. and Optiscan Pty. Ltd. from the FDA CDRH database. Although the Optiscan Pty. Ltd. device has achieved FDA clearance, the intended use stated in its FDA approval summary was for use during endoscopic medical procedures. The series of VivaScope devices (Lucid, Inc, USA) and Optiscan™ have received the FDA Class II status; the former in 2008, the latter in 2010.

## **Summary**

In this brief, no systematic review or controlled trial on confocal microscopy was found. Although observational studies describing the use of confocal microscopy exist, data from comparative studies with longitudinal followup among large populations are lacking. Additionally, test accuracy of this technology is yet to be formally demonstrated in the United States, despite some test accuracy data from Europe and Australia.

## **Ultrasound/Laser Doppler**

Ultrasound with and without laser Doppler has been used in clinical practice for decades. Its primary use in dermatology has been adjunctive. Recent advances in ultrasound, particularly higher frequency scanners and the availability of color Doppler, have increased the capability of this device in the evaluation of suspicious skin lesions. For example, with high frequency scanners of between 20 and 50 MHz, clear definition of skin layers is possible, while with lower frequency scanners information on deeper tissue penetration is provided.

## **Available Literature**

The literature we reviewed identified 34 abstracts relevant to Ultrasound/Laser Doppler, and Ultrasound in combination with other techniques found in a combination of radiological and clinical journals. There were 16 primary studies, comprised of 2 comparative cohort studies, 7 non-comparative cohort studies, and 7 diagnostic test reports. In addition, there were 18 reviews including 6 narrative review and 12 technical reports. (See Appendix D, Table D1). The most commonly reported outcome was lesion characterization (8 studies) with test accuracy being the second most common (5 studies) (see Appendix D, Table D4).

A review of the ClinicalTrials.gov database revealed only one study on the use of ultrasound. This study combined the use of ultrasound with laser Doppler, with the stated aim of early detection of metastatic melanoma (NCT00776945, accessed November 5, 2010). This observational study is scheduled to be completed in December 2014.

## **Description of Technique**

Ultrasound with high frequency scanners of 20 to 50 MHz is useful as an adjunct in the accurate diagnosis of skin lesions.<sup>39,89</sup> High frequency ultrasound provides information on lesion quality and inner structure of tumors, based on different echogenic properties.<sup>89</sup> Current ultrasound imaging techniques allow for the three-dimensional C-mode (computed) scanning of structures in the skin in vivo. A review of the identified literature reported that ultrasound is primarily used in pre-planning for therapy and surgery (for examples see Guitera 2008,<sup>90</sup> Vilana 2009,<sup>91</sup> Pellacani 2003<sup>92</sup>) through its 3D imaging of malignant processes.<sup>93-95</sup> It is also used as an adjunct in the accurate diagnosis of skin lesions.<sup>39,89</sup> Two studies combining high-frequency ultrasound with dermoscopy<sup>96,97</sup> reported possible improvement in diagnostic accuracy (over sonography alone), and helpful information about tumor depth and location to assist in surgical



planning. Ultrasound biomicroscopy (UBM), a technique generally used in the diagnosis of various eye abnormalities, has demonstrated preliminary usefulness in differentiating the histological components of cutaneous BCC and SCC,<sup>98,99</sup> and eyelid lesions.<sup>100</sup> For patients with BCC, High Frequency Ultrasound has also been explored to evaluate tumor margins.<sup>101</sup>

### **Theoretical Advantages**

Ultrasound is advantageous in the evaluation of skin lesions because it is noninvasive, reproducible, safe, and cost effective.<sup>39,89,102,103</sup> Depth and thickness of a variety of tumors can be evaluated including, benign nevi, BCC, SCC, and melanoma.<sup>89</sup> A 2010 retrospective study comparing ultrasound diagnoses with clinical diagnoses versus clinical diagnoses alone, in relation to histologic determination, demonstrated that ultrasound increased accuracy of clinical diagnosis. While referring diagnosis was correct in 73 percent of 4,338 lesions, the addition of the ultrasound evaluation improved diagnostic accuracy to 97 percent (P<0.001 for the difference).<sup>104</sup> The study concluded that noninvasive ultrasound imaging of skin lesions provides important clinical information, which improves accuracy of diagnosis and has value in pre-operative therapy. A 2007 retrospective study examined the usefulness of high frequency ultrasound in the diagnosis of BCC through the identification of hypersonographic spots.<sup>105</sup> This study concluded that multiple (more than five spots per lesion) hypersonographic spots versus other identified patterns of hypersonic spots may assist in differentiating between BCC and melanoma.

### **Theoretical Disadvantages**

A limitation of the technique, identified in Wortsman 2010,<sup>104</sup> was its lack of sensitivity in detecting lesions localized to the epidermis or extremely thin lesions.

### **Variations of Technique**

- Reflex Transmission Imaging (RTI). This is a particular form of high resolution ultrasound that can be joined with white light digital photography for classification of pigmented lesions. The RTI device, termed DermaScanC, reveals the vascularization of tumors seen with color Doppler sonography (B-mode). This technique may reduce the number of referrals for benign tumors without missing melanoma; however, the small number of studies assessing its use and expense may limit its utility.
- Color-coded duplex sonography. This technique involves coupling a B-mode (brightness) image with a pulsed wave Doppler, and provides data on blood flow in real time. One study identified the usefulness of this technique in its ability to distinguish between melanoma and other pigmented skin lesions;<sup>106</sup> two other studies demonstrated its potential as a prognostic tool for the identification of melanoma with high metastatic potential.<sup>107,108</sup>
- Laser Doppler perfusion imaging. This technique is able to discriminate differences in perfusion levels between malignant melanoma and benign pigmented skin lesions. Vascularization of melanoma lesions has been a primary interest for researchers because of the hypothesized theory that vascularization gradually increases during the transition of a lesion from benign to dysplastic to primary melanoma.<sup>39</sup> Early studies regarding the use of this technique to differentiate between benign and malignant melanocytic skin tumors reported its usefulness as a discriminative adjunct in assessment; there were no

abstracts found on this topic since 2004, nor were there any studies listed in ClinicalTrials.gov database.

## **FDA Status**

No information was found on the FDA clearance status for the devices of this type on the FDA CDRH database for use in the evaluation of skin lesions.

## **Summary**

In this brief, no systematic review or completed controlled trial on ultrasound or color Doppler technology was found. The available literature addresses the potential benefit of noninvasive ultrasound imaging of skin lesions as a source of important clinical information to improve accuracy of diagnosis and assist in pre-operative planning. The evidence accessed for this study indicated that, while it was first thought that ultrasound alone would be helpful in differentiating between benign and malignant lesions, research to date supports its use as an adjunct to other diagnostic tools, but does not provide support for its use as a stand-alone tool. Additional trials are needed in order to determine the value of ultrasound/color Doppler techniques in establishing the diagnosis of melanoma or NMSC. Information about training requirements, or evidence of effectiveness among different patient groups (history, race/ethnicity) was not identified.

## **Photodynamic Diagnosis**

Photodynamic diagnosis (PDD) of suspicious skin lesions relies on the fluorescent properties of an exogenous drug or endogenous compound in response to a light source. Topical agents are used to stimulate the production of endogenous photosensitizers that produce a photodynamic effect when exposed to light of certain wavelengths and energy.

## **Available Literature**

Our systematic literature search on MEDLINE<sup>®</sup> identified a total of 22 abstracts, 16 of which dealt with PDD for BCC, two for use with suspected melanoma, and four that addressed a combination of NMSC (n=2) or skin cancer type not specified (n=2) (see Appendix D, Table D2). These abstracts were reported principally in technical journals, rather than clinical journals. These abstracts included six primary studies, including one RCT, four comparative cohort studies and one single case report. The remainder of the studies were narrative reviews (n=9) or technical reports (n=7) (see Appendix D, Table D1). The single RCT, reported from Sweden, was designed to evaluate the tolerance threshold of four different application times of 5-aminolevulinic acid (ALA) in 40 patients (10/group). The endpoint of the study was the fluorescence intensity between normal skin and tumor tissue. In the remainder of the primary studies, two reported on lesion characterization and three reported on test accuracy. (see Appendix D, Table D4). No clinical outcomes were reported.

We identified a single study of photodynamic diagnosis in the ClinicalTrials.gov registry (see Appendix C, Table C2). This study, not yet open for participant recruitment, is designed to evaluate the effect of the topical application of ALA on protoporphyrin formation among patients with NMSC. As noted in the section on confocal microscopy, confocal laser scanning microscopy will be employed as part of the study outcome assessment.

## Description of Technique

Topical application of ALA has been shown to produce increased concentration of endogenous protoporphyrin IX (PpIX), which has high fluorescent yield.<sup>109</sup> Studies have shown that PpIX accumulates in skin tumors at a much higher concentration than in normal skin.<sup>103,110</sup>

## Theoretical Advantages

To enhance differentiation between normal skin and tumor, shorter exposure times to ALA have been shown to be promising.<sup>111</sup> Newer lipophilic derivatives of ALA have been shown to increase local bioavailability of these agents and may extend the clinical application of PDD.<sup>112</sup> PDD may be helpful in guiding biopsies, especially in anatomically difficult sites (e.g., nose, ear),<sup>111</sup> and aid in preoperative planning, although the evidence for this claim is mixed.<sup>113-116</sup> PDD also may be useful in detecting recurrences or multifocal disease.<sup>117</sup> Application of ALA or other prodrugs has been shown to be especially useful in detecting BCC and SCC.

## Theoretical Disadvantages

The use of PDD in melanoma detection has been less promising than in the nonmelanomatous lesions, because it may not have sufficient good sensitivity and specificity in detecting the disease, when compared to biopsy. Chwirot 1998, reporting on 90 known melanomatous lesions, detected only an 82.5 percent sensitivity and a 78.6 percent specificity using autofluorescence.<sup>118</sup> In a 2008 review, Allison and Sibata conclude that the application of PDD to melanoma is still “a work in progress.”<sup>119</sup> Recent techniques using laser-induced melanin fluorescence have been shown to differentiate malignant melanoma from benign lesions.<sup>120</sup> Ultraviolet photography, described below, also relies on the fluorescent properties of melanin.

## Variations of Technique

- Ultraviolet light photography. Ultraviolet light is absorbed by melanin. The theory behind this experimental technique is that illumination by ultraviolet light could reveal irregular pigment distribution, and therefore could be useful in defining the borders of melanoma (e.g., lentigo maligna melanoma).<sup>66</sup> It is unclear how widespread the use of this technique is in the dermatology community, as we did not identify any other abstracts related to this technique as used in the detection of melanoma.
- Polarized light photography. This method relies on the fact that reflected light has two components—one regular reflectance to reflect the skin surface morphology, the other “back-scattered” from within the tissue.<sup>121</sup> It is useful in the assessment of skin surface morphology when the proper polarizing filters and techniques are used. It can be used in the assessment of dermal melanosis. It is not widely used for assessing skin pigmentation; Taylor 2006 and others have highlighted the limitations of polarized light photography in darker skinned persons with Fitzpatrick skin types IV, V, and VI.<sup>22,121</sup>
- Other topical therapies, principally used in the treatment of nonmelanomatous skin cancer, such as imiquimod and 5-FU could be used in combination with photography to highlight skin cancers.

## FDA Status

No information was found on the FDA clearance status for the devices of this type on the FDA CDRH database for use in the diagnostic evaluation of skin lesions.

## Summary

In this brief, a single RCT of PDD was found in which the technical aspects of method were explored. Much of the extant literature addresses the technical aspects of the photosensitizers or the available different light sources. Although the available literature addresses the potential benefit of this method in directing or limiting potentially disfiguring biopsies for patients with nonmelanomatous skin lesions, there is little to no evidence to support the use of this method in melanoma given current data on test accuracy. Information about training requirements or optimum clinical setting was also not identified.

## Investigational Devices

### Multiphoton Laser Scanning Microscopy

Multiphoton laser scanning microscopy, also known as multiphoton fluorescence microscopy or multiphoton excitation microscopy, uses more than one photon excitation to illuminate endogenous fluorophores in skin tissues, which emits a fluorescence signal to be captured by a detector.<sup>122</sup> Similar to CSLM, it uses laser beam and allows imaging of tissues beyond the superficial epidermis. Unlike CSLM, this technique does not use a confocal pinhole filter.<sup>123,124</sup> Evidence of the current application of this modality is sparse. Our systematic literature search identified three narrative reviews and two diagnostic studies of multiphoton microscopy or tomography (see Appendix D, Table D1).

We identified two registered cross-sectional studies that assess the use of this technology for skin lesion evaluation. Both studies are based in Taiwan and are recruiting participants (see Appendix C, Table C2). The only commercially available device for multiphoton tomography is DermaInspect<sup>®</sup>, manufactured by JenLab in Germany ([jenlab.de/DermaInspect-R.29.0.html](http://jenlab.de/DermaInspect-R.29.0.html)). We could not determine the FDA clearance status for this device on the FDA CDRH database (see Appendix C, Table C1).

### Electrical Bio-Impedance

Different biological tissues have different electrical impedance spectra. The spectrometer measures impedance in different frequencies (1 to 1000 kHz) as different frequencies reflect different tissue properties. Skin electrical impedance has been found to be statistically different depending on tissue types (e.g., impedance of benign pigmented nevi has been shown to be different from basal cell carcinoma).<sup>125</sup> One group of authors reported using the SciBase I noninvasive electrical impedance spectrometer (SciBase AB, Huddinge, Sweden) to measure impedance of different skin lesions. The use of electrical bio-impedance in the detection of skin cancer remains investigational at this time. The five abstracts on bio-impedance that we identified were all published before 2006 (see Appendix D, Table D1).

A proposed advantage of bioelectrical impedance is that the data generated from this technology can complement information from visual inspection, and help prevent misdiagnosis of basal cell carcinoma and other types of skin cancer.<sup>126</sup> Even though statistically significant differences in impedance were found between tissue types in Aberg 2003,<sup>125</sup> the degree of overlap and within group variance were too high to allow for easy clinical differentiation based on impedance measurements.

A search of the ClinicalTrials.gov Web site (accessed November 3, 2010) identified an international, prospective, non-randomized study that collected data for optimization of an algorithm to classify skin lesions using electrical impedance. This study has been completed, but

the results have yet to be posted (see Appendix C, Table C2). A non-randomized study is currently recruiting participants to collect data on sensitivity and specificity of SciBase III electrical impedance spectrometer to detect melanoma and the data will be used to support a Pre-market Application to obtain FDA approval (NCT01077050) [see Appendix C, Table C1].

## Optical Coherence Tomography

Optical Coherence Tomography (OCT) is an imaging technique—akin to an optical ultrasound—that utilizes reflected light to produce cross-sectional subcutaneous images of tissue at a resolution equivalent to a low-power microscope. This technique provides tissue morphology imagery at a higher resolution (smaller than 10  $\mu\text{m}$ ) than modalities such as MRI or ultrasound. OCT allows for instant, real-time sub-surface images of tissue morphology at near-microscopic resolution and requires no preparation of the sample/subject and no ionizing radiation.

Our search identified five abstracts<sup>127-131</sup> examining OCT's application to the diagnosis of skin cancer (see Appendix D, Table D1). Two abstracts summarized technical reports.<sup>130,131</sup> A 1997 technical report describes OCT as a promising *new* noninvasive diagnostic imaging method for the visualization of morphologic changes of superficial layers of human skin.<sup>131</sup> A 2005 technical report describes possible histopathologic correlates of dermoscopic structures identified using OCT.<sup>130</sup> Olmedo 2006<sup>129</sup> presents findings from a noncomparative cohort study of 23 patients (49 lesions) utilizing OCT to characterize basal cell carcinoma *in vivo*. The Mogensen 2009<sup>128</sup> narrative review described OCT as an “emerging imaging technology” that is “still evolving and continued technological development will necessitate an ongoing evaluation of its diagnostic accuracy.” Additionally, “OCT is being integrated in multimodal imaging devices that would potentially be able to provide a quantum leap to the imaging of skin *in vivo*”. Forsea 2010<sup>127</sup> investigates the “utility of OCT for the diagnosis of non-melanocytic, non-pigmented cutaneous tumors”. The comparative cohort study assessed 15 patients with clinical suspicion of epithelial cancers and precancers along with 7 control patients with inflammatory skin diseases. All patients had perilesional skin documented by clinical digital photography, contact dermoscopy with digital image capture and OCT—final diagnoses were certified by histology. Results demonstrated that OCT “appears as a promising method of *in vivo* diagnosis of early neoplastic cutaneous lesions”. Moreover, combining OCT and dermoscopy for lesion evaluation resulted in improved diagnostic performance when compared to clinical diagnosis, OCT or dermoscopy alone.

A recent search on the ClinicalTrials.gov Web site (accessed 11-3-2010) identified one observational study investigating the diagnostic value and possibilities of OCT in non-melanoma skin cancer. The study is currently recruiting participants (see Appendix C, Table C2). No information was found on the FDA clearance status for the devices of this type on the FDA CDRH database.

## Tape Stripping

Tape Stripping is a noninvasive ‘biopsy’ technology used to analyze superficial cells harvested from pigmented skin lesions (PSLs) suspected of being early melanomas. Cells from the upper epidermis are stripped off using an adhesive tape, and RNA from the PSL is harvested and analyzed via ribonuclease protection assay (RPA) to differentiate malignancies on the basis of gene expression profiles. A 1992 study<sup>132</sup> of 150 PSLs concluded, based on estimates of sensitivity and specificity of tape stripping for the diagnosis of malignant melanoma, that this

method may be a helpful diagnostic tool when used in conjunction with ABCDE guidelines. DermTech International ([www.dermtech.com](http://www.dermtech.com)) developed and patented the commercialized form of this technology. DermTech's Epidermal Genetic Information Retrieval (EGIR™) utilizes a custom adhesive film to collect surface skin samples. EGIR™ is reported to be quick and painless and can be applied to virtually any skin surface. To help increase diagnostic accuracy, EGIR™ allows for re-testing of lesions. In a 2011 study by Wachsman, reporting on the testing with an independent dataset, this classifier discerned in situ and invasive melanomas from naevi with 100-percent sensitivity and 88-percent specificity, with an area under the curve for the receiver operating characteristic of 0.955.<sup>133</sup>

A recent search on the ClinicalTrials.gov Web site (accessed November 3, 2010) identified one non-randomized study, sponsored by DermTech International, assessing tape stripping for diagnosis of early stage melanoma. This study has been terminated (withdrawn per sponsor and investigator), and results have not been posted (see Appendix C, Table C2). No information was found on the FDA clearance status for the devices of this type on the FDA CDRH database.

## **Thermography**

Dermatologic use of thermography involves measuring and mapping surface skin temperature through direct contact (via application of liquid crystal plates to a part of the body) or at a distance (utilizing a highly-sensitive medical infrared camera and sophisticated computer interface). A single narrative review<sup>134</sup> published in 1995 from the San Gallicano Dermatological Institute for Research and Care in Italy assessed thermography and its potential application in clinical and experimental dermatology. Among the topics reviewed was the clinical use of thermography as a diagnostic tool for cutaneous melanoma. The review reports that due to high percentages of false-negative results from studies in the 1980s,<sup>135,136</sup> the use of thermography as a stand-alone diagnostic tool for melanoma has diminished. However, thermography used in conjunction with thermostimulation (application of thermal stress on the skin to be examined) has allowed for better differentiation of melanoma from other types of pigmented lesions. A recent search of the ClinicalTrials.gov Web site (accessed 11-3-2010) identified one trial studying the application of infrared thermography to find skin lesions in patients with Kaposi's sarcoma—a topic outside the scope of this technical brief. No information was found on the FDA clearance status for the devices of this type on the FDA CDRH database.

## **Multispectral Imaging and Fully Automated Computer-Based Analysis**

A fully automated device that has been reported in the literature is a device that captures multispectral images of a pigmented lesion in 10 bands, from blue to near infrared (MelaFind , MELA Sciences Inc, Irvington, New York). It uses automated image analysis and statistical pattern recognition to help identify lesions that should be considered for biopsy. This multispectral imaging system shows quantitative and more objective results compared with conventional dermoscopic analysis, which is qualitative and potentially subjective.<sup>37</sup> Diagnostic performance in a prospective, multicenter study of patients with at least one pigmented lesion scheduled for biopsy was recently reported.<sup>137</sup> This device is currently undergoing an FDA Premarket Approval review for use by dermatologists.

## Summary and Implications

The present technology brief assessed the current state of science regarding noninvasive diagnostic techniques for the detection of skin cancers, particularly BCC, SCC, and melanoma. In addition, we sought to assess the clinical application of these modalities and their diffusion across specialty/subspecialty groups.

Based on these objectives, we found that the use of photography to capture suspicious skin lesions of the entire body for monitoring purposes is commonly used in dermatology practices, but not typically in a primary care setting. Photographic surveillance is recommended for patients at high risk of skin cancer, based on family history, history of dysplastic nevi, or history of prior malignant lesions.<sup>48,49</sup> However, the age of onset and frequency at which it should be performed is unclear. The affordability and adaptability of digital imaging permit the increased ease of electronic image storage and allow for side-by-side comparisons at future visits. The evolution of computerized imaging systems has also enhanced the ability to convey these lesions from patients to providers and across provider types. The available data are limited on the role of photography in changing clinical outcomes, including confirmation that baseline photographs in specialty clinics improve the detection of melanoma, resulting in detection of earlier stage lesions, or recurrent lesions. While there are some studies, principally from Australia, about the impact of photography in primary care settings, no similar studies have been conducted in the United States.

In addition, we found that approximately half of recently surveyed U.S. dermatologists use some form of dermoscopy (polarized light noncontact, polarized light contact, and nonpolarized light immersion).<sup>57</sup> Except for anecdotal information describing the use of dermoscope in primary care settings, it is not routinely used in non-dermatologist settings. A handheld dermoscope can provide at least a 10-fold magnification of skin lesions and aid in the assessment of pigmented or papulosquamous lesion morphology. Almost all the primary studies on dermoscopy were non-randomized. The non-randomized studies tended to focus on features of dermoscopic image that would be of diagnostic interest. We did not identify any controlled studies examining the use of dermoscopy to increase the detection rate of early stage melanoma. The primary studies that reported patient outcomes largely focused on number of new lesions and how lesions had evolved. No study reported on how the addition of dermoscopy affected survival from melanoma.

One RCT did compare dermoscopic evaluation and naked-eye examination in primary care physicians in Italy and Spain and inferred the effect of the addition of dermoscopy on the likelihood that a primary care physician would fail to refer a patient with suspicious skin lesions for a second expert opinion. A second RCT of patients in Italy examined the downstream effect on the number of skin lesion excised for diagnostic verification with the addition of dermoscopy in a pigmented lesion clinic. Whether the findings from the two European RCTs are applicable to the U.S. population and whether they could be further translated into actual detection of different forms of skin cancer and/or affecting survival in afflicted patients are uncertain as the practice patterns are different between the two countries and no trials that examined the effects of the addition of dermoscopy to naked eye examinations reported on these outcomes. Based on the abstracts reviewed, we surmise that the actual conduct of dermoscopy as practiced in a U.S. dermatology setting must be quite heterogeneous owing to the different available algorithms, devices, training, and practitioner's experience and belief about the benefits of this technology.

Any new trials in the United States investigating the benefit of dermoscopy compared with naked eye examination in affecting health outcomes will have to take into account this heterogeneity.

Similarly, dermatologists are the primary users of confocal scanning laser microscopy (CSLM), which aids in the evaluation of skin lesions by providing high resolution skin tissue images that are similar to histopathological images. The high cost of confocal microscopes is an obstacle to the widespread diffusion of this technique. There are no trials comparing CSLM with the use of other diagnostic techniques (such as clinical examination or dermoscopy). Reported outcomes in cohort studies mainly focused on lesion characterizations by CSLM and its test accuracy.

While numerous other modalities, including high frequency ultrasound/Doppler and PDD, are available, their use is still limited in clinical practice, and several, such as multiphoton microscopy, bio-electrical impedance, OCT, tape stripping, multispectral imaging and fully automated computer-based analysis, and thermography, are considered investigational. There are virtually no trials that compare their accuracy and patient outcomes with conventional histological determination. Test accuracy of many of these investigational modalities has not been adequately assessed. It is unclear whether these modalities perform better in diagnosing certain types of skin cancer or among subgroups of patients, such as specific ethnic/racial groups or history of prior cancer (skin or other site). In addition, evidence supporting the use of these investigational modalities to replace further diagnostic evaluation is lacking. Little to no data was available to assess the safety and potential harms related to the use of these technologies. Research on the use, diffusion, and training of different modalities has yet to be conducted. In summary, for most of these technologies, the abstracts we identified addressed their technical efficacy and/ or diagnostic accuracy efficacy, leaving unanswered questions enumerated above.



## Next Steps

Only three trials examined the use of dermoscopy versus naked eye examination in the evaluation of suspicious skin lesions. Only one reported diagnostic accuracy of dermoscopy compared with naked eye examination.<sup>55</sup> The focus of the other two studies did not concern diagnostic accuracy (one examined the time needed to complete exam with and without dermoscopy;<sup>59</sup> the other studied the referral rate for biopsy with and without dermoscopy<sup>56</sup>) A trial based on a larger number of dermatologists and primary care physicians in the U.S. and using biopsy result as the reference standard and reporting on both intermediate (e.g., number of lesions) and clinical outcomes (e.g., survival) would be informative.

Key informant input suggests that the main challenge to the use of dermoscopy in a primary care setting lies in the training (or lack of) of nonexperts in its technique. As most of the studies on training focused on dermatologists, it would be important to investigate the kinds of training appropriate for primary care practitioners before this technique could be incorporated in a primary care setting.

Because of the wide range of reported diagnostic sensitivities and specificities for the standard dermoscopic algorithms in use, studies should be conducted to better understand the determinants of this reported variability.

A limited number of studies reported on the use of computer-aided diagnoses of suspicious skin lesion. It would be informative to further evaluate the performance of automated computer diagnostic instruments vis-à-vis the ability of an experienced clinician to diagnose skin cancer. It is also important to analyze further specific attributes of images captured by these noninvasive devices (including dermoscopy, confocal laser scanning microscopy, etc.) for their use in computer-aided diagnosis (such as a neural network classifier).

In contrast to the widespread use of many of photodynamic therapies for NMSC and benign skin disorders, the clinical use of photodynamic diagnostic techniques is still investigational. At present, its principal role may be in defining the borders of suspicious lesions, particularly for NMSC, and in differentiating tumor tissue from normal tissue. Whether the use of alternative light sources, like laser, with photodynamic compounds, is helpful in diagnosing melanoma deserves further exploration.

Even though intermediate/process outcomes are important in the use of these noninvasive technologies (e.g., decreasing the interval between referral to specialist and diagnosis and initiation of treatment) to further appreciate their impact, long-term follow up studies with patient-centered outcomes, such as survival and reduction of unnecessary biopsies, should also be undertaken.

To improve understanding of the diffusion of these different technologies, it would be useful to explore how specific population/patient/practice settings (e.g., rural versus urban, individuals with or without previous history of cancer or of different ethnic/racial backgrounds, availability of trained specialists) affect the use and adoption of these newer technologies.

## References

1. American Cancer Society. Cancer Facts & Figures 2009. Atlanta: American Cancer Society. Available at: <http://www.cancer.org/Research/CancerFactsFigures/cancer-facts-figures-2009>. Accessed August 24, 2011.
2. Perkins JL, Liu Y, Mitby PA, et al. Nonmelanoma skin cancer in survivors of childhood and adolescent cancer: a report from the childhood cancer survivor study. *J Clin Oncol* 2005;23(16):3733-3741.
3. Rosenberg CA, Greenland P, Khandekar J, et al. Association of nonmelanoma skin cancer with second malignancy. *Cancer* 2004;100(1):130-138.
4. Hong WK, Bast RC, Hait WN, et al. *Holland-Frei Cancer Medicine*, 8th Edition. Shelton, CT: People's Medical Publishing House USA, 2010.
5. Linos E, Swetter SM, Cockburn MG, et al. Increasing burden of melanoma in the United States. *J Invest Dermatol* 2009;129(7):1666-1674.
6. Hu S, Parmet Y, Allen G, et al. Disparity in melanoma: a trend analysis of melanoma incidence and stage at diagnosis among whites, Hispanics, and blacks in Florida. *Arch Dermatol* 2009;145(12):1369-1374.
7. Gloster Jr HM, Brodland DG. The epidemiology of skin cancer. *Dermatol Surg* 1996;22(3):217-226.
8. Tsao H, Atkins MB, Sober AJ. Management of cutaneous melanoma. *N Engl J Med* 2004;351(10):998-1012.
9. Garbe C, Peris K, Hauschild A, et al. Diagnosis and treatment of melanoma: European consensus-based interdisciplinary guideline. *Eur J Cancer* 2010;46(2):270-283.
10. Australian Cancer Network Melanoma Guidelines Revision Working Party. Clinical Practice Guidelines for the Management of Melanoma in Australia and New Zealand. 2008. Cancer Council Australia and Australian Cancer Network, Sydney and New Zealand Guidelines Group.
11. Screening for skin cancer: U.S. Preventive Services Task Force recommendation statement. *Ann Intern Med* 2009;150(3):188-193.
12. From L, Marret L, Rosen C, et al. Screening for Skin Cancer. June 19, 2007. Cancer Care Ontario.
13. National Guideline Clearinghouse (NGC). Guideline synthesis: Screening and prevention of skin cancer. In: National Guideline Clearinghouse (NGC) [guideline.gov]. Available at: <http://www.guideline.gov>. Accessed November 1, 2009.
14. Goodson AG, Grossman D. Strategies for early melanoma detection: Approaches to the patient with nevi. [Review] [159 refs]. *Journal of the American Academy of Dermatology* 2009;60(5):719-735.
15. Terushkin V, Halpern AC. Melanoma early detection. *Hematol Oncol Clin North Am* 2009;23(3):481-500, viii.
16. Marghoob AA, Swindle LD, Moricz CZ, et al. Instruments and new technologies for the in vivo diagnosis of melanoma. *J Am Acad Dermatol* 2003;49(5):777-797.
17. Thornbury JR, Fryback DG. Technology assessment—an American view. *Eur J Radiol* 1992;14(2):147-156.
18. Improving Outcomes for People with Skin Tumours including Melanoma (update): The Management of Low-risk Basal Cell Carcinomas in the Community. May 1, 2010. Guidance on Cancer Services, the National Collaborating Centre for Cancer (NICE).
19. Rice ZP, Weiss FJ, DeLong LK, et al. Utilization and rationale for the implementation of total body (digital) photography as an adjunct screening measure for melanoma. *Melanoma Research* 2010;20(5):417-421.
20. Shriner DL, Wagner Jr RF. Photographic utilization in dermatology clinics in the United States: a survey of university-based dermatology residency programs. *Journal of the American Academy of Dermatology* 1992;27(4):565-567.

21. Terushkin V, Oliveria SA, Marghoob AA, et al. Use of and beliefs about total body photography and dermatoscopy among US dermatology training programs: an update. *Journal of the American Academy of Dermatology* 2010;62(5):794-803.
22. Rigel DS, Russak J, Friedman R. The evolution of melanoma diagnosis: 25 years beyond the ABCDs. *CA Cancer J Clin* 2010;60(5):301-316.
23. Esmaeili A, Scope A, Halpern AC, et al. Imaging techniques for the in vivo diagnosis of melanoma. [Review] [50 refs]. *Seminars in Cutaneous Medicine & Surgery* 2008;27(1):2-10.
24. Halpern AC, Marghoob AA, Bialoglow TW, et al. Standardized positioning of patients (poses) for whole body cutaneous photography. *Journal of the American Academy of Dermatology* 2003;49(4):593-598.
25. Shriner DL, Wagner Jr RF, Glowczwski JR. Photography for the early diagnosis of malignant melanoma in patients with atypical moles. [Review] [22 refs]. *Cutis* 1992;50(5):358-362.
26. Oakley AM, Reeves F, Bennett J, et al. Diagnostic value of written referral and/or images for skin lesions. *Journal of Telemedicine & Telecare* 2006;12(3):151-158.
27. Harrison SL, Buettner PG, MacLennan R, et al. How good are parents at assessing melanocytic nevi on their children? A study comparing parental counts, dermatologist counts, and counts obtained from photographs. *American Journal of Epidemiology* 2002;155(12):1128-1136.
28. Chiu V, Won E, Malik M, et al. The use of mole-mapping diagrams to increase skin self-examination accuracy. *Journal of the American Academy of Dermatology* 2006;55(2):245-250.
29. Phelan DL, Oliveria SA, Halpern AC. Patient experiences with photo books in monthly skin self-examinations. *Dermatology Nursing* 2005;17(2):109-114.
30. Weinstock MA, Nguyen FQ, Martin RA. Enhancing skin self-examination with imaging: evaluation of a mole-mapping program. *Journal of Cutaneous Medicine & Surgery* 2004;8(1):1-5.
31. Banky JP, Kelly JW, English DR, et al. Incidence of new and changed nevi and melanomas detected using baseline images and dermoscopy in patients at high risk for melanoma. *Archives of Dermatology* 2005;141(8):998-1006.
32. Drugge RJ, Nguyen C, Drugge ED, et al. Melanoma screening with serial whole body photographic change detection using Melanoscan technology. *Dermatology Online Journal* 2009;15(6):1.
33. Feit NE, Dusza SW, Marghoob AA. Melanomas detected with the aid of total cutaneous photography. *British Journal of Dermatology* 2004;150(4):706-714.
34. Wang SQ, Kopf AW, Koenig K, et al. Detection of melanomas in patients followed up with total cutaneous examinations, total cutaneous photography, and dermoscopy. *Journal of the American Academy of Dermatology* 2004;50(1):15-20.
35. Risser J, Pressley Z, Veledar E, et al. The impact of total body photography on biopsy rate in patients from a pigmented lesion clinic. *Journal of the American Academy of Dermatology* 2007;57(3):428-434.
36. Halpern AC, Lieb JA. Early melanoma diagnosis: a success story that leaves room for improvement. [Review] [84 refs]. *Current Opinion in Oncology* 2007;19(2):109-115.
37. Psaty EL, Halpern AC. Current and emerging technologies in melanoma diagnosis: the state of the art. [Review] [109 refs]. *Clinics in Dermatology* 2009;27(1):35-45.
38. Rhodes AR. Intervention strategy to prevent lethal cutaneous melanoma: use of dermatologic photography to aid surveillance of high-risk persons. [Review] [46 refs]. *Journal of the American Academy of Dermatology* 1998;39(2:Pt 1):t-7.

39. Patel JK, Konda S, Perez OA, et al. Newer technologies/techniques and tools in the diagnosis of melanoma. [Review] [172 refs]. *European Journal of Dermatology* 2008;18(6):617-631.
40. Drugge RJ, Nguyen C, Gliga L, et al. Clinical pathway for melanoma detection using comprehensive cutaneous analysis with Melanoscan. *Dermatology Online Journal* 2010;16(8):1.
41. Zhou Y, Smith M, Smith L, et al. Using 3D differential forms to characterize a pigmented lesion in vivo. *Skin Research & Technology* 2010;16(1):77-84.
42. Christensen JH, Soerensen MB, Linghui Z, et al. Pre-diagnostic digital imaging prediction model to discriminate between malignant melanoma and benign pigmented skin lesion. *Skin Research & Technology* 2010;16(1):98-108.
43. Green WH, Wang SQ, Coggnetta Jr AB. Total-body cutaneous examination, total-body photography, and dermoscopy in the care of a patient with xeroderma pigmentosum and multiple melanomas. *Archives of Dermatology* 2009;145(8):910-915.
44. Malvey J, Puig S. Follow-up of melanocytic skin lesions with digital total-body photography and digital dermoscopy: a two-step method. [Review] [41 refs]. *Clinics in Dermatology* 2002;20(3):297-304.
45. Rademaker M, Oakley A. Digital monitoring by whole body photography and sequential digital dermoscopy detects thinner melanomas. *Journal of Primary Health Care* 2010;2(4):268-272.
46. Massone C, Wurm EM, Soyer HP. Teledermatology. [Review] [50 refs]. *Giornale Italiano di Dermatologia e Venereologia* 2008;143(3):213-218.
47. Harrison PV, Kirby B, Dickinson Y, et al. Teledermatology—high technology or not? *Journal of Telemedicine & Telecare* 1998;4:Suppl-2.
48. BlueCross BlueShield of North Carolina. Evidence Based Guideline Total Body Photography. Available at: [http://www.bcbsnc.com/assets/services/public/pdfs/medicalpolicy/total\\_body\\_photography.pdf](http://www.bcbsnc.com/assets/services/public/pdfs/medicalpolicy/total_body_photography.pdf). 2009. Accessed August 23, 2011.
49. Halpern AC. Total body skin imaging as an aid to melanoma detection. [Review] [29 refs]. *Seminars in Cutaneous Medicine & Surgery* 2003;22(1):2-8.
50. Campos-do-Carmo G, Ramos-e-Silva. Dermoscopy: basic concepts. [Review] [22 refs]. *International Journal of Dermatology* 2008;47(7):712-719.
51. venuto-Andrade C, Dusza SW, Agero AL, et al. Differences between polarized light dermoscopy and immersion contact dermoscopy for the evaluation of skin lesions. *Arch Dermatol* 2007;143(3):329-338.
52. Bassoli S, Seidenari S. Benefits of polarized versus nonpolarized dermoscopy. *Expert Review of Dermatology* 2010.
53. Marchionda PJ, Krause LK, Jensen JD, et al. A North American perspective on dermoscopy: benefits, limitations, and grey zones. [Review] [108 refs]. *Giornale Italiano di Dermatologia e Venereologia* 2010;145(1):89-97.
54. Wang SQ, Dusza SW, Scope A, et al. Differences in dermoscopic images from nonpolarized dermoscope and polarized dermoscope influence the diagnostic accuracy and confidence level: a pilot study. *Dermatologic Surgery* 2008;34(10):1389-1395.
55. Argenziano G, Puig S, Zalaudek I, et al. Dermoscopy improves accuracy of primary care physicians to triage lesions suggestive of skin cancer. *Journal of Clinical Oncology* 2006;24(12):1877-1882.
56. Carli P, De G V, Chiarugi A, et al. Addition of dermoscopy to conventional naked-eye examination in melanoma screening: a randomized study. *Journal of the American Academy of Dermatology* 2004;50(5):683-689.
57. Noor O, Nanda A, Rao BK. A dermoscopy survey to assess who is using it and why it is or is not being used. *Int J Dermatol* 2009;48(9):951-952.
58. Massone C, Di SA, Soyer HP. Dermoscopy for skin cancer detection. [Review] [71 refs]. *Current Opinion in Oncology* 2005;17(2):147-153.

59. Zalaudek I, Kittler H, Marghoob AA, et al. Time required for a complete skin examination with and without dermoscopy: a prospective, randomized multicenter study. *Archives of Dermatology* 2008;144(4):509-513.
60. Franz H, Frank R, Rytter M, et al. Allergic contact dermatitis due to cedarwood oil after dermoscopy. *Contact Dermatitis* 1998;38(3):182-183.
61. Salsano E, Pareyson D, Politi LS. Tonic pupil following the use of dermatoscope. *Acta Neurologica Taiwanica* 2009;18(2):148-150.
62. Stauffer F, Kittler H, Forstinger C, et al. The dermatoscope: a potential source of nosocomial infection? *Melanoma Research* 2001;11(2):153-156.
63. Hausermann P, Widmer A, Itin P. Dermatoscope as vector for transmissible diseases - no apparent risk of nosocomial infections in outpatients. *Dermatology* 2006;212(1):27-30.
64. Kelly SC, Purcell SM. Prevention of nosocomial infection during dermoscopy? *Dermatologic Surgery* 2006;32(4):552-555.
65. Binder M, Kittler H, Pehamberger H, et al. Possible hazard to patients from immersion oil used for epiluminescence microscopy. *Journal of the American Academy of Dermatology* 1999;40(3):499.
66. Marghoob AA, Swindle LD, Moricz CZ, et al. Instruments and new technologies for the in vivo diagnosis of melanoma. [Review] [160 refs]. *Journal of the American Academy of Dermatology* 798;49(5):777-797.
67. Braun RP, Rabinovitz HS, Oliviero M, et al. Dermoscopy of pigmented skin lesions. [Review] [98 refs]. *Journal of the American Academy of Dermatology* 2005;52(1):109-121.
68. Engasser HC, Warshaw EM. Dermatoscopy use by US dermatologists: a cross-sectional survey. *J Am Acad Dermatol* 2010;63(3):412-9, 419.
69. Haenssle HA, Korpas B, Hansen-Hagge C, et al. Selection of patients for long-term surveillance with digital dermoscopy by assessment of melanoma risk factors. *Archives of Dermatology* 2010;146(3):257-264.
70. De GV, Trez E, Salvini C, et al. Dermoscopy in black people. *British Journal of Dermatology* 2006;155(4):695-699.
71. Chen SC, Pennie ML, Kolm P, et al. Diagnosing and managing cutaneous pigmented lesions: primary care physicians versus dermatologists. *J Gen Intern Med* 2006;21(7):678-682.
72. Westerhoff K, McCarthy WH, Menzies SW. Increase in the sensitivity for melanoma diagnosis by primary care physicians using skin surface microscopy. *British Journal of Dermatology* 2000;143(5):1016-1020.
73. Menzies SW, Emery J, Staples M, et al. Impact of dermoscopy and short-term sequential digital dermoscopy imaging for the management of pigmented lesions in primary care: a sequential intervention trial. *British Journal of Dermatology* 2009;161(6):1270-1277.
74. Goulart JM, Malvey J, Puig S, et al. Dermoscopy in skin self-examination: A useful tool for select patients. *Archives of Dermatology* 2011;147(1):53-58.
75. Rajpara SM, Botello AP, Townend J, et al. Systematic review of dermoscopy and digital dermoscopy/artificial intelligence for the diagnosis of melanoma. [Review] [95 refs]. *British Journal of Dermatology* 2009;161(3):591-604.
76. Vestergaard ME, Macaskill P, Holt PE, et al. Dermoscopy compared with naked eye examination for the diagnosis of primary melanoma: a meta-analysis of studies performed in a clinical setting. *British Journal of Dermatology* 2008;159(3):669-676.
77. Kittler H, Pehamberger H, Wolff K, et al. Diagnostic accuracy of dermoscopy. [Review] [41 refs]. *Lancet Oncology* 2002;3(3):159-165.

78. Bafounta ML, Beauchet A, Aegerter P, et al. Is dermoscopy (epiluminescence microscopy) useful for the diagnosis of melanoma? Results of a meta-analysis using techniques adapted to the evaluation of diagnostic tests. *Archives of Dermatology* 2001;137(10):1343-1350.
79. Hofmann-Wellenhof R, Wurm EM, Hlgrimm-Siess V, et al. Reflectance confocal microscopy--state-of-art and research overview. *Seminars in Cutaneous Medicine & Surgery* 2009;28(3):172-179.
80. Gonzalez S. Confocal reflectance microscopy in dermatology: promise and reality of non-invasive diagnosis and monitoring. *Actas Dermo-Sifiliograficas* 2009;100:Suppl-69.
81. Branzan AL, Landthaler M, Szeimies RM. In vivo confocal scanning laser microscopy in dermatology. [Review] [57 refs]. *Lasers in Medical Science* 2007;22(2):73-82.
82. Scope A, venuto-Andrade C, Agero AL, et al. In vivo reflectance confocal microscopy imaging of melanocytic skin lesions: consensus terminology glossary and illustrative images. *Journal of the American Academy of Dermatology* 2007;57(4):644-658.
83. Guitera P, Pellacani G, Longo C, et al. In vivo reflectance confocal microscopy enhances secondary evaluation of melanocytic lesions. *Journal of Investigative Dermatology* 2009;129(1):131-138.
84. Guitera P, Pellacani G, Crotty KA, et al. The impact of in vivo reflectance confocal microscopy on the diagnostic accuracy of lentigo maligna and equivocal pigmented and nonpigmented macules of the face. *Journal of Investigative Dermatology* 2010;130(8):2080-2091.
85. Pellacani G, Guitera P, Longo C, et al. The impact of in vivo reflectance confocal microscopy for the diagnostic accuracy of melanoma and equivocal melanocytic lesions. *Journal of Investigative Dermatology* 2007;127(12):2759-2765.
86. Segura S, Puig S, Carrera C, et al. Development of a two-step method for the diagnosis of melanoma by reflectance confocal microscopy. *Journal of the American Academy of Dermatology* 2009;61(2):216-229.
87. Rajadhyaksha M. Confocal microscopy of skin cancers: translational advances toward clinical utility. *Conference Proceedings: 2009;Annual:International-3*.
88. Nehal KS, Gareau D, Rajadhyaksha M. Skin imaging with reflectance confocal microscopy. [Review] [51 refs]. *Seminars in Cutaneous Medicine & Surgery* 2008;27(1):37-43.
89. Zmudzinska M, Czarnecka-Operacz M, Silny W. Principles of dermatologic ultrasound diagnostics. [Review] [22 refs]. *Acta Dermatovenerologica Croatica* 2008;16(3):126-129.
90. Guitera P, Li LX, Crotty K, et al. Melanoma histological Breslow thickness predicted by 75-MHz ultrasonography. *British Journal of Dermatology* 2008;159(2):364-369.
91. Vilana R, Puig S, Sanchez M, et al. Preoperative assessment of cutaneous melanoma thickness using 10-MHz sonography. *AJR Am J Roentgenol* 2009;193(3):639-643.
92. Pellacani G, Seidenari S. Preoperative melanoma thickness determination by 20-MHz sonography and digital videomicroscopy in combination. *Archives of Dermatology* 2003;139(3):293-298.
93. Serrone L, Solivetti FM, Thorel MF, et al. High frequency ultrasound in the preoperative staging of primary melanoma: a statistical analysis. *Melanoma Research* 2002;12(3):287-290.
94. Weichenthal M, Mohr P, Breitbart EW. The velocity of ultrasound in human primary melanoma tissue - implications for the clinical use of high resolution sonography. *BMC Dermatology* 2001;1:1.
95. Schmid-Wendtner MH, Burgdorf W. Ultrasound scanning in dermatology. [Review] [30 refs]. *Archives of Dermatology* 2005;141(2):217-224.
96. Dummer W, Blaheta HJ, Bastian BC, et al. Preoperative characterization of pigmented skin lesions by epiluminescence microscopy and high-frequency ultrasound. *Archives of Dermatology* 1995;131(3):279-285.

97. Krahn G, Gottlob P, Sander C, et al. Dermatoscopy and high frequency sonography: two useful non-invasive methods to increase preoperative diagnostic accuracy in pigmented skin lesions. *Pigment Cell Research* 1998;11(3):151-154.
98. Petrella LI, Pereira WC, Valle HA, et al. Study of superficial basal cell carcinomas and Bowen disease by qualitative and quantitative ultrasound biomicroscopy approach. *Conference Proceedings: 2010;Annual:International-6002*.
99. Petrella LI, Valle HA, Issa PR, et al. Study of cutaneous cell carcinomas ex vivo using ultrasound biomicroscopic images. *Skin Research & Technology* 2010;16(4):422-427.
100. Bajaj MS, Aalok L, Gupta V, et al. Ultrasound biomicroscopic appearances of eyelid lesions at 50 MHz. *Journal of Clinical Ultrasound* 2007;35(8):424-429.
101. Desai TD, Desai AD, Horowitz DC, et al. The use of high-frequency ultrasound in the evaluation of superficial and nodular basal cell carcinomas. *Dermatologic Surgery* 2007;33(10):1220-1227.
102. Il-Muller D, Maschke J. Ultrasonography in dermatology. [Review] [22 refs]. *Journal der Deutschen Dermatologischen Gesellschaft* 2007;5(8):689-707.
103. Kennedy JC, Marcus SL, Pottier RH. Photodynamic therapy (PDT) and photodiagnosis (PD) using endogenous photosensitization induced by 5-aminolevulinic acid (ALA): mechanisms and clinical results. [Review] [53 refs]. *Journal of Clinical Laser Medicine & Surgery* 1996;14(5):289-304.
104. Wortsman X, Wortsman J. Clinical usefulness of variable-frequency ultrasound in localized lesions of the skin. *Journal of the American Academy of Dermatology* 2010;62(2):247-256.
105. Uhara H, Hayashi K, Koga H, et al. Multiple hypersonographic spots in basal cell carcinoma. *Dermatologic Surgery* 2007;33(10):1215-1219.
106. Bessoud B, Lassau N, Koscielny S, et al. High-frequency sonography and color Doppler in the management of pigmented skin lesions. *Ultrasound in Medicine & Biology* 2003;29(6):875-879.
107. Lassau N, Koscielny S, Avril MF, et al. Prognostic value of angiogenesis evaluated with high-frequency and color Doppler sonography for preoperative assessment of melanomas. *AJR* 2002;American(6):1547-1551.
108. Lassau N, Lamuraglia M, Koscielny S, et al. Prognostic value of angiogenesis evaluated with high-frequency and colour. Doppler sonography for preoperative assessment of primary cutaneous melanomas: correlation with recurrence after a 5 year follow-up period. *Cancer Imaging* 2006;6:24-29.
109. Marcus SL, Sobel RS, Golub AL, et al. Photodynamic therapy (PDT) and photodiagnosis (PD) using endogenous photosensitization induced by 5-aminolevulinic acid (ALA): current clinical and development status. [Review] [23 refs]. *Journal of Clinical Laser Medicine & Surgery* 1996;14(2):59-66.
110. Na R, Stender IM, Wulf HC. Can autofluorescence demarcate basal cell carcinoma from normal skin? A comparison with protoporphyrin IX fluorescence. *Acta Dermato-Venereologica* 2001;81(4):246-249.
111. Fritsch C, Lang K, Neuse W, et al. Photodynamic diagnosis and therapy in dermatology. [Review] [74 refs]. *Skin Pharmacology & Applied Skin Physiology* 1998;11(6):358-373.
112. Fotinos N, Campo MA, Popowycz F, et al. 5-Aminolevulinic acid derivatives in photomedicine: Characteristics, application and perspectives. [Review] [183 refs]. *Photochemistry & Photobiology* 2006;82(4):994-1015.
113. Szeimies RM, Landthaler M. Photodynamic therapy and fluorescence diagnosis of skin cancers. [Review] [19 refs]. *Recent Results in Cancer Research* 2002;160:240-245.
114. Fritsch C, Becker-Wegerich PM, Menke H, et al. Successful surgery of multiple recurrent basal cell carcinomas guided by photodynamic diagnosis. *Aesthetic Plastic Surgery* 1997;21(6):437-439.

115. Lee CY, Kim KH, Kim YH. The efficacy of photodynamic diagnosis in defining the lateral border between a tumor and a tumor-free area during Mohs micrographic surgery. *Dermatologic Surgery* 2010;36(11):1704-1710.
116. Wetzig T, Kendler M, Maschke J, et al. No clinical benefit of preoperative fluorescence diagnosis of basal cell carcinoma localized in the H-zone of the face. *British Journal of Dermatology* 2010;162(6):1370-1376.
117. Vereecken P, Da Costa CM, Steels E, et al. Fluorescence diagnosis of face-located basal cell carcinomas: a new dermatological procedure which may help the surgeon. *Acta Chirurgica Belgica* 2007;107(2):205-207.
118. Chwirot BW, Chwirot S, Redzinski J, et al. Detection of melanomas by digital imaging of spectrally resolved ultraviolet light-induced autofluorescence of human skin. *European Journal of Cancer* 1998;34(11):1730-1734.
119. Allison RR, Sibata CH. Photodiagnosis for cutaneous malignancy: a brief clinical and technical review. [Review] [25 refs]. *Photodiagnosis & Photodynamic Therapy* 2008;5(4):247-250.
120. Eichhorn R, Wessler G, Scholz M, et al. Early diagnosis of melanotic melanoma based on laser-induced melanin fluorescence. *Journal of Biomedical Optics* 14(3):034033-034Jun.
121. Taylor S, Westerhof W, Im S, et al. Noninvasive techniques for the evaluation of skin color. [Review] [32 refs]. *Journal of the American Academy of Dermatology* 2006;54(5:Suppl 2):Suppl-90.
122. Lin SJ, Jee SH, Dong CY. Multiphoton microscopy: a new paradigm in dermatological imaging. [Review] [45 refs]. *European Journal of Dermatology* 2007;17(5):361-366.
123. Paoli J, Smedh M, Ericson MB. Multiphoton laser scanning microscopy—a novel diagnostic method for superficial skin cancers. [Review] [45 refs]. *Seminars in Cutaneous Medicine & Surgery* 2009;28(3):190-195.
124. Tsai TH, Jee SH, Dong CY, et al. Multiphoton microscopy in dermatological imaging. [Review] [51 refs]. *Journal of Dermatological Science* 2009;56(1):1-8.
125. Aberg P, Nicander I, Holmgren U, et al. Assessment of skin lesions and skin cancer using simple electrical impedance indices. *Skin Research & Technology* 2003;9(3):257-261.
126. Beetner DG, Kapoor S, Manjunath S, et al. Differentiation among basal cell carcinoma, benign lesions, and normal skin using electric impedance. *IEEE Transactions on Biomedical Engineering* 2003;50(8):1020-1025.
127. Forsea AM, Carstea EM, Ghervase L, et al. Clinical application of optical coherence tomography for the imaging of non-melanocytic cutaneous tumors: a pilot multimodal study. *Journal of Medicine & Life* 2010;3(4):381-389.
128. Mogensen M, Thrane L, Joergensen TM, et al. Optical coherence tomography for imaging of skin and skin diseases. *Seminars in Cutaneous Medicine & Surgery* 2009;28(3):196-202.
129. Olmedo JM, Warschaw KE, Schmitt JM, et al. Optical coherence tomography for the characterization of basal cell carcinoma in vivo: a pilot study. *Journal of the American Academy of Dermatology* 2006;55(3):408-412.
130. De GV, Stante M, Massi D, et al. Possible histopathologic correlates of dermoscopic features in pigmented melanocytic lesions identified by means of optical coherence tomography. *Experimental Dermatology* 2005;14(1):56-59.
131. Welzel J, Lankenau E, Birngruber R, et al. Optical coherence tomography of the human skin. *Journal of the American Academy of Dermatology* 1997; 37(6):958-963.
132. Berardi P, Arcangeli F. The tape stripping toluidine blue (TSTB) method in the diagnosis of malignant melanoma: an investigator-blind study. *Melanoma Research* 1992;2(2):93-99.
133. Wachsman W, Morhenn V, Palmer T, et al. Noninvasive genomic detection of melanoma. *Br J Dermatol* 2011;164(4):797-806.



134. Di CA. Thermography and the possibilities for its applications in clinical and experimental dermatology. [Review] [38 refs]. *Clinics in Dermatology* 1995;13(4):329-336.
135. Cristofolini M, Perani B, Pisciolli F, et al. Uselessness of thermography for diagnosis and follow-up of cutaneous malignant melanoma. *Tumori* 1981; 67(2):141-143.
136. Amalrich R, Altschuler C, Giraud D. Value of infrared thermography in the assessment of malignant melanoma of the skin. In: Ring EFJ, Phillips B, editors. *Recent advances in medical thermology*. New York/London: Plenum, 2010: 623-629.
137. Monheit G, Cognetta AB, Ferris L, et al. The performance of MelaFind: a prospective multicenter study. *Arch Dermatol* 2011;147(2):188-194.
138. Del Mar CB, Green AC. Aid to diagnosis of melanoma in primary medical care. *BMJ* 1995;310(6978):492-495.
139. Hanrahan PF, Menzies SW, D'Este CA, et al. Participation of older males in a study on photography as an aid to early detection of melanoma. *Australian & New Zealand Journal of Public Health* 2000;24(6):615-618.
140. Hanrahan PF, D'Este CA, Menzies SW, et al. A randomised trial of skin photography as an aid to screening skin lesions in older males. *Journal of Medical Screening* 2002;9(3):128-132.
141. English DR, Burton RC, Del Mar CB, et al. Evaluation of aid to diagnosis of pigmented skin lesions in general practice: controlled trial randomised by practice. *BMJ* 2003;327(7411):375.
142. Oliveria SA, Dusza SW, Phelan DL et al. Patient adherence to skin self-examination. effect of nurse intervention with photographs. *American Journal of Preventive Medicine* 2004;26(2):152-155.
143. Bowns IR, Collins K, Walters SJ, et al. Telemedicine in dermatology: a randomised controlled trial. *Health Technology Assessment (Winchester, England)* 2006;10(43):iii-iv.
144. Ericson MB, Sandberg C, Gudmundson F, et al. Fluorescence contrast and threshold limit: implications for photodynamic diagnosis of basal cell carcinoma. *Journal of Photochemistry & Photobiology* 2003;B(2):121-127.

## Appendix A. Search Strategies

#	Search Terms
1	exp Skin Neoplasms/
2	exp "Neoplasms, Adnexal and Skin Appendage"/
3	exp Melanoma/
4	exp Carcinoma, Squamous Cell/
5	exp Carcinoma, Basal Cell/
6	exp Carcinoma, Merkel Cell/
7	exp Lymphoma, T-Cell, Cutaneous/
8	sarcoma, Kaposi/
9	exp Nevus, Pigmented/
10	(Basal adj2 carcinoma\$.tw.
11	(basal adj1 cancer\$.tw.
12	(basal adj1 neoplas\$.tw.
13	(basal adj1 tumo?r\$.tw.
14	(basal adj1 epithelioma\$.tw.
15	(basal adj1 malignan\$.tw.
16	basalioma\$.tw.
17	(basocellular\$ adj carcinoma\$.tw.
18	BCC.tw.
19	(basosquamous adj1 carcinoma\$.tw.
20	(squamous adj2 carcinoma\$.tw.
21	(squamous adj1 tumo?r\$.tw.
22	(squamous adj1 cancer\$.tw.
23	(squamous adj1 neoplas\$.tw.
24	(squamous adj1 epithelioma\$.tw.
25	(squamous adj1 malignan\$.tw.
26	SCC.tw.
27	(merkel adj2 carcinoma\$.tw.
28	(merkel adj1 cancer\$.tw.
29	(merkel adj1 tumo?r\$.tw.
30	(merkel adj1 neoplas\$.tw.
31	(merkel adj1 malignan\$.tw.
32	MCC.tw.
33	(t adj1 lymphoma\$.tw.
34	(cutaneous adj1 lymphoma\$.tw.
35	(mycos\$ adj fungoid\$.tw.
36	sezary\$.tw.
37	(kaposi\$ adj sarcoma\$.tw.
38	melanoma\$.tw.
39	(maligna\$ adj2 lentigo).tw.
40	LMM\$1.tw.
41	nonmelanoma\$.tw.
42	NMSC.tw.
43	dermatofibrosarcoma\$.tw.

44 (apocrine adj carcinoma\$.tw.  
45 (sweat adj1 carcinoma\$.tw.  
46 (sweat adj1 tumo?r\$.tw.  
47 (sweat adj1 neoplas\$.tw.  
48 (sweat adj1 cancer\$.tw.  
49 (sebaceous adj carcinoma\$.tw.  
50 (sebaceous adj tumo?r\$.tw.  
51 (sebaceous adj neoplas\$.tw.  
52 (sebaceous adj cancer\$.tw.  
53 (eccrine adj (poroma\$ or porocarcinoma\$)).tw.  
54 (eccrine adj epithelioma\$.tw.  
55 SSDC.tw.  
56 Basal Cell Nevus Syndrome/  
57 ((naevoid or nevoid) adj3 syndrome\$.tw.  
58 gorlin\$.tw.  
59 (malignant adj1 (nev\$ or naev\$)).tw.  
60 ((skin or derm\$ or cutaneous or epithelial or epidermoid\$) adj1  
61 (cancer\$ or neoplas\$ or carcinoma\$ or tumo?r\$ or malignan\$)).tw.  
62 or/1-60  
63 (dermoscopy or dermoscope\$1).mp. or exp Dermoscopy/  
64 full body photography.mp.  
65 exp Photography/ or digital photography.mp.  
66 \*photography/  
67 62 or 63 or 64 or 65 or 66  
68 tape stripping.mp.  
69 exp Fluorescence/ or fluorescence.mp.  
70 exp Ultrasonography/ or ultrasonography.mp.  
71 exp Laser-Doppler Flowmetry/ or laser Doppler.mp.  
72 exp Electric Impedance/ or electrical bio-impedance.mp.  
73 color mapping.mp.  
74 thermography.mp. or exp Thermography/  
75 skin surface microscopy.mp.  
76 skin surface microscopies.mp.  
77 dermatoscopy.mp.  
78 dermatoscopies.mp.  
79 microscopy, epiluminescence.mp.  
80 microscopies, skin surface.mp.  
81 epiluminescence microscopy.mp.  
82 microscopy, skin surface.mp.  
83 epiluminescence microscopies.mp.  
84 surface microscopy, skin.mp.  
85 microscopies, epiluminescence.mp.  
86 surface microscopies, skin.mp.  
87 color doppler.mp.  
88 incident light microscopy.mp.  
89 photodynamic diagnosis.mp.

- 90 fluorescence diagnosis.mp.
- 91 photodynamic detection.mp.
- 92 fluorescence-based photodynamic diagnostic product.mp.
- 93 fluorescent diagnostics.mp.
- 94 photodiagnosis.mp.
- 95 68 or 69 or 70 or 71 or 72 or 73 or 74 or 75 or 76 or 77 or 78 or 79 or 80 or 81 or 82  
or 83 or 84 or 85 or 86 or 87 or 88 or 89 or 90 or 91 or 92 or 93 or 94
- 96 67 or 95
- 97 61 and 96
- 98 limit 97 to (English language and humans and yr="1990 - Current")

## Appendix B. Inclusion and Exclusion Criteria

**Table B-1. Literature abstract screening (PICO) criteria**

	<b>Inclusion criteria</b>	<b>Exclusion criteria</b>
<b>Population (P)</b>	<ul style="list-style-type: none"> <li>- History of past or current skin cancer: melanoma, basal cell carcinoma, squamous cell carcinoma</li> <li>- Patients with new or recurrent pigmented or suspicious skin lesions, including facial skin cancers, basal cell nevus syndrome, and Gorlin's Syndrome</li> <li>- Included all age, race, sex, and countries</li> </ul>	<ul style="list-style-type: none"> <li>- All other skin cancers               <ul style="list-style-type: none"> <li>- Kaposi's sarcoma</li> <li>- Merkel cell carcinoma</li> <li>- Mycosis fungoides</li> <li>- Skin lymphoma</li> <li>- Sézary syndrome</li> <li>- Choroidal melanoma</li> </ul> </li> <li>- Subungual, ocular, and visceral lesions</li> <li>- Head and neck cancers</li> <li>- Metastases</li> </ul>
<b>Diagnostic device of interest (I)</b>	<ul style="list-style-type: none"> <li>- <b>General</b></li> <li>- Full body photography</li> <li>- Digital photography</li> <li>- Dermoscopy</li> <li>- <b>Limited Use</b></li> <li>- Confocal microscopy</li> <li>- Ultrasound, including laser Doppler, color mapping</li> <li>- Photodynamic diagnosis</li> <li>- <b>Investigational</b></li> <li>- Multiphoton laser scanning microscopy</li> <li>- Multispectral imaging with computer-analysis</li> <li>- Optical coherence tomography</li> <li>- Epidermal genetic tape stripping</li> <li>- Bio-electrical impedance</li> <li>- Thermography</li> </ul>	<ul style="list-style-type: none"> <li>- Spectrophotometric intracutaneous Analysis (SIAscopy)</li> <li>- Spectrophotometry</li> <li>- Photoacoustic microscopy</li> <li>- Photodynamic therapy (PDT)</li> <li>- Colorimetry</li> <li>- <sup>18</sup>F-FDG positron emission tomography (PET)</li> <li>- Computer tomography (CT)</li> <li>- Single photon emission computed tomography (SPECT)</li> <li>- Lymphoscintigraphy</li> <li>- Fluorescent in situ hybridization</li> <li>- Therapeutic interventions</li> <li>- Pre-surgical planning</li> </ul>
<b>Comparator (C)</b>	<ul style="list-style-type: none"> <li>- Biopsy</li> <li>- Any intervention and device listed above</li> <li>- Clinical exam/assessment</li> </ul>	
<b>Outcomes (O)</b>	<ul style="list-style-type: none"> <li>- Any clinical outcomes reported (including skin cancer survival and overall survival)</li> <li>- Quality of life measures</li> <li>- Intermediate outcomes, e.g., changes in size and number of lesions</li> <li>- Lesion characterizations</li> <li>- Adverse events, harms, or safety data</li> <li>- FDA clearance/approval status (if applicable)</li> <li>- Process measures, e.g., time to specialty referral, hospital wait times, healthcare utilization</li> <li>- Diagnostic test accuracy, e.g., sensitivity, specificity, positive predictive value, negative predictive value</li> </ul>	<ul style="list-style-type: none"> <li>- Metastases detection</li> <li>- Prognosis prediction</li> </ul>
<b>Study design</b>	<ul style="list-style-type: none"> <li>- Systematic reviews</li> <li>- Narrative reviews</li> <li>- Trials</li> <li>- Comparative cohorts</li> <li>- Case series</li> <li>- Case reports</li> <li>- Diagnostic tests</li> </ul>	

# Appendix C. FDA Clearance and Clinical Trials Status

**Table C-1. Available U.S. FDA clearance status for noninvasive skin cancer diagnostic devices**

Device name	Company (country) Web site	FDA clearance status	Intended use
<b>DERMOSCOPY</b>			
EpiScope (MODEL 47300)	Welch Allyn (USA) www.welchallyn.com	<ul style="list-style-type: none"> <li>• Approved by the FDA Class I device</li> <li>• 510(K920103)</li> <li>• FDA decision date: 04/28/1992</li> </ul>	To illuminate body surfaces and cavities
Nevoscope	TransLite (USA) www.tlite.com	<ul style="list-style-type: none"> <li>• Approved by the FDA as Class I device</li> <li>• 510(K954943)</li> <li>• FDA decision date: 03/27/1996</li> </ul>	To view skin lesions by either surface illumination or transillumination
Dermascope	American Diagnostic Corp. (USA) www.adctoday.com	<ul style="list-style-type: none"> <li>• Approved by the FDA as Class I device in 1999</li> </ul>	To enlarge images for medical purposes
MoleMax	Derma Medical Systems www.dermamedicalsystems.com	<ul style="list-style-type: none"> <li>• Approved by the FDA as Class I device in 1999</li> </ul>	To enlarge images for medical purposes
MicroDerm	Visiomed AG (USA) www.visiomedag.com	<ul style="list-style-type: none"> <li>• Approved by the FDA as Class II device</li> <li>• 510(K032760)</li> <li>• FDA decision date: 04/27/2004</li> </ul>	To acquire and store images of skin surfaces
<b>CONFOCAL MICROSCOPY</b>			
VivaScope® 1500 VivaScope® 2500 VivaScope® 3000	Lucid, Inc. (USA) www.lucid-tech.com	<ul style="list-style-type: none"> <li>• Approved by the FDA as Class II device</li> <li>• 510(k) number: K080788</li> <li>• FDA decision date: 09/05/2008</li> </ul>	To acquire, store, retrieve, display, and transfer in vivo images of tissue
Optiscan™	Optiscan Pty Ltd (Australia) www.optiscan.com	<ul style="list-style-type: none"> <li>• Approved by the FDA as Class II device</li> <li>• 510(k) number: K093624</li> <li>• FDA decision date: 02/19/2010</li> </ul>	This device was listed as a confocal microscopy device for skin lesion evaluation in a published review. <sup>37</sup> However, the intended use listed in the FDA summary is for the imaging of the internal microstructure of tissues during endoscopic medical procedures.

**Table C-1. Available U.S. FDA clearance status for noninvasive skin cancer diagnostic devices (continued)**

<b>Device name</b>	<b>Company (country) Web site</b>	<b>FDA clearance status</b>	<b>Intended use</b>
<b>ULTRASOUND/LASER DOPPLER</b>			
Cortex Dermascan C Ultrasonic System	Cortex Technology APS (Denmark) www.cortex.dk/	<ul style="list-style-type: none"> <li>• Approved by the FDA</li> <li>• 510(K983945)</li> <li>• FDA decision date: 03/17/1999</li> </ul>	To visualize layers of the skin, including blood vessels
DUB 20	G.W.B. INTL., LTD. (USA)	<ul style="list-style-type: none"> <li>• Approved by the FDA as Class II device</li> <li>• 510(K896029)</li> <li>• FDA decision date: 01/12/1990</li> </ul>	No data available
SSA-340 A (Modification)	Toshiba America Medical System, Inc. (USA) www.medical.toshiba.com	<ul style="list-style-type: none"> <li>• Approved by the FDA as Class II device</li> <li>• 510(K960602)</li> <li>• FDA decision date: 03/21/1996</li> </ul>	To accentuate minute vascular structures and signal presence of blood
Sonoline Elegra Diagnostic Ultrasound System	Siemens Medical Solutions USA, Inc.(USA)	<ul style="list-style-type: none"> <li>• Approved by the FDA as a Class II device</li> <li>• 510(K003125)</li> <li>• FDA decision date: 10/20/2000</li> </ul>	For peripheral vascular applications, not specified
<b>MULTISPECTRAL IMAGING AND FULLY AUTOMATED COMPUTER-BASED ANALYSIS</b>			
MelaFind	Electro-Optical Sciences, Inc. (USA) www.eosciences.com	<ul style="list-style-type: none"> <li>• Unproven procedure</li> <li>• Filed a pre-market approval application in June 2009</li> <li>• FDA advisory panel meeting (Nov. 18, 2010): voted 8-7, a recommendation for approval of MelaFind as a skin cancer detection device</li> </ul>	

**Table C-2. Studies of noninvasive diagnostic techniques for the detection of skin cancer on the clinicaltrials.gov registry**

<b>NCT number</b>	<b>Study design</b>	<b>Type of technology</b>	<b>Study status</b>	<b>Last updated</b>	<b>Results</b>
<b>PHOTOGRAPHY</b>					
No registered study was identified for this modality.					
<b>DERMOSCOPY</b>					
00765193	Cohort	Dermoscopy (as needed)	Completed	April 4, 2010	Posted
<b>CONFOCAL MICROSCOPY</b>					
00601185	Non-randomized diagnostic study	Reflectance confocal microscopy	Completed	January 27, 2010	Not posted
00785369	Non-randomized diagnostic study	Reflectance confocal microscopy	Completed	Feb 3, 2010	Not posted
00487864	Observational non-comparative cohort	Confocal scanning laser microscopy	Completed	June 18, 2007	Not posted
01010321	Observational case-series	Confocal microscopy	Suspended	June 27, 2010	NA
00771355	Observational case-series	Reflectance confocal microscopy	Recruiting participants; estimated completion date is July 2010	May 3, 2010	NA
00588315	Case-control	Confocal microscopy	Recruiting participants; estimated completion date is December 2010	June 22, 2010	NA
00574392	Observational non-comparative cohort	Reflectance confocal microscopy	Ongoing but not recruiting participants; estimated completion date is November 2011	October 8, 2010	NA
01194947	Case-series	Reflectance confocal microscopy	Not yet open for recruitment; estimated completion date is September 2013	September 22, 2010	NA
00663910	Non-randomized pilot study	Reflectance confocal microscopy*	Not yet open for recruitment; estimated completion date is March 2010	December 1, 2009	NA
<b>ULTRASOUND WITH LASER DOPPLER</b>					
00776945	Observational	Ultrasound with laser Doppler	Ongoing. Estimated primary completion date is December 2014	November 12, 2009	NA
<b>PHOTODYNAMIC DIAGNOSIS</b>					
No registered study was identified for this modality (except as noted above*)					
<b>MULTIPHOTON LASER SCANNING MICROSCOPY</b>					
00154921	Cross-sectional	Two-photon fluorescence microscopy	Recruiting participants; estimated study completion date is December 2007	November 22, 2005	NA
00508781	Cross-sectional	Multiphoton laser scanning microscopy	Recruiting participants; estimated study completion date is December 2012	July 26, 2007	NA
<b>ELECTRICAL BIO-IMPEDENCE</b>					
00966173	Observational non-comparative cohort	Electrical impedance spectrometer	Completed	August 10, 2010	Not posted
01077050	Observational non-comparative cohort	Electrical impedance spectrometer	Recruiting participants; estimated study completion date is April 2010	May 19, 2010	NA



**Table C-2. Studies of noninvasive diagnostic techniques for the detection of skin cancer on the clinicaltrials.gov registry (continued)**

<b>NCT number</b>	<b>Study design</b>	<b>Type of technology</b>	<b>Study status</b>	<b>Last updated</b>	<b>Results</b>
<b>MULTISPECTRAL IMAGING AND FULLY AUTOMATED COMPUTER-BASED ANALYSIS</b>					
00434057	Non-randomized diagnostic study	MelaFind	Completed	November 10, 2009	Posted
01011153	Observational Cross-sectional	MelaFind	Estimated primary completion date is December 2009	November 10, 2009	Not posted
<b>OPTICAL COHERENCE TOMOGRAPHY</b>					
00390351	Cross-sectional	Optical coherence tomography	Recruiting participants; estimated completion date is July 2008	October 18, 2006	NA
<b>TAPE STRIPPING</b>					
00482105	Observational non-comparative cohort	EGIR™ tape stripping	Terminated	May 7, 2009	Not posted
<b>THERMOGRAPHY</b>					
No registered study was identified for this modality					

**Source:** <http://www.clinicaltrials.gov>

\* This study evaluates the effect of topical application of 5-aminolevulinic acid photodynamic therapy on protoporphyrin formation among non-melanoma skin cancer patients. The primary purpose of this study was not to evaluate confocal microscopy per se, but confocal microscopy was used as part of the study outcome assessment.

## Appendix D. Evidence Maps and Outcome Measures

**Table D-1. Evidence map of published abstracts for noninvasive diagnostic devices by clinical use status (N=583<sup>a</sup>)**

Noninvasive technologies	Reviews (N=232)			Primary Studies (N=351)				
	Narrative reviews	Technical reports	Systematic reviews	RCT	Comparative cohorts	Non-comparative cohorts	Diagnostic tests	Single case reports
<b>Modalities in general clinical use</b>								
Photography	4	4	--	7 <sup>b</sup>	11	13	5	-
Dermoscopy	78	71	5	3	39	96	52	49
<i>Subtotal</i>	<i>81</i>	<i>74</i>	<i>5</i>	<i>10</i>	<i>50</i>	<i>109</i>	<i>57</i>	<i>49</i>
<b>Modalities in limited clinical use</b>								
Confocal microscopy	17	12	--	--	6	26	7	4
Ultrasound/Laser Doppler	6	12	--	--	2	7	7	--
Photodynamic diagnosis	9	7	--	1	4	--	--	1
<i>Subtotal</i>	<i>32</i>	<i>31</i>	<i>0</i>	<i>1</i>	<i>12</i>	<i>33</i>	<i>14</i>	<i>5</i>
<b>Investigational</b>								
Multiphoton laser scanning microscopy	3	--	--	--	--	--	2	--
Multispectral imaging and fully automated computer-based analysis	1 <sup>c</sup>	--	--	--	--	--	1	--
Electrical bio-impedance	--	--	--	--	1	2	2	--
Optical coherence tomography	1	2	--	--	1	1	--	--
Tape stripping	--	--	--	--	--	--	1	--
Thermography	1	--	--	--	--	--	--	--
<i>Subtotal</i>	<i>6</i>	<i>2</i>	<i>0</i>	<i>0</i>	<i>2</i>	<i>3</i>	<i>6</i>	<i>0</i>
<b>Total</b>	<b>119</b>	<b>108</b>	<b>5</b>	<b>11</b>	<b>64</b>	<b>144</b>	<b>77</b>	<b>55</b>

<sup>a</sup> Subset of 629 abstracts designated as either a review article or primary study focusing on a single diagnostic modality, some review articles have been counted in more than one category, therefore, the individual numbers may not sum up to the subtotal.

<sup>b</sup> 6 unique RCTs produced 7 individual abstracts.

<sup>c</sup> Review also covered other topics (e.g., dermoscopy).

**Table D-2. Evidence map of published abstracts for noninvasive diagnostic devices by skin cancer type**

Noninvasive technologies	Melanoma	Basal cell carcinoma	Squamous cell carcinoma	Other <sup>a</sup>
<b>Modalities in clinical use</b>				
Photography	28	1	-	22
Dermoscopy	236	22	5	58
<b>Modalities in limited clinical use</b>				
Confocal microscopy	29	13	2	28
Ultrasound	9	3	-	19
Photodynamic diagnosis	2	16	-	4
<b>Investigational</b>				
Multiphoton laser scanning microscopy	-	-	-	5
Multispectral imaging and fully automated computer-based analysis	1	-	-	-
Electrical bio-impedance	-	3	-	2
Optical coherence tomography	1	1	-	3
Tape stripping	1	-	-	-
Thermography	1	-	-	-
<b>Total</b>	<b>308</b>	<b>59</b>	<b>7</b>	<b>141</b>

<sup>a</sup> Includes “malignancies of the skin, not otherwise specified” and “skin cancer combinations.”

**Table D-3. RCTs identified in the present technical brief**

First Author UI Country year	Study Objective	Comparisons	Setting	Population (N) Mean age, yrs Males (%) Race Cancer type	Type of Outcome, Followup duration	Outcome, Adverse events
<b>Photography</b>						
Del Mar CB <sup>138</sup> 788887 Australia 1995	To evaluate excision rate of benign melanocytic nevi	General practitioners (GPs) with a camera vs. GPs with no camera	Primary care	108 GPs (5784 pts with suspicious nevus) 28.2 years (pt level) 43.4% male (pt level) No data on race (study conducted in Australia) Melanoma	Intermediate outcomes Followup = 2 years	Outcomes: Excision rates of benign melanocytic nevi  No adverse events reported
Hanrahan PF <sup>139,140</sup> 11215011 12370325 Australia 2000;2002	To assess the utility of photographs for skin cancer management	Patient received photographs vs. patients with no photographs	Primary care	973 male > 50 years agreed to participate 62.0 years 100.0% male No data on race (study conducted in New South Wales) Melanoma	Test accuracy Intermediate outcomes Followup = 2 years	Outcomes: Diagnostic accuracy between those using and not using photography Effect of photography on management of lesion (leave lesion for followup, cryotherapy) Cost savings of photography  No adverse events reported
English DR <sup>141</sup> 12919990 Australia 2003	To evaluate the ratio of benign to malignant excision	GPs with a camera and algorithm vs. GPs with no camera	Primary care setting	468 GPs( 223 practices) No data on age No data on race Melanoma	Intermediate outcomes Followup duration unclear	Outcome: Ratio of benign to malignant melanoma excised.  No adverse events reported

**Table D-3. RCTs identified in the present technical brief (continued)**

<b>First Author UI Country year</b>	<b>Study Objective</b>	<b>Comparisons</b>	<b>Setting</b>	<b>Population (N) Mean age, yrs Males (%) Race Cancer type</b>	<b>Type of Outcome, Followup duration</b>	<b>Outcome, Adverse events</b>
Oliveria SA <sup>142</sup> 14751328 USA 2004	To assess the impact of nurse-delivered intervention with digital photographs to increase patient adherence to skin self examination	Teaching intervention with photo-book vs. teaching intervention alone	Primary care setting	100 high-risk patients Control age:38 years Control male%:33.3 Dysplastic/atypical nevi	Intermediate outcomes Followup = 4 months	Outcomes: Adherence to skin self examination. No adverse events reported.
Chiu V <sup>28</sup> 16844506 USA 2006	To examine the accuracy of skin self examination	Mole mapping vs. no mole mapping.	Primary care setting	88 patients Control age:>50 yrs, 57% males in mole mapping group Control males: 52% Suspicious skin lesions	Intermediate outcomes Followup = 2 weeks	Outcome: Percentage of patients that gave accurate assessment of lesions
Bowns IR <sup>143</sup> 17049140 2006 UK	To compare tele-dermatology with face to face consultation	Tele-consultation vs. face to face consultation evaluating diagnostic concordance between physicians	Specialist setting (dermatology)	208 patients 46.3 years 37.4% male No data on race Any malignancy	Test accuracy Process outcomes Followup duration: NA	Outcomes: Diagnostic concordance between physicians—Sn,Sp Number of followup visits Patients' satisfaction with care Adverse events: not reported
<b>Dermoscopy</b>						
Carli P <sup>56</sup> 15097950 Italy 2004	To assess the impact of dermoscopy on lesion management	Naked eye and dermoscopy vs. naked eye alone	Pigmented lesion clinic (dermatology)	913 patients 36 years 43% male No data on race Melanoma	Intermediate outcomes Followup = 6 months	Outcomes: Percentage of patients referred for surgery Number of melanoma excised Adverse events: not reported
Argenziano G <sup>55</sup> 16622262 Barcelona, Spain, Naples, Italy 2006	To evaluate the effect of dermoscopy on the diagnostic accuracy of primary care practitioners	Dermoscopy evaluation vs. naked eye evaluation	Primary care setting	73 PCPs 2522 patients 40.5 years 38% male No data on race Any malignancy	Test accuracy Followup = 16 months	Outcomes: Sn,Sp,NPV,PPV  Adverse events: not reported

**Table D-3. RCTs identified in the present technical brief (continued)**

First Author UI Country year	Study Objective	Comparisons	Setting	Population (N) Mean age, yrs Males (%) Race Cancer type	Type of Outcome, Followup duration	Outcome, Adverse events
Zalaudek I <sup>59</sup> 18427045 2008 Austria	To determine the time required to complete skin examination with or without dermoscopy	Skin exam and dermoscopy vs. skin exam alone	Pigmented lesion clinic (dermatology)	1359 patients 39.5 years 45.9% male No data on race Any malignancy	Process outcomes Followup duration: NA	Outcome: Median time required for complete skin examination Adverse events: not reported
<b>Photodynamic diagnosis</b>						
Ericson MB <sup>144</sup> 12633984 2003 Sweden	To evaluate tolerance threshold of photo-diagnosis by evaluating ratio of fluorescence intensity between ALA treated tumor tissue and normal skin	4 groups with varying ALA application time, from 1 to 4 hrs	dermatologist	40 patients Age: nd No data on % male No data on race Basal cell carcinoma	Other outcomes Followup duration: NA	Outcomes: Ratio of fluorescence intensity between ALA treated tumor tissue and normal skin Fluorescence intensity variation in ALA-treated normal skin Adverse events: not reported

ALA = 5-aminolevulinic acid, GPs = general practitioners, nd = no data, NPV = negative predictive value, PCPs = primary care physicians, PPV = positive predictive value;  
Sn = sensitivity; Sp = specificity.

**Table D-4. Outcome measures reported in the published primary studies for noninvasive diagnostic devices^**

<b>Noninvasive technologies</b>	<b>Test accuracy</b>	<b>Clinical outcomes</b>	<b>Lesion characterization</b>	<b>Other</b>
<b>Modalities in clinical use</b>				
Photography	9	0	10	18
Dermoscopy	92	1	83	63
<b>Modalities in limited clinical use</b>				
Confocal microscopy	15	0	24	3
Ultrasound / Laser Doppler	5	0	8	3
Photodynamic diagnosis	3	0	2	1
<b>Investigational</b>				
Multiphoton laser scanning microscopy	2	0	0	0
Multispectral imaging and fully automated computer-based analysis	1	0	0	0
Electrical bio-impedance	2	0	0	3
Optical coherence tomography	1	0	2	0
Tape stripping	2	0	0	0

^Thermography is not included in this table as no primary studies on thermography were identified.

## Appendix E. Abbreviations

ABCD	Asymmetry, border, color, and differential structure
ALA	Aminolevulinic acid
BCC	Basal cell carcinoma
CDRH	Center for Devices and Radiological Health
CSLM	Confocal scanning laser microscopy
CT	Computed tomography
EGIR	Epidermal Genetic Information Retrieval
FDA	Food and Drug Administration
GP	General practitioner
MAUDE	Manufacturer and User Facility Device Experience
MeSH	Medical Subject Headings
MRI	Magnetic resonance imaging
NCT	National Clinical Trial
NMSC	Non-melanoma skin cancer
OCT	Optical Coherence Tomography
PDD	Photodynamic diagnosis
PET	Positron emission tomography
PICO	Population, intervention, comparison, and outcome
PpIX	Protoporphyrin IX
SCC	Squamous cell carcinoma
SPECT	Single photon emission computed tomography
TBP	Total body photography