



Clofazimine

Updated: October 13, 2017.

OVERVIEW

Introduction

Clofazimine is a fat soluble, brick red dye that is used in combination with other agents in the therapy of leprosy. Clofazimine, by itself, has not been associated with serum aminotransferase elevations during therapy or to instances of clinically apparent acute liver injury.

Background

Clofazimine (kloe faz' i meen) is a fat soluble iminophenazine, brick red dye that has in vitro activity against several species of mycobacteria and was found to be very effective in the treatment of leprosy (Hansen disease). Clofazimine binds to mycobacterial DNA and was developed as a potential therapy of mycobacterium tuberculosis, but showed minimal activity. In contrast, it was found to be a valuable agent in treating leprosy; clinical trials demonstrating benefit both as monotherapy and when combined with dapsone and rifampin. Multidrug therapy using all three agents is now considered the first line of therapy for adults with leprosy and provides a high rate of ultimate cure after 1 to 3 years of therapy. Clofazimine was approved for use in the United States in 1986, but was withdrawn in 2016 and is now only available under the auspices of the National Hansen's Disease (Leprosy) Program (<https://www.hrsa.gov/hansens-disease/index.html>). In other countries, clofazimine is available under the commercial name Lamprene in tablets of 50 mg, the recommended dose being 100 mg daily. Clofazimine also has immunosuppressive activity and it has been used experimentally to treat discoid lupus erythematosus and psoriasis. More recently, it has shown some activity in treating infectious with drug resistant non-tuberculosis Mycobacterium species including Mycobacterium avian complex and abscessus. The major side effects of clofazimine include skin discoloration and gastrointestinal upset with pain, nausea and diarrhea. The skin discoloration is due to the reddish-orange color of clofazimine and results in a pinkish-brown discoloration of skin and bodily fluids in the majority of patients treated for more than a month. The discoloration fades with stopping the drug, but may persist for months or years. The gastrointestinal side effects of clofazimine can be severe and require dose modification or discontinuation. The symptoms appear to be due to crystallization of the clofazimine molecule in intestinal submucosa; these crystals can also be found in liver, lymph nodes and spleen. While clofazimine is rarely used in the United States, it is an important medication from a worldwide perspective and has played an essential role in public health efforts to eradicate leprosy.

Hepatotoxicity

Therapy with clofazimine has not been associated with elevations in serum enzymes during treatment and has not been linked to cases of clinically apparent liver injury. The multidrug therapy combination of clofazimine, rifampin and dapsone, however, is associated with instances of jaundice and hepatitis, which are most likely

attributable to dapsone ("dapsone syndrome") and marked by fever, rash, eosinophilia and hepatic involvement (DRESS syndrome) typically arising within 8 weeks of starting the drug regimen. Dapsone induced liver injury can be severe and the mortality rate in cases with jaundice is as high as 25% to 33%. The liver injury usually resolves with stopping therapy and most patients have later tolerated restarting of clofazimine and rifampin. Thus, clinically apparent liver injury from clofazimine must be very rare, if it occurs at all.

Likelihood score: E (unlikely cause of clinically apparent liver injury).

Mechanism of Injury

The possible causes of liver injury from clofazimine therapy are not known and might relate to formation of drug-crystals in macrophages in the liver. While crystals of clofazimine can be found in liver and spleen in patients on prolonged therapy, they do not appear to be associated with appreciable liver damage. The hepatic metabolism of clofazimine is not well defined.

Outcome and Management

The serum aminotransferase and alkaline phosphatase elevations that occur during clofazimine therapy are self-limited and are generally due to other drugs that are used in combination with clofazimine. These abnormalities often resolve even with continuation of clofazimine therapy. Appearance of frank jaundice and hepatitis during multidrug therapy of leprosy should lead to temporary discontinuation of all three medications, but then with careful restarting of clofazimine once the liver injury has resolved.

Drug Class: [Antiinfective Agents](#), [Leprosy Agents](#)

Other Drugs in the Subclass, Leprosy Agents: [Dapsone](#) , [Rifampin](#)

PRODUCT INFORMATION

REPRESENTATIVE TRADE NAMES

Clofazimine – Lamprene®

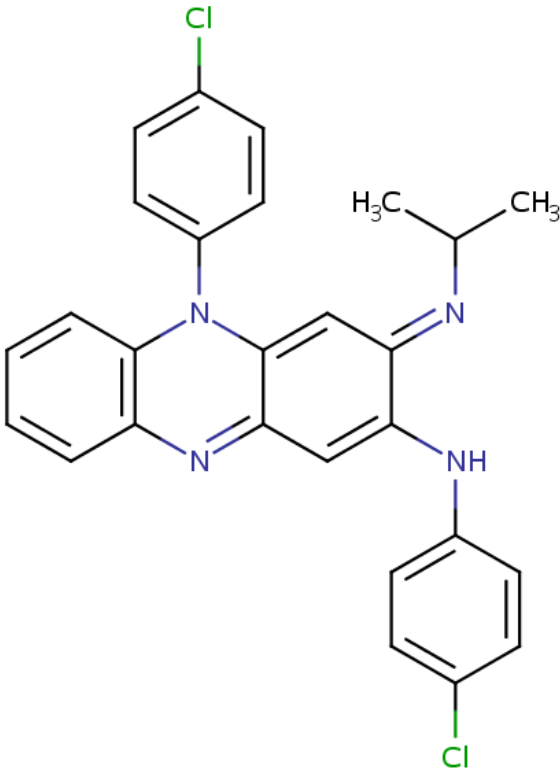
DRUG CLASS

[Antiinfective Agents](#)

[COMPLETE LABELING](#)

Product labeling at DailyMed, National Library of Medicine, NIH

CHEMICAL FORMULA AND STRUCTURE

DRUG	CAS REGISTRY NO	MOLECULAR FORMULA	STRUCTURE
Clofazimine	2030-63-9	C ₂₇ H ₂₂ Cl ₂ N ₄	 <p>The chemical structure of Clofazimine is a complex heterocyclic molecule. It features a central benzimidazole ring system. One nitrogen atom of the benzimidazole is substituted with a 4-chlorophenyl group. The other nitrogen atom is substituted with an isopropyl group. The benzimidazole ring is further substituted at the 2-position with a 4-chlorophenylamino group (-NH-C₆H₄-Cl).</p>

ANNOTATED BIBLIOGRAPHY

References updated: 13 October 2017

Zimmerman HJ. Hepatic injury from the treatment of infectious and parasitic diseases. In, Zimmerman HJ. Hepatotoxicity: the adverse effects of drugs and other chemicals on the liver. 2nd ed. Philadelphia: Lippincott, 1999. pp 589-637.

(Expert review of hepatotoxicity published in 1999, clofazimine is not discussed).

Moseley RH. Antibacterial and Antifungal Agents. In, Kaplowitz N, DeLeve LD, eds. Drug-induced liver disease. 3rd Edition. Amsterdam: Elsevier, 2013. p. 463-81.

(Review of hepatotoxicity of antibiotics; clofazimine is not discussed).

Gumbo T. Clofazimine. Chemotherapy of tuberculosis, Mycobacterium Avium Complex Disease, and Leprosy. In, Brunton LL, Chabner BA, Knollman BC, eds. Goodman & Gilman's the pharmacological basis of therapeutics. 12th ed. New York: McGraw-Hill, 2011, pp. 1560.

(Textbook of pharmacology and therapeutics).

Browne SG, Hogerzeil LM. "B 663" in the treatment of leprosy. Preliminary report of a pilot trial. Lepr Rev 1962 Jan; 33: 6-10. PubMed PMID: 13873759.

- (Description of the initial trials of clofazimine in humans with leprosy: 16 patients with lepromatous leprosy were treated with clofazimine [100 to 300 mg daily], some in combination with dapsone, and all 16 improved clinically with no signs of toxicity except for discoloration of the skin and nausea and dizziness in some patients receiving the highest doses).*
- Browne SG. Treatment of leprosy with B 633: appraisal of the pilot trial after three years. *Lepr Rev* 1965 Jan; 36: 13-5. PubMed PMID: 14241912.
- (Among 28 patients with leprosy in Nigeria treated with clofazimine for up to 3 years, all improved clinically and adverse events were ruddy skin and black discoloration without symptoms or itching, resolving upon stopping).*
- Clofazimine (Lamprene) in leprosy. *Drug Ther Bull* 1970; 8: 7-8. PubMed PMID: 4903794.
- (Concise description of clofazimine [a fat soluble, orange dye with both antimycobacterial and antiinflammatory properties], its pharmacology, clinical efficacy in leprosy and safety; no mention of hepatotoxicity).*
- Karat AB, Jeevaratnam A, Karat S, Rao PS. Double-blind controlled clinical trial of clofazimine in reactive phases of lepromatous leprosy. *Br Med J* 1970; 1(5690): 198-200. PubMed PMID: 4904935.
- (Among 24 Indian patients with lepromatous leprosy who were treated for 12 weeks with clofazimine [100 mg three times daily] vs prednisolone, 11 of 12 clofazimine- but only 3 of 12 prednisolone-treated subjects had a clinical response; side effects included red and black pigmentation, but no mention of hepatotoxicity or ALT elevations).*
- Helmy HS, Pearson JM, Waters MF. Treatment of moderately severe erythema nodosum leprosum with clofazimine--a controlled trial. *Lepr Rev*; 42: 167-77. PubMed PMID: 4339652.
- (Among 10 patients with leprosy in Malaysia who developed erythema nodosum leprosum while on dapsone, a 4 week course of clofazimine [300 mg daily] was superior to placebo in inducing clinical improvement; side effects included skin discoloration in most and gastrointestinal intolerance in 30%).*
- Schulz EJ. Forty-four months' experience in the treatment of leprosy with clofazimine (Lamprene (Geigy)). *Lepr Rev* 1971; 42: 178-87. PubMed PMID: 5151819.
- (Among 123 patients with leprosy in South Africa treated with clofazimine with or without dapsone, bacterial clearance and clinical response rates were similar, but erythema nodosum reactions were less with clofazimine; side effects included skin discoloration, pruritus and ichthyosis but liver tests did not change on treatment).*
- Karat AB, Jeevaratnam A, Karat S, Rao PS. Controlled clinical trial of clofazimine in untreated lepromatous leprosy. *Br Med J* 1971; 4 (5786): 514-6. PubMed PMID: 4942741.
- (Among 23 patients with lepromatous leprosy treated with clofazimine [100 mg daily] or dapsone [100 mg daily] for at least 6 months, response rates were similar and serum ALT levels did not change).*
- Browne SG. Clofazimine in leprosy. *Br Med J* 1972; 1 (5798): 506-7. PubMed PMID: 4550304.
- (Letter in response to Karat [1971] commenting that clinical responses cannot be fully assessed with only 6 months of therapy with clofazimine in this small number of patients).*
- Mackey JP, Barnes J. Clofazimine in the treatment of discoid lupus erythematosus. *Br J Dermatol* 1974; 91: 93-6. PubMed PMID: 4851057.
- (Among 26 patients with discoid lupus erythematosus treated with clofazimine, 17 [65%] had a beneficial response and side effects were largely skin pigmentation which faded slowly upon stopping).*
- Tolentino JG, Rodriquez JN, Abalos RM. Controlled long-term therapy of leprosy with B663 (lamprene, clofazimine) compared with DDS. *Int J Lepr Other Mycobact Dis* 1974; 42: 416-418. PubMed PMID: 4617720.
- (Among 43 patients with active leprosy treated with either dapsone or clofazimine, 16 completed 4 years of therapy and all improved clinically regardless of agent used and "no toxic reactions worth mentioning were observed").*

Ahrens TF, Pettit JH, Ridley DS, Glaus L. Multicentre controlled comparative trial of clofazimine and dapsone in low dosages. *Lepr Rev* 1975; 46: 287-96. PubMed PMID: 1107728.

(Among 94 patients with leprosy treated with low doses of either clofazimine [100 mg] or dapsone [50 mg] twice weekly, response rates were similar and erythema nodosum reactions were less with clofazimine [8 vs 24 events]).

Pattyn SR, Rollier MT, Rollier R, Saerens EJ, Dockx P. A controlled clinical trial of continuous and intermittent rifampicin therapy during an initial three months period in lepromatous leprosy: final analysis. *Lepr Rev* 1975; 46 (2 Suppl): 129-39. PubMed PMID: 1100953.

(Among 93 patients with leprosy treated with rifampin [daily or weekly], dapsone and clofazimine, bacterial clearance was fastest with rifampin; jaundice occurred in 1 patient on dapsone).

Plock H, Leiker DL. A long term trial with clofazimine in reactive lepromatous leprosy. *Lepr Rev* 1976; 47: 25-34. PubMed PMID: 1263732.

(Among 17 Tanzanian patients on long term clofazimine [200 to 400 mg daily] for leprosy, 7 discontinued therapy early because of gastrointestinal intolerance).

Jopling WH. Complications of treatment with clofazimine (Lamprene: B663). *Lepr Rev* 1976; 47: 1-3. PubMed PMID: 1263731.

(Editorial on side effects of long term clofazimine therapy focusing upon gastrointestinal discomfort that typically arises several weeks to months after starting and is slow to resolve even upon stopping, associated with reddish-brown discoloration of viscera and crystals of clofazimine in laminal propria of intestines and local lymph nodes).

Ramu G, Iyer GG. Side effects of clofazimine therapy. *Lepr India* 1976; 48 (4 Suppl): 722-31. PubMed PMID: 1026810.

(Among 84 patients with leprosy treated with clofazimine, all developed red or dark skin pigmentation usually within 10 weeks of starting, ichthyosis in 67%, abdominal pain, nausea and diarrhea in 11%, the pain occasionally acute and severe).

Hastings RC, Jacobson RR, Trautman JR. Long-term clinical toxicity studies with clofazimine (B663) in leprosy. *Int J Lepr Other Mycobact Dis* 1976; 44: 287-93. PubMed PMID: 824210.

(Among 51 patients with leprosy treated with clofazimine for 2-8 years, mild AST elevations occur in 20% of patients, bilirubin levels did not change, and there were no clinically significant toxic effects).

Feldman RA, Sturdivant M. Leprosy in the United States, 1950-1969: an epidemiologic review. *South Med J* 1976; 69: 970-9. PubMed PMID: 959886.

(Over a 20 year period, 1826 cases of leprosy were diagnosed in the US and Puerto Rico, 43% acquired abroad, and most cases reported from Texas, Hawaii and Louisiana).

Jacobson RR, Trautman JR. The diagnosis and treatment of leprosy. *South Med J* 1976; 69: 979-85. PubMed PMID: 959887.

(Overview of the clinical spectrum, diagnosis and therapy of leprosy from the US Public Health Service hospital in Carville, Louisiana discusses use of clofazimine which was an experimental medication at the time and only available from Carville).

Golden GS, McCormick JB, Fraser DW. Leprosy in the United States, 1971-1973. *J Infect Dis* 1977; 135: 120-5. PubMed PMID: 833445.

(Report from the CDC of 419 cases of leprosy diagnosed over a 3 year period in the US, most indigenous cases from California, Texas and Hawaii; 62% lepromatous or dimorphous vs 36% tuberculoid or indeterminate).

Bryceson A. Unnecessary laparotomy for abdominal pain and fever due to clofazimine. *Lepr Rev* 1979; 50: 258-9. PubMed PMID: 522604.

(24 year old man with leprosy treated for 2-3 months with clofazimine [500 mg daily] for corticosteroid resistant erythema nodosum leprosum had severe bouts of abdominal pain that eventually led to laparotomy which showed no abnormalities except for red intraperitoneal fat and black lymph nodes with crystals of clofazimine, the abdominal pains resolving upon stopping drug).

Thomsen K, Rothenborg HW. Clofazimine in the treatment of pyoderma gangrenosum. *Arch Dermatol* 1979; 115: 851-2. PubMed PMID: 453894.

(Among 10 patients with pyoderma gangrenosum treated with clofazimine for 0.5 to 5 months, healing occurred in all patients and tests "of liver and kidney function disclosed no abnormality").

Browne SG, Harman DJ, Waudby H, McDougall AC. Clofazimine (Lamprene, B663) in the treatment of lepromatous leprosy in the United Kingdom. A 12 year review of 31 cases, 1966-1978. *Int J Lepr Other Mycobact Dis* 1981; 49: 167-76. PubMed PMID: 7196886.

(Among 31 patients with leprosy treated in the UK with clofazimine monotherapy for 1-12 years, all had a clinical response and none stopped therapy because of adverse events; 5 patients died, all of unrelated causes).

Moore VJ. A review of side-effects experienced by patients taking clofazimine. *Lepr Rev* 1983; 54: 327-35. PubMed PMID: 6668986.

(Among 65 patients with leprosy treated with clofazimine, 64% developed skin discoloration and 33% had gastrointestinal complaints, but none required stopping).

Bulakh PM, Kowale CN, Ranade SM, Burte NP, Chandorkar AG. The effect of clofazimine on liver function tests in lepra reaction (ENL). *Lepr India* 1983; 55: 714-8. PubMed PMID: 6668931.

(Among 20 patients who developed erythema nodosum reactions while on dapsone for lepromatous leprosy, serum aminotransferase levels were often slightly elevated and levels decreased during clofazimine therapy).

Pattyn SR, Janssens L, Bourland J, Saylan T, Davies EM, Grillone S, Feracci C. Hepatotoxicity of the combination of rifampin-ethionamide in the treatment of multibacillary leprosy. *Int J Lepr Other Mycobact Dis* 1984; 52: 1-6. PubMed PMID: 6368424.

(Among 596 patients with leprosy in the Middle East and Africa treated with regimens using rifampin, prothionamide [or ethionamide] and dapsone [or clofazimine], 81 developed hepatitis within 8 to 186 days which the authors attributed to the combination of rifampin and ethionamide; 1 of 5 patients had recurrence upon rechallenge with the combination).

Chandorkar AG, Burte NP, Gade RK, Bulakh PM. Once monthly rifampicin (1200 mg) plus daily dapsone (100 mg) and clofazimine (100 mg) in the initial treatment of lepromatous leprosy. *Indian J Lepr* 1984; 56: 63-70. PubMed PMID: 6384381.

(Among 30 patients with leprosy who were treated with daily dapsone and clofazimine and monthly rifampin, all had moderate to marked clinical improvement with 6 to 9 months; adverse events included skin pigmentation and renal dysfunction in 2 patients that responded to withdrawal of rifampin).

Kaluarachchi SI, Fernandopulle BM, Gunawardane BP. Hepatic and haematological adverse reactions associated with the use of multidrug therapy in leprosy--a five year retrospective study. *Indian J Lepr* 2001; 73: 121-9. PubMed PMID: 11579648.

(Among 3333 cases of leprosy treated with multidrug therapy between 1991-95, 25 patients had "toxic hepatitis" which was attributed to dapsone).

Shaw IN, Christian M, Jesudasan K, Kurian N, Rao GS. Effectiveness of multidrug therapy in multibacillary leprosy: a long-term follow-up of 34 multibacillary leprosy patients treated with multidrug regimens till skin smear negativity. *Lepr Rev* 2003; 74: 141-7. PubMed PMID: 12862255.

(Among 34 patients with multibacillary leprosy treated with 2 regimens of rifampin, dapsone and clofazimine for 2 years, all responded and none relapsed during mean follow up of 13 years; the only adverse event was reversible skin discoloration attributed to clofazimine).

Pais AV, Pereira S, Garg I, Stephen J, Antony M, Inchara YK. Intra-abdominal, crystal-storing histiocytosis due to clofazimine in a patient with lepromatous leprosy and concurrent carcinoma of the colon. *Lepr Rev* 2004; 75: 171-6. PubMed PMID: 15282969.

(44 year old woman with lepromatous leprosy treated with clofazimine for several years was found to have blackish discoloration of omentum and abdominal lymph nodes and clofazimine crystals in histiocytes during surgery for an unrelated metastatic carcinoma).

Dacso MM, Jacobson RR, Scollard DM, Stryjewska BM, Prestigiacomo JF. Evaluation of multi-drug therapy for leprosy in the United States using daily rifampin. *South Med J* 2011 Oct; 104: 689-94. PubMed PMID: 21941157.

(Review of 158 cases of multibacillary leprosy treated with a multidrug regimen from a U.S. registry [1988-1997], found only one case of relapse, a patient who received a 2-drug regimen [dapsone and daily rifampin] for 2 years).

Singh H, Nel B, Dey V, Tiwari P, Dulhani N. Adverse effects of multi-drug therapy in leprosy, a two years' experience (2006-2008) in tertiary health care centre in the tribal region of Chhattisgarh State (Bastar, Jagdalpur). *Lepr Rev* 2011; 82: 17-24. PubMed PMID: 21644468.

(Among 176 patients treated with multidrug therapy for leprosy in India, 79 [45%] had 84 drug related adverse effects, including 73 from dapsone, 8 rifampin and 16 clofazimine manifested by skin discoloration in 2, gastrointestinal upset in 13 and hematemesis in 3).

Cholo MC, Steel HC, Fourie PB, Germishuizen WA, Anderson R. Clofazimine: current status and future prospects. *J Antimicrob Chemother* 2012; 67: 290-8. PubMed PMID: 22020137.

(Review of the molecular structure, antimicrobial activity, mechanisms of action, pharmacokinetics, adverse effects and antiinflammatory activity of clofazimine).

Cariello PF, Kwak EJ, Abdel-Massih RC, Silveira FP. Safety and tolerability of clofazimine as salvage therapy for atypical mycobacterial infection in solid organ transplant recipients. *Transpl Infect Dis* 2015; 17: 111-8. PubMed PMID: 25620390.

(Among 5 solid organ transplant recipients with mycobacterium avium complex infection who were treated with clofazimine, 2 were cured, 2 died and 1 had gastrointestinal intolerance, side effects included skin discoloration in 3, but "hepatotoxicity was not observed").

Talhari C, Talhari S, Penna GO. Clinical aspects of leprosy. *Clin Dermatol* 2015; 33: 26-37. PubMed PMID: 25432808.

(Review of the clinical features and diagnosis of leprosy).

Kar HK, Gupta R. Treatment of leprosy. *Clin Dermatol* 2015; 33: 55-65. PubMed PMID: 25432811.

(Review of the current regimens for therapy of leprosy, the first line regimen being dapsone, clofazimine and rifampin given for 6 [pauci-bacillary] or 12 [multi-bacillary] months, now available in blister packs of 4 weeks of treatment).

Noordeen SK. History of chemotherapy of leprosy. *Clin Dermatol* 2016; 34: 32-6. PubMed PMID: 26773621.

(History of the development of therapies for leprosy starting with sulfonamides, and then sulfones such as dapsons, followed by clofazimine and then rifampin, maturing with multidrug therapy using all three for a defined period [1 or 2 years] with monthly rifampin).

Szeto W, Garcia-Buitrago MT, Abbo L, Rosenblatt JD, Moshiree B, Morris MI. Clofazimine enteropathy: a rare and underrecognized complication of mycobacterial therapy. *Open Forum Infect Dis* 2016; 3: ofw004. PubMed PMID: 27800519.

(68 year old woman with lymphoma and hematopoietic cell transplant developed abdominal pain and diarrhea one month after starting clofazimine for Mycobacterium abscessus infection, which was nevertheless continued for 6 months, the pain, diarrhea and weight loss resolving with stopping; no mention of ALT elevations or hepatotoxicity).

Smith CS, Aerts A, Saunderson P, Kawuma J, Kita E, Virmond M. Multidrug therapy for leprosy: a game changer on the path to elimination. *Lancet Infect Dis* 2017; 17: e293-e7. PubMed PMID: 28693853.

(Leprosy is still present in 100 low income countries with more than 200,000 cases diagnosed yearly despite multidrug therapy that is highly effective and has been used on 16 million patients supported by long term efforts by WHO, financial support by the Nippon Foundation and donation of the 3 drug combination by Novartis).

Martiniano SL, Wagner BD, Levin A, Nick JA, Sagel SD, Daley CL. Safety and effectiveness of clofazimine for primary and refractory nontuberculous mycobacterial infection. *Chest* 2017; 152: 800-9. PubMed PMID: 28483608.

(Among 117 patients with non-tuberculosis mycobacterial infections who were treated with clofazimine in combination with other agents for a median of 1 year, adverse events included skin rash or discoloration [66%], gastrointestinal complaints [55%] and ALT elevations of greater than 3 times ULN [3%], but no instances of clinically apparent liver injury).

Available at: <https://www.hrsa.gov/hansens-disease/index.html>

(Website for the National Hansen's Disease [Leprosy] Program with information on diagnosis and treatment, including means of obtaining triple therapy).

(Website for the National Hansen's Disease [Leprosy] Program with information on diagnosis and treatment, including means of obtaining triple therapy).