



## Osimertinib

Updated: June 1, 2017.

## OVERVIEW

### Introduction

Osimertinib is a small molecule tyrosine kinase receptor inhibitor and antineoplastic agent that is used in the therapy of selected forms of advanced non-small cell lung cancer (NSCLC). Osimertinib is associated with a moderate rate of serum aminotransferase elevations during therapy and rare instances of clinically apparent acute liver injury.

### Background

Osimertinib (oh" sim er' ti nib) is a small molecule tyrosine kinase receptor inhibitor with potent activity against the epidermal growth factor receptor (EGFR) that is rearranged and mutated in selected cancers including approximately 5% of non-small cell lung cancer (NSCLC). The mutated, rearranged EGFR promotes unregulated cell growth and proliferation, and inhibition of its activity can result in death of cells that overexpress the receptor. Osimertinib has been found to inhibit mutated EGFR in cell culture and, in several clinical trials, was found to induce objective responses in a proportion of patients with advanced EGFR mutated (T790M) NSCLC. Osimertinib received accelerated approval for use refractory, EGFR T790M-positive NSCLC in the United States in 2015. Osimertinib is available in tablets of 40 and 80 mg under the brand name Tagrisso. The recommended initial dose is 80 mg once daily, continued until progressive disease or intolerable toxicity occurs. Side effects are common and include diarrhea, rash, dry skin and nail toxicity. Uncommon, but potentially severe side effects include interstitial lung disease, prolongation of the QTc interval, cardiomyopathy and embryo-fetal toxicity.

### Hepatotoxicity

Elevations in serum aminotransferase levels are uncommon during osimertinib therapy occurring in 4% to 5% of patients and rising above 5 times the upper limit of the normal range in only 1% or less. In preregistration trials, there was a single incidence of clinically apparent liver injury attributed to osimertinib therapy, but the clinical features and relatedness to therapy were not defined. Since its approval and more widespread use, there have been no published cases of liver injury due to osimertinib.

Likelihood score: E\* (unproven but suspected cause of clinically apparent liver injury).

### Mechanism of Injury

The mechanism by which osimertinib might cause liver injury is not known. Osimertinib is metabolized by the liver predominantly by CYP 3A4 and is susceptible to drug-drug interactions with agents that induce or inhibit CYP 3A4.

## Outcome and Management

Serum enzyme elevations during osimertinib therapy are uncommon, but elevations above 5 times the upper limit of normal (if confirmed) should lead to temporary discontinuation, which should be permanent if laboratory values do not improve significantly or resolve within a few weeks or if symptoms or jaundice arises. There does not appear to be cross reactivity with other EGFR inhibitors and, in some situations, switching to another protein kinase inhibitor may be appropriate.

Drug Class: [Antineoplastic Agents](#), [Protein Kinase Inhibitors](#)

## PRODUCT INFORMATION

### REPRESENTATIVE TRADE NAMES

Osimertinib – Tagrisso®

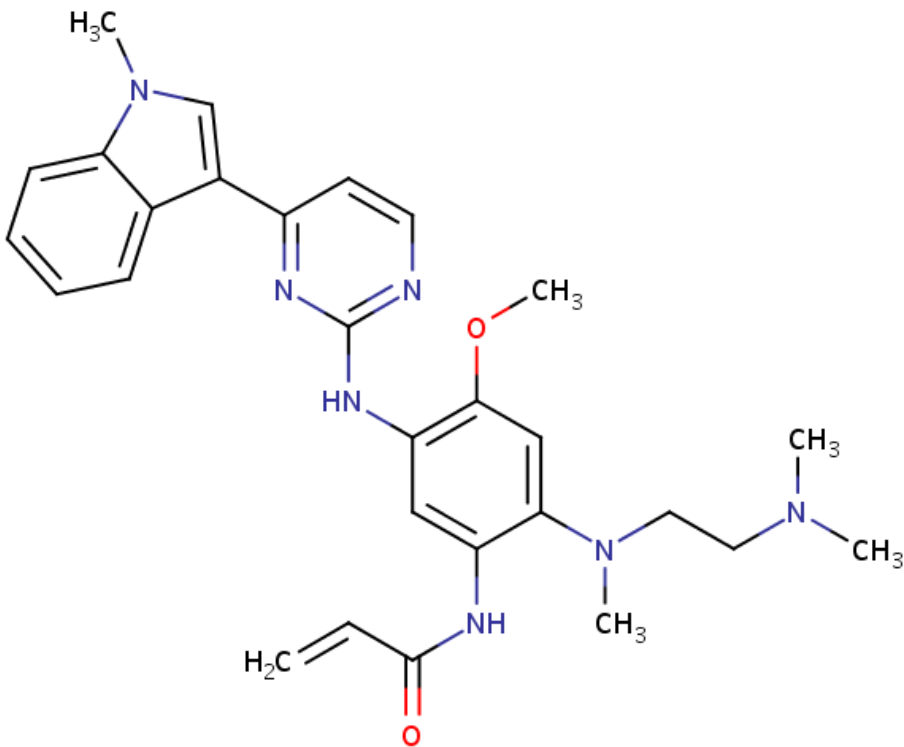
### DRUG CLASS

[Antineoplastic Agents](#)

### [COMPLETE LABELING](#)

Product labeling at [DailyMed](#), National Library of Medicine, NIH

## CHEMICAL FORMULA AND STRUCTURE

DRUG	CAS REGISTRY NO.	MOLECULAR FORMULA	STRUCTURE
Osimertinib	1421373-65-0	Not available	 <p>The chemical structure of Osimertinib is a complex molecule. It features a central benzene ring substituted with several groups: a methoxy group (-OCH<sub>3</sub>), a dimethylaminoethyl group (-N(CH<sub>3</sub>)<sub>2</sub>CH<sub>2</sub>CH<sub>2</sub>CH<sub>3</sub>), an acrylamide group (-NHCOCH=CH<sub>2</sub>), and a 1-methyl-1H-indol-3-ylmethyl group (-CH<sub>2</sub>-CH<sub>2</sub>-indole-1-yl). The indole ring has a methyl group (-CH<sub>3</sub>) attached to its nitrogen atom. The pyridine ring is connected to the indole ring via its 2-position.</p>

## ANNOTATED BIBLIOGRAPHY

References updated: 01 June 2017

Abbreviations used: NSCLC, non-small cell lung cancer; EGFR, epidermal growth factor receptor; ULN, upper limit of the normal range

Zimmerman HJ. Hepatotoxicity: the adverse effects of drugs and other chemicals on the liver. 2nd ed. Philadelphia: Lippincott, 1999.

*(Review of hepatotoxicity published in 1999 before the availability of tyrosine kinase receptor inhibitors such as osimertinib).*

DeLeve LD. Erlotinib. Cancer chemotherapy. In, Kaplowitz N, DeLeve LD, eds. Drug-induced liver disease. 3rd ed. Amsterdam: Elsevier, 2013, pp. 556.

*(Review of hepatotoxicity of cancer chemotherapeutic agents published in 2013 discusses the hepatotoxicity of crizotinib, but not osimertinib).*

Chabner BA, Barnes J, Neal J, Olson E, Mujagic H, Sequist L, Wilson W, et al. Targeted therapies: tyrosine kinase inhibitors, monoclonal antibodies, and cytokines. In, Brunton LL, Chabner BA, Knollman BC, eds. Goodman & Gilman's the pharmacological basis of therapeutics. 12th ed. New York: McGraw-Hill, 2011, pp. 1731-54.

*(Textbook of pharmacology and therapeutics).*

Shah RR, Morganroth J, Shah DR. Hepatotoxicity of tyrosine kinase inhibitors: clinical and regulatory perspectives. *Drug Saf* 2013; 36: 491-503. PubMed PMID: 23620168.

*(Review of the hepatotoxicity of 18 tyrosine kinase inhibitors approved for use in cancer in the US as of 2013; crizotinib is listed as causing liver enzyme elevations in up to 57% of patients [ $\geq 5$  times ULN in 6%] and as having been linked cases of hepatitis and fatal hepatic failure; no mention of osimertinib).*

Yang J, Ramalingam SS, Jänne PA, Cantarini M, Mitsudomi T. LBA2\_PR: Osimertinib (AZD9291) in pre-treated pts with T790M-positive advanced NSCLC: updated Phase 1 (P1) and pooled Phase 2 (P2) results. *J Thorac Oncol* 2016; 11 (4 Suppl): S152-3.

*(Preliminary results in two trials of osimertinib in 474 patients with advanced NSCLC with T790M mutated EGFR revealed objective response rates of 66-71% and major side effects of rash and diarrhea).*

Noonan SA, Sachs PB, Camidge DR. Transient asymptomatic pulmonary opacities occurring during osimertinib treatment. *J Thorac Oncol* 2016; 11: 2253-8. PubMed PMID: 27618759.

*(Among 20 patients with NSCLC treated with osimertinib at a single referral center, 7 [35%] developed transient, asymptomatic pulmonary opacities [by CT scan], arising within 2-43 weeks of starting and resolving within 1-11 weeks despite continuation of osimertinib).*

Goss G, Tsai CM, Shepherd FA, Bazhenova L, Lee JS, Chang GC, Crino L, et al. Osimertinib for pretreated EGFR Thr790Met-positive advanced non-small-cell lung cancer (AURA2): a multicentre, open-label, single-arm, phase 2 study. *Lancet Oncol* 2016; 17: 1643-52. PubMed PMID: 27751847.

*(Among 199 patients with NSCLC with T790 mutant EGFR positivity treated with osimertinib [80 mg daily] with an average follow up of 13 months, 70% had an objective response and adverse events included ALT elevations in 5% of patients which were above 5 times ULN in 1%, one patient stopping therapy because of liver injury, no details provided).*

Kotake M, Murakami H, Kenmotsu H, Naito T, Takahashi T. High incidence of interstitial lung disease following practical use of osimertinib in patients who had undergone immediate prior nivolumab therapy. *Ann Oncol* 2017; 28 (3): 669-70. PubMed PMID: 27993813.

*(Among 19 Japanese patients with EGFR-T790M mutation-positive advanced NSCLC treated with osimertinib at a single Japanese institution, 4 developed interstitial lung disease within 4-12 weeks, 3 of whom had previously received nivolumab suggesting a synergistic effect in causing this adverse event; no mention of ALT elevations or liver injury).*

Yang JC, Ahn MJ, Kim DW, Ramalingam SS, Sequist LV, Su WC, Kim SW, et al. Osimertinib in pretreated T790M-positive advanced non-small-cell lung cancer: AURA Study Phase II Extension Component. *J Clin Oncol* 2017; 35 (12): 1288-96. PubMed PMID: 28221867.

*(Among 201 patients with NSCLC with T790M EGFR mutation treated with osimertinib, the objective response rate was 62% and many adverse events were described including diarrhea [43%], rash [40%], and interstitial lung disease [4%], but ALT elevations and hepatotoxicity were not mentioned).*

Mok TS, Wu YL, Ahn MJ, Garassino MC, Kim HR, Ramalingam SS, Shepherd FA, He Y, et al.; AURA3 Investigators. Osimertinib or platinum-pemetrexed in EGFR T790M-positive lung cancer. *N Engl J Med* 2017; 376: 629-40. PubMed PMID: 27959700.

*(Among 419 patients with refractory EGFR T790M-positive NSCLC treated with osimertinib vs platinum-pemetrexed chemotherapy, the objective response rate was greater with osimertinib [71% vs 31%] and serious adverse events were less frequent [23% vs 47%], including lower rates of ALT elevations [6% vs 11%] which were rarely above 5 times ULN [1% in both]).*

Sun JM, Lee SH, Ahn JS, Park K, Ahn MJ. Osimertinib for the treatment of non-small cell lung cancer. *Expert Opin Pharmacother* 2017; 18: 225-31. PubMed PMID: 28116908.

*(Review of the role of osimertinib in therapy of NSCLC, particularly in patients with the T790M mutation in EGFR which underlies resistance to first-generation tyrosine kinase inhibitors of EGFR; only brief mention of adverse events and no mention of ALT elevations or hepatotoxicity).*

Mamesaya N, Kenmotsu H, Katsumata M, Nakajima T, Endo M, Takahashi T. Osimertinib-induced interstitial lung disease after treatment with anti-PD1 antibody. *Invest New Drugs* 2017; 35: 105-7. PubMed PMID: 27599705.

*(38 year old woman with NSCLC and T790M mutation in EGFR received osimertinib shortly after a course of nivolumab [check point inhibitor] and developed interstitial lung disease after 31 days of treated, which improved upon stopping and worsened again on restarting osimertinib; no mention of ALT elevations or liver toxicity).*