

VI THE GASTROINTESTINAL SYSTEM

WILLIAM BEAUMONT, THE MAN AND THE OPPORTUNITY



Born in 1785 in Lebanon, Connecticut, William Beaumont was the son of a thriving farmer and veteran of the Revolutionary War. After declining an offer by his father of a nearby farm, Beaumont left home in 1806 at age 22 with a horse and sleigh, a barrel of cider, and \$100. He settled in Champlain, New York, near the Canadian border, and taught school for 3 years. In 1810, at age 25, Beaumont entered a preceptorship under Benjamin Chandler in St. Albans, Vermont, living in Chandler's home for 2 years as an apprentice. He learned medicine primarily through observation of patients rather than through study of books, and recorded cases and his thoughts in notebooks, a habit he continued throughout his life. At the outbreak of the War of 1812, Beaumont left Chandler with a medical license from Vermont and crossed Lake

Champlain to Plattsburgh, New York, where he entered the army as a surgeon's mate. Over the next 3 years he gained experience treating soldiers and performed numerous autopsies. He participated in the capture of York in 1813 and the Battle of Plattsburgh in 1814, and resigned when the Treaty of Ghent ended the war in 1815.

After 4 years of private practice in Plattsburgh, Beaumont reenlisted in the army in 1819 at age 35 and was ordered to Fort Michilimackinac in the Michigan territory. Built by the British in 1780 on an island, Fort Mackinac was adjacent to a village inhabited by about 500 French Canadians and Indians employed by the American Fur Company. In June and July, however, Mackinac swelled with 5000 traders bearing their winter catch. Osler memorialized Fort Mackinac in a beautiful essay on Beaumont that begins:

Come with me for a few moments on a lovely June day in 1822, to what were then far-off northern wilds, to the Island of Michilimackinac, where the waters of Lake Michigan and Lake Huron unite and where stands Fort Mackinac, rich in the memories of Indian and voyageur, one of the four important posts on the upper lakes in the days when the rose and fleur-de-lys strove for the mastery of the western world. (Osler, 1902)

Beaumont was the only physician on the island in June 1822 when Alexis St. Martin, a 19-year-old French Canadian, was accidentally shot by a gun in the store of the American Fur Company. Beaumont's record of the event follows:

I was called to him immediately after the accident. Found a portion of the Lungs as large as a turkey's egg protruding through the external wound, lacerated and burnt, and below this another protrusion resembling a portion of the Stomach, what at first view I could not believe possible to be that organ in that situation with the subject surviving, but on closer examination I found it to be actually the Stomach, with a puncture in the protruding portion large enough to receive my fore-finger, and through which a portion of his food that he had taken for breakfast had come out and lodged among his apparel. In this dilemma I considered my attempt to save his life entirely useless. (Myers, 1912)

Under Beaumont's care, St. Martin survived the immediate effects of the wound but acquired a gastrocutaneous fistula, where the wounded stomach adhered to intercostal muscles. St. Martin remained debilitated and destitute after 10 months, so Beaumont took him into his own home and sustained him.

After 2 years of treating St. Martin, Beaumont published a letter describing "A Case of Wounded Stomach" in the *Philadelphia Medical Recorder* in January 1825. His scientific curiosity was increasing at the same time, and he wrote in his journal:

This case affords an excellent opportunity for experimenting upon the gastric fluids and process of digestion. It would give no pain, nor cause the least uneasiness, to extract a gill of fluid every two or three days, for it frequently flows out spontaneously in considerable quantities. Various kinds of digestible substances might be introduced into the stomach and then easily examined during the process of digestion. I may, therefore, be able hereafter to give some interesting experiments on these subjects. (Myers, 1912)

He began those experiments in May 1825 at Fort Mackinac and completed the last in 1833 at Plattsburgh. In 1833, at age 48, Beaumont published his *Experiments and Observations on the Gastric Juice and the Physiology of Digestion*, a 280-page book divided into two sections. The first contains general observations on various topics in gastroenterology. The second contains a description of the 238 experiments, concluding with 51 inferences. Osler (1902) considered the following to be the important contributions of Beaumont: (1) a more accurate and complete description of gastric juice; (2) confirmation of the previous observation that hydrochloric acid was the important acid of gastric juice; (3) recognition that gastric juice and mucus were separate secretions; (4) establishment of the influence of mental disturbance on secretion of gastric juice and digestion; (5) a more accurate and fuller comparison of the action of gastric juice inside and outside the stomach; (6) refutation of many erroneous opinions; (7) the first comprehensive study of motions of the stomach; and (8) a table of the digestibility of different articles of diet.

St. Martin left Beaumont forever in 1834. A year later, at age 50, Beaumont was ordered to St. Louis, where he lived the rest of his life and engaged in a

lucrative private practice. When Captain Robert E. Lee and his family were stationed at St. Louis, they dined often at the Beaumont home. When he was ordered to Florida after 4 years in St. Louis, Beaumont submitted a conditional resignation, which was accepted in 1840, ending 25 years of military service. He died in 1853 at age 68 but will be remembered for an extraordinary 9-year period of his life, from 1825 to 1833, during which his 238 experiments on St. Martin were conducted. As Osler said, "The man and the opportunity had met."

—CHARLES STEWART ROBERTS

REFERENCES

Myers JS. Life and letters of Dr. William Beaumont. St. Louis: C. V. Mosby, 1912.

Osler W. William Beaumont. A pioneer American physiologist. JAMA 1902;39:1223-31.

80

An Overview of the Gastrointestinal System

CHARLES M. FERGUSON

Evaluation of the gastrointestinal tract requires careful history and physical examination techniques. Though sophisticated laboratory tests or radiographic or endoscopic procedures may be necessary to confirm a diagnosis of intra-abdominal pathology, the initial diagnosis is usually suspected from the history and reinforced by physical examination. Most important, therapeutic decisions for intra-abdominal inflammatory processes are based mainly on findings that can be elicited only by careful physical examination. Thus, though physical examination of the abdomen is difficult, it is a skill that must be mastered for proper management of these patients.

History

Table 80.1 lists symptoms of gastrointestinal disease. Pain is the most common complaint related to abdominal problems. Important points to cover with the patient are the location and duration of the pain, any change in its location or intensity, any known precipitating factors, and any associated symptoms (fever, chills, nausea, vomiting, or change in bowel habits). One must also inquire as to associated abdominal findings such as bloody stools, melena, or abdominal distention.

Once the examiner has a clear idea of the present illness, he or she should inquire as to previous such episodes of illness or similar illnesses. A brief history of previous illnesses, acute or chronic, may be helpful, and a review of all previous operations, medications, and allergies is imperative.

Physical Examination

Table 80.2 presents the sequence of steps for examining the gastrointestinal system. No special instruments are required for examination of the abdomen. Good lighting and a stethoscope are all that is needed. Common abnormalities that may be disclosed during the examination are listed in Table 80.3.

Table 80.1
Symptoms of Gastrointestinal Diseases

Symptom	Chapter
Pain	86
Indigestion and heartburn	83
Nausea and vomiting	84
Dysphagia	82
GI bleeding	85
Jaundice	87
Diarrhea	88
Constipation	89

For convenience, the abdomen is divided into quadrants (Figure 80.1) and areas (Figure 80.2). The umbilicus is the central point of the abdomen dividing right from left, upper from lower. Masses found on inspection or palpation, or tenderness found on palpation, are described according to the quadrant in which they are found. For example, the swollen gallbladder of acute cholecystitis may cause a tender mass in the right upper quadrant. It is thus important to relate the quadrants of the abdomen to the underlying organs (Figure 80.3).

Inspection

The patient is placed supine on an examining table or bed. It is helpful to place a small pillow beneath the knees to relax the abdominal musculature. The head should rest comfortably on a small pillow. The patient's arms should rest comfortably at the sides. Drapes should be placed over the breasts and groins just below the inguinal regions to preserve modesty. The examiner stands on the patient's right.

The general contour of the abdomen is examined for any abnormalities. Notice is made as to whether the abdomen is distended or scaphoid, whether there is any bulging in the flanks, and whether the umbilicus is inverted or evert-

Table 80.2
Sequence of Examination of the Gastrointestinal System

Step	Position	Chapter
Inspection	Supine, head and knees supported	93
Auscultation	Supine, head and knees supported	93
Palpation	Supine, head and knees supported	93
Percussion	Supine, head and knees supported	93
Check for ascites	Supine, may need to roll patient for shifting dullness	93
Rectal examination	Left lateral decubitus	97
Inguinal examination	Standing	96

Table 80.3
Common Abnormalities of Abdominal Examination

Anatomical structure	Abnormality	Common condition	Chapter
Umbilicus	Mass or protrusion	Hernia Sister Mary Joseph's node	93
	Prominent veins	Portal hypertension	93
Stomach	Mass in left upper quadrant	Gastric carcinoma Gastric outlet obstruction	93
Pancreas	Mass in right upper quadrant	Pancreatic carcinoma Pancreatic pseudocyst	93
Gallbladder	Mass in right upper quadrant	Cholecystitis Carcinoma of gallbladder Hydrops of gallbladder	93
	Tenderness and guarding in right upper quadrant	Acute cholecystitis	93
Small intestine	Decreased bowel sounds	Ileus	93
	Increased bowel sounds	Obstruction	93
Colon	Abdominal mass	Carcinoma	93
Liver	Increased size	Hepatitis Metastatic carcinoma Cirrhosis	95
	Decreased size	Cirrhosis	95
	Nodularity	Metastatic carcinoma Cirrhosis	95
Spleen	Increased size	Acute viral infections Portal hypertension Hemolytic anemia	93
Peritoneal space	Presence of ascites	Portal hypertension Metastatic carcinoma Congestive heart failure	93
Anus and rectum	Anal mass	Hemorrhoid Anal carcinoma	97
	Anal inflammatory lesion	Fissure Fistula	97
	Rectal mass	Rectal carcinoma Benign rectal ulcer	97
Inguinal canal	Reducible mass	Direct hernia Indirect hernia Femoral hernia	96

ed. The skin of the abdominal wall is examined carefully for hemangiomas or the dilated veins of a caput Medusa, both indicative of severe liver disease. The skin should also be examined carefully for scars, correlating these with previous operations.

Each quadrant of the abdomen is next carefully inspected for any visible masses. The abdominal wall is inspected carefully during respiration for any asymmetry of motion. Any such asymmetry may well be due to muscular rigidity from underlying inflammation.

All surgical scars are carefully inspected for bulges, which may indicate herniation. The patient should be asked to cough to check again for herniation. Similarly, one should inspect the inguinal and femoral regions for herniation during normal respiration and during cough.

Auscultation

In abdominal examination auscultation is performed before palpation, as palpation may alter the bowel sounds. Starting

in the right upper quadrant, the examiner listens over the liver for rubs or bruits and over the free abdominal wall for bowel sounds. One moves next to the left upper quadrant, again listening for bowel sounds and then over the spleen to detect rubs or bruits. One should next auscultate in the periumbilical regions for aortic or renal bruits and for bowel sounds and then in the left and right lower quadrants for bowel sounds or iliac bruits. If, during the course of auscultation, no bowel sounds are detected, one should auscultate in the periumbilical region for 3 full minutes before determining that bowel sounds are absent. Important points to note on bowel sounds are the pitch, intensity, and duration of the sounds. Any bruits noted should be carefully localized to the loudest point as this relates to the origin of the bruit.

Palpation

Palpation of the abdomen involves using the flat of the hand and fingers, not the fingertips (Figure 80.4) to detect palpa-

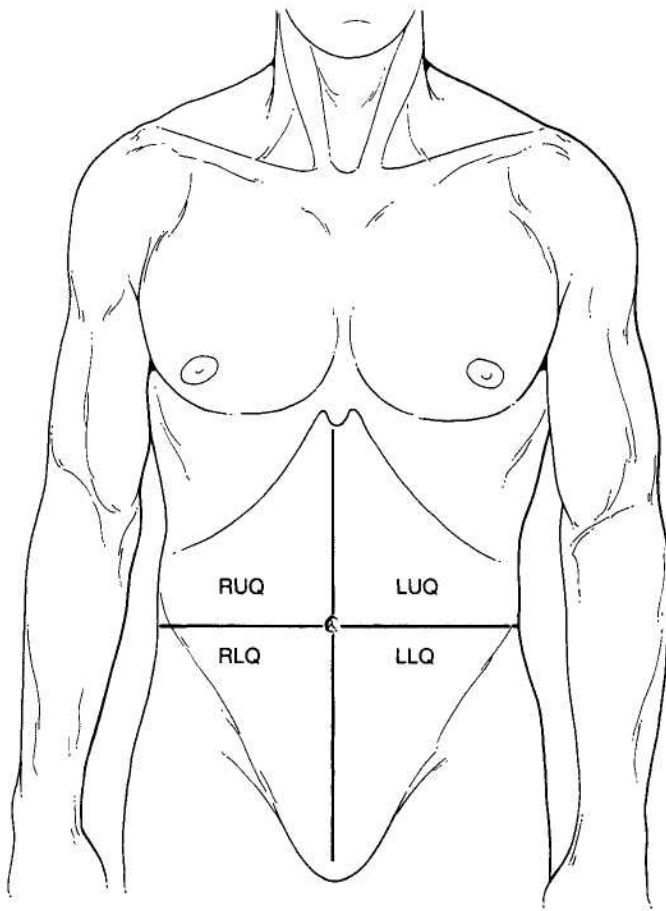


Figure 80.1
The abdominal quadrants; right upper, right lower, left upper, and left lower.

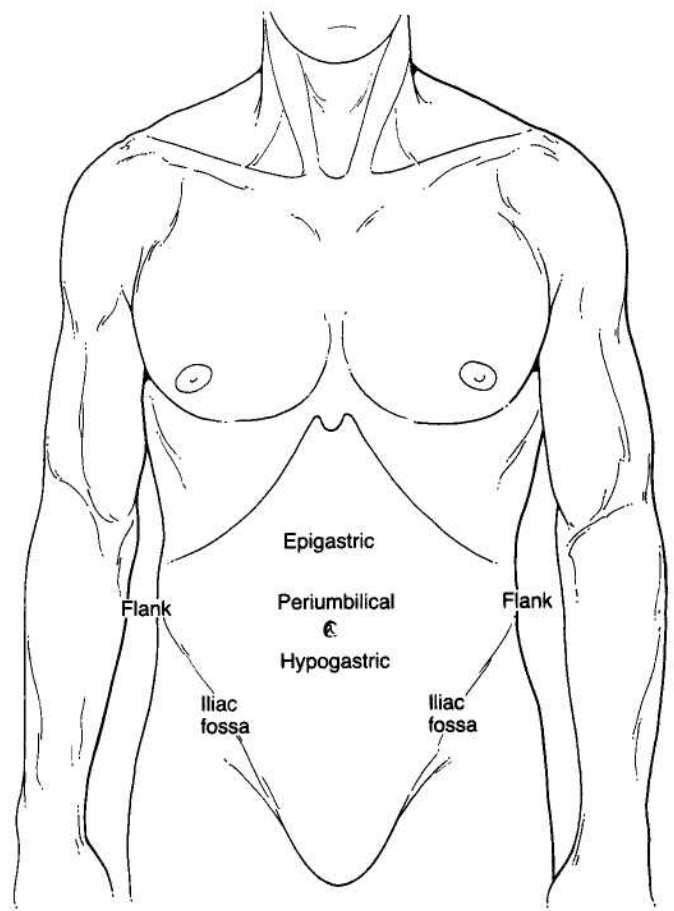


Figure 80.2
The abdominal areas.

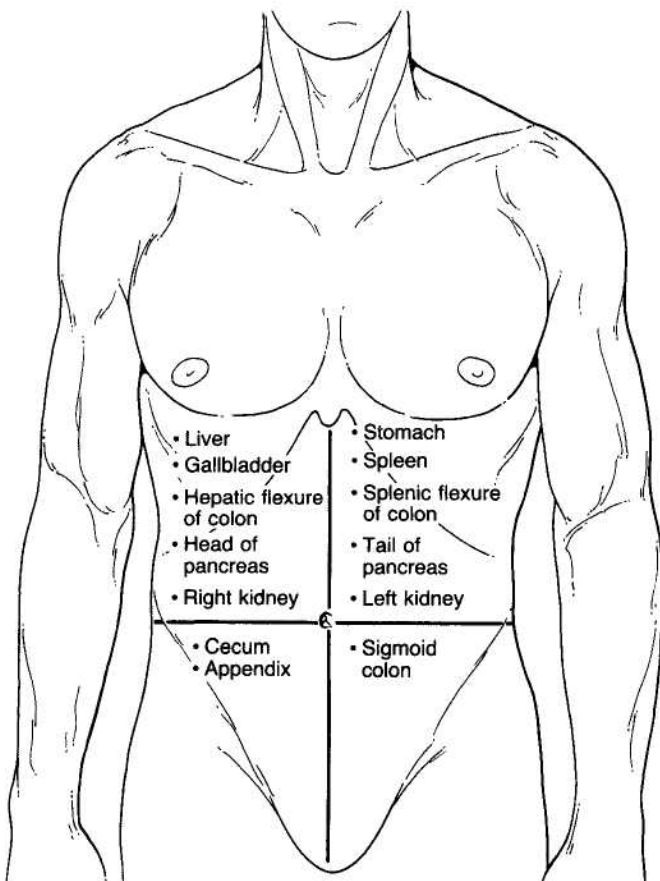


Figure 80.3
Topographic anatomy of the abdomen.

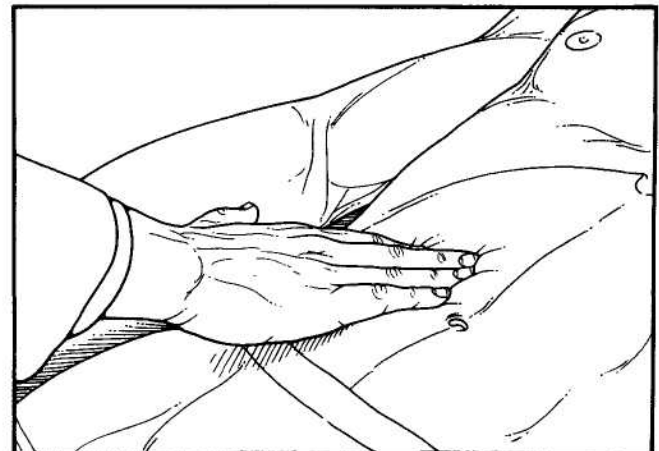


Figure 80.4
Palpation of the abdomen. The flat of the hand and fingers are used for palpation, not the fingertips.

ble organs, abnormal masses, or tenderness. Again, an orderly approach is necessary to prevent oversights. One should begin in the right upper quadrant with palpation of the liver. The flat of the right hand is placed on the abdominal wall with the fingertips pointing toward the right shoulder. The fingertips should be 2 to 3 cm below the costal margin (Figure 80.5). The patient is asked to inspire deeply, bringing the liver edge down to the fingertips. One should note the consistency of the liver and whether there is tenderness. It should be noted whether the edge of the liver is sharp, blunted, or nodular. The examiner's hand may be moved along the liver edge, outlining the size of the liver. An alternative method of palpating the liver is to hook the fingers around the costal margin and have the patient inspire deeply to bring the liver edge down (Figure 80.6). This technique is particularly effective in patients with normal liver size.

After the liver is examined, one palpates the right upper quadrant for masses or tenderness. Again, one uses the flat of the hand and fingers for palpation. If any mass is noted, it often is helpful to outline the mass by using two-handed palpation. The left hand is used to push down on the right hand and thus overcome the abdominal musculature and examine the mass (Figure 80.7). If no mass is noted, one moves on to the left upper quadrant. Again, one palpates carefully for masses or tenderness in the left upper quadrant. An attempt should be made at palpation of the spleen in the same fashion as the liver. The normal spleen will be palpable in only the thinnest of individuals. If the spleen is not palpable in the supine position, the patient is turned to the right lateral position. The examiner stands on the patient's right and palpates with the right hand while using the left hand to exert pressure on the patient's left flank

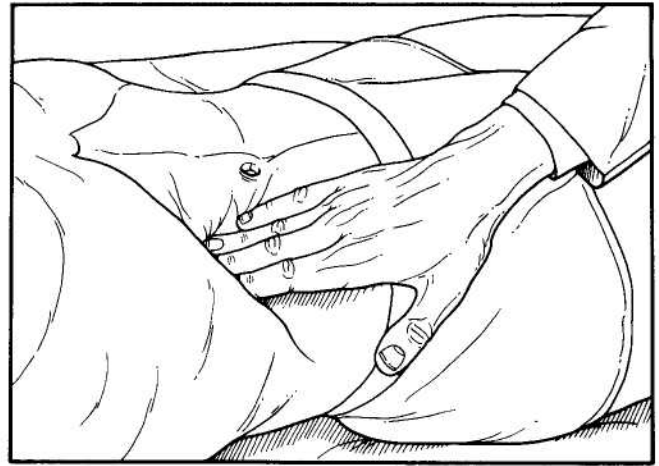


Figure 80.5
Palpation of the liver. The patient inspires deeply, bringing the liver edge to the examiner's fingertips.

(Figure 80.8). This pushes the spleen anteriorly and often makes it palpable.

One next moves to the periumbilical region, again palpating for mass or tenderness. One should be particularly cognizant of the aortic bifurcation being at the umbilicus so that an aortic aneurysm will commonly present as a pulsatile mass at or just above the umbilicus. The umbilicus itself should be carefully palpated for detection of herniation or lymphadenopathy.

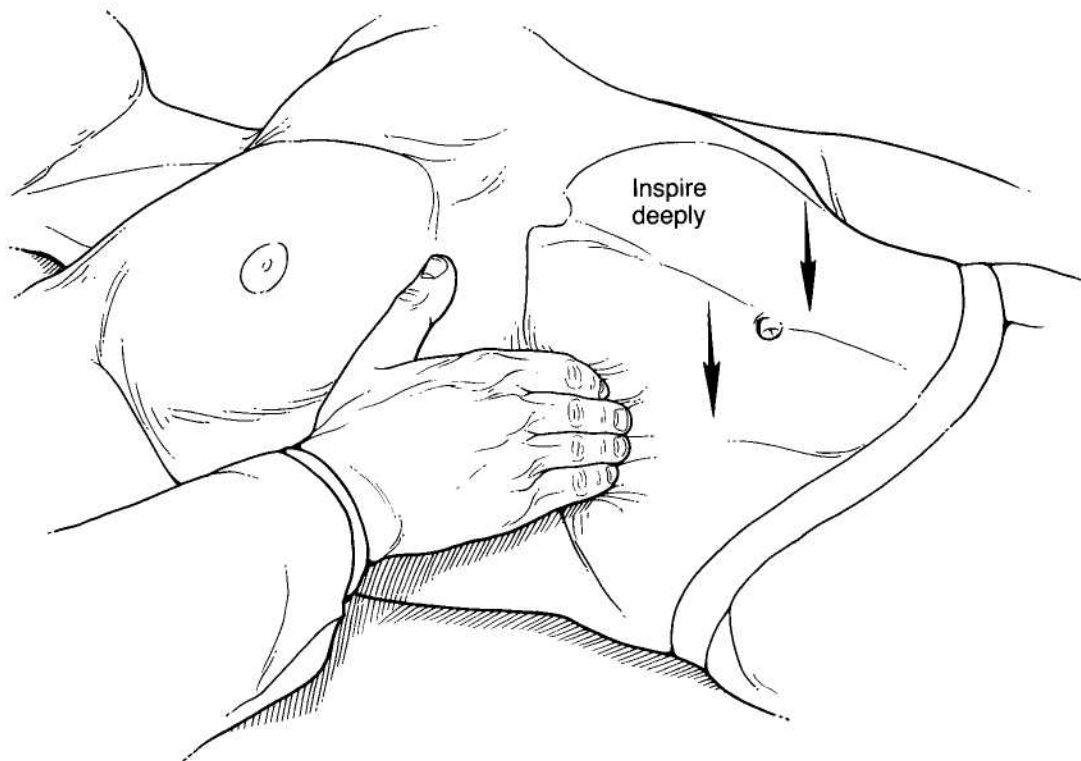


Figure 80.6
Alternative method for palpation of the liver. The fingers are hooked around the costal margin. The patient inspires deeply, bringing the liver edge to the fingertips.

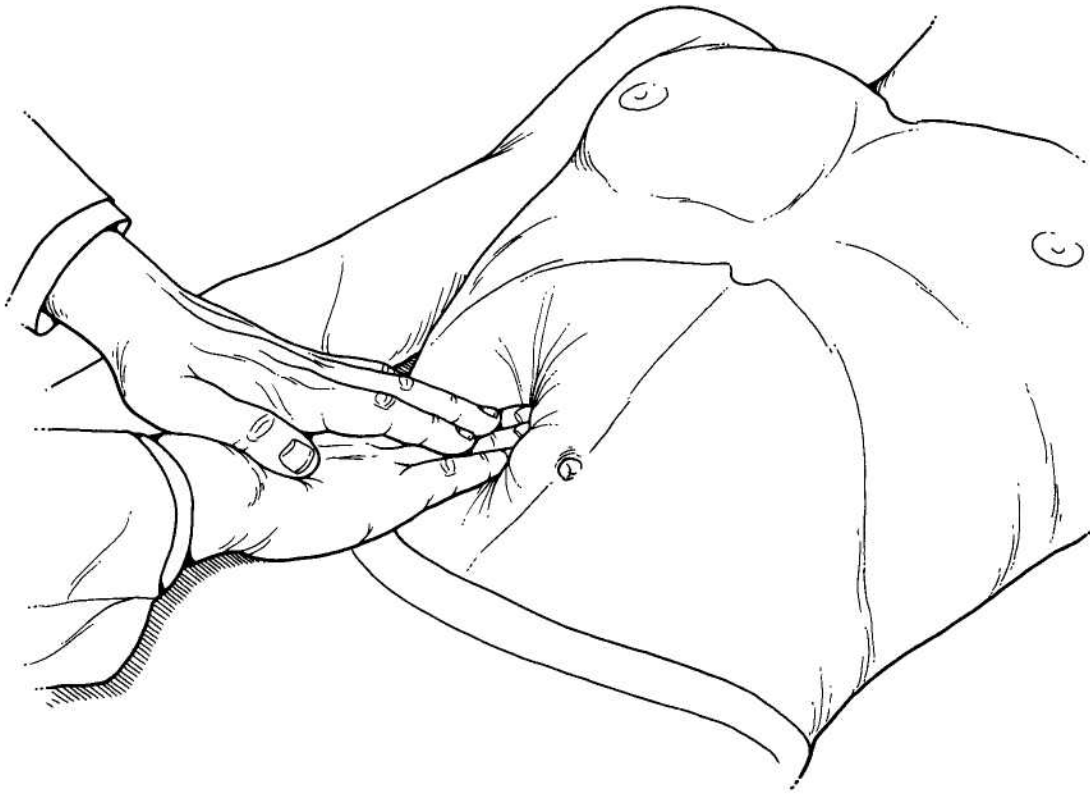


Figure 80.7
Two handed palpation. The left hand is used to push down on the right hand, and thus examine any mass.

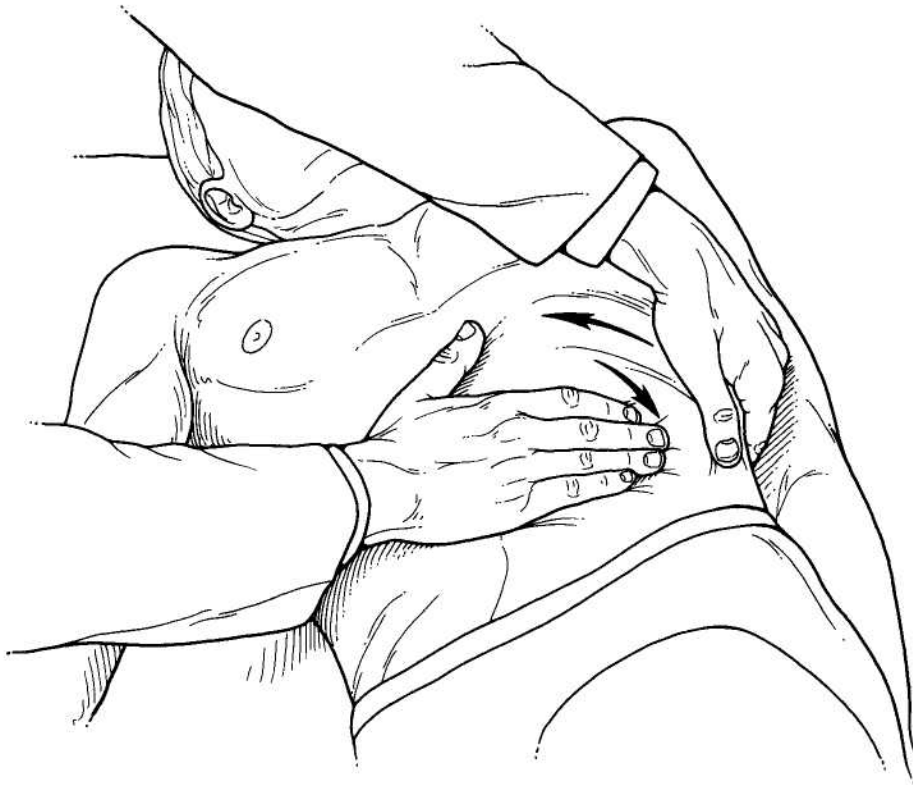

Figure 80.8
Palpation of the spleen. The left hand exerts pressure against the left lower rib cage, pushing the spleen anteriorly to be palpated by the right hand.

The left lower quadrant and flank are next palpated. The lower pole of the left kidney may be palpable in thin individuals as a firm, rounded, smooth mass in the left flank. The sigmoid colon may be palpable as a tubular structure low in the left lower quadrant. Note should be made of any tenderness or abnormal masses in the left lower quadrant. Attention is next directed to the right lower quadrant and flank. As on the left, the lower pole of the right kidney may be palpable in the right flank. The cecum may be palpable

in thin individuals as a fluctuant, poorly defined mass low in the right lower quadrant. Again, note must be made of any abnormal mass or tenderness.

Special attention is next directed to incisional scars. The patient is asked to cough or perform a Valsalva maneuver as the scars are palpated to check for any incisional herniation. Similarly, the inguinal and femoral regions are palpated during cough or Valsalva for detection of hernia.

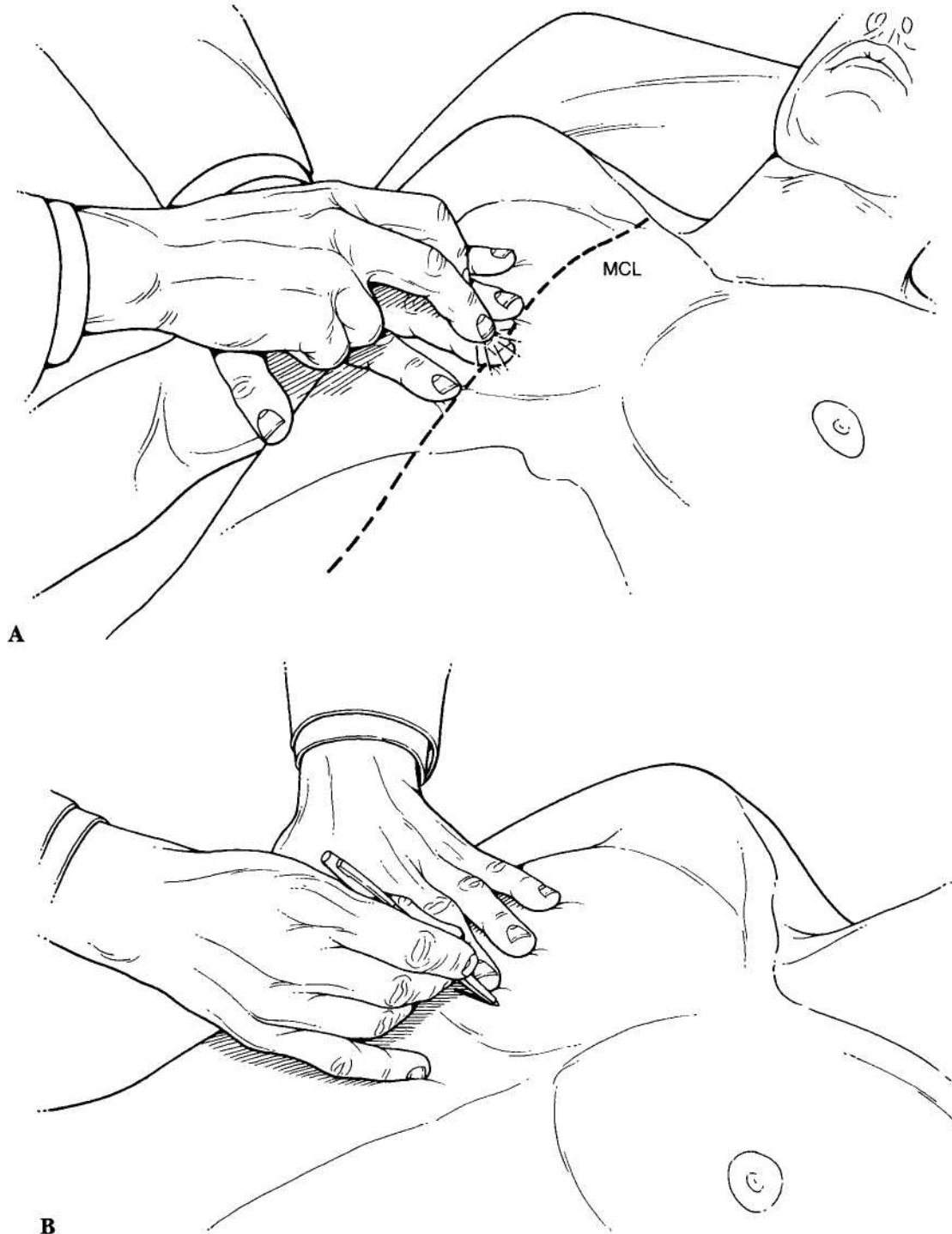

Figure 80.9
(A) Percussion of liver dullness. (B) Point of highest dullness; the dome of the liver.

Percussion

Percussion of the abdomen is performed to check liver size, spleen size, and any abnormal gas collections. The size of the liver is estimated by determining the span of liver dullness by percussion. This is performed by percussing just below the breast in the midclavicular line. A resonant note

should be obtained because of the underlying air (Figure 80.9). Percussion then proceeds caudally from the dome of the liver until dullness is noted. Percussion is then continued caudally until resonance returns, indicating that the examiner has reached the hepatic flexure of the colon at the hepatic edge (Figure 80.10). A normal liver span is 10 to 12 cm. If dullness is absent over the liver, this may be a sign

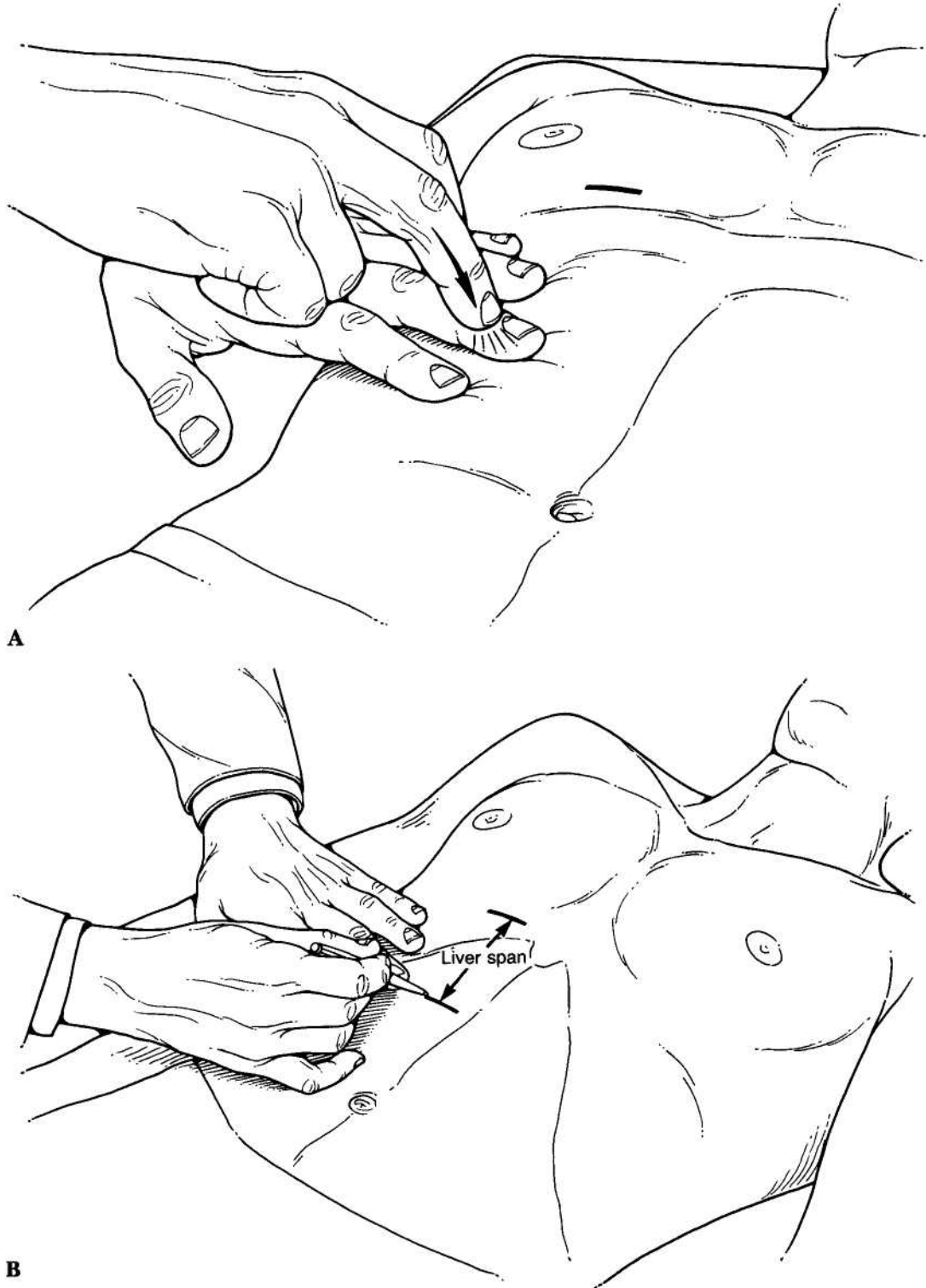


Figure 80.10
 (A) Percussion of the liver at the liver edge. (B) Return of resonance marks liver span.

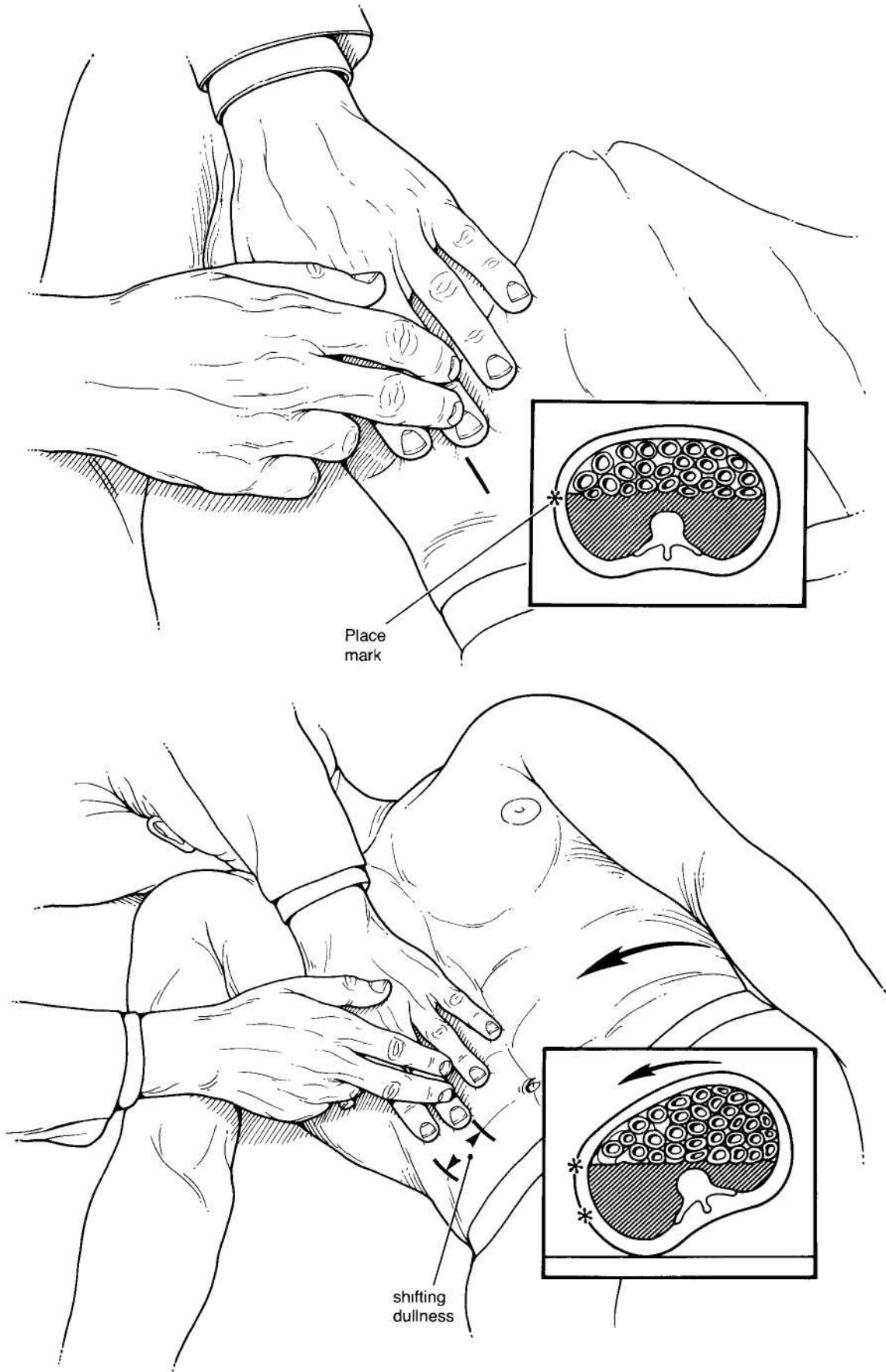


Figure 80.11
Percussion of shifting dullness. See text for explanation.

of intra-abdominal gas, as might occur with a perforated viscus.

Using a similar technique, percussion can be used to outline the size of the spleen. Percussing in the midaxillary line, the normal splenic dullness can be detected from the ninth to the eleventh intercostal space. If the dullness encompasses a larger area, splenomegaly is usually present. Percussion is next performed in the right upper quadrant to check for gas within the hepatic flexure, in the left upper quadrant to check for gas in the stomach or the splenic flexure, in the left lower quadrant to check for gas in the sigmoid, in the right lower quadrant to check for gas in the cecum. Percussion in the periumbilical region should delineate the presence of gas within small bowel loops. Any mass that has been noted on inspection or palpation of the abdomen should also be carefully percussed at this time to determine if there is gas within that mass. This would be indicative of the mass either being a distended loop of bowel or of free intraperitoneal air.

Ascites should be searched for carefully, especially if the patient has bulging flanks or a protuberant abdomen. The most informative examination for the presence or absence of ascites is a search for shifting dullness. This is performed by beginning in the flank with percussion and proceeding anteriorly until the note changes from dull to tympanic, indicating that bowel loops have been reached. This area is marked with a pen and then the patient is rotated toward that flank to allow fluid to shift anteriorly. The examination

is then repeated. Where the note changes from dullness to tympany is again marked. A change from the previous mark indicates free intra-abdominal fluid (Figure 80.11).

Another test that is helpful in identifying ascites is the presence of a fluid wave. The patient or an assistant indents the anterior abdominal wall in the midline; the examiner places the flat of the hand against one flank and then taps gently on the other flank with a finger. If significant ascites is present, a fluid wave should be transmitted from the tapping finger to the receptive hand (Figure 80.12).

Rectal Examination

The patient is next asked to turn to the left lateral decubitus position with the right hip and knee fully flexed and the left hip and knee slightly flexed. The gluteal region should be at the edge of the examining table. The anal area is then carefully examined for any skin lesions, scars, fistula tracts, or external hemorrhoids. The gloved right index finger is then well lubricated and inserted anally. Resistance at the anal ring is usually due to spasm caused by nervousness and may be overcome by asking the patient to strain as the finger is inserted. The anal wall is carefully palpated, taking note of any hypertrophic apillae, inflamed crypts, strictures, and for sphincter tone. The fingertip then palpates the rectum to check for any rectal mass and for the condition of the prostate.

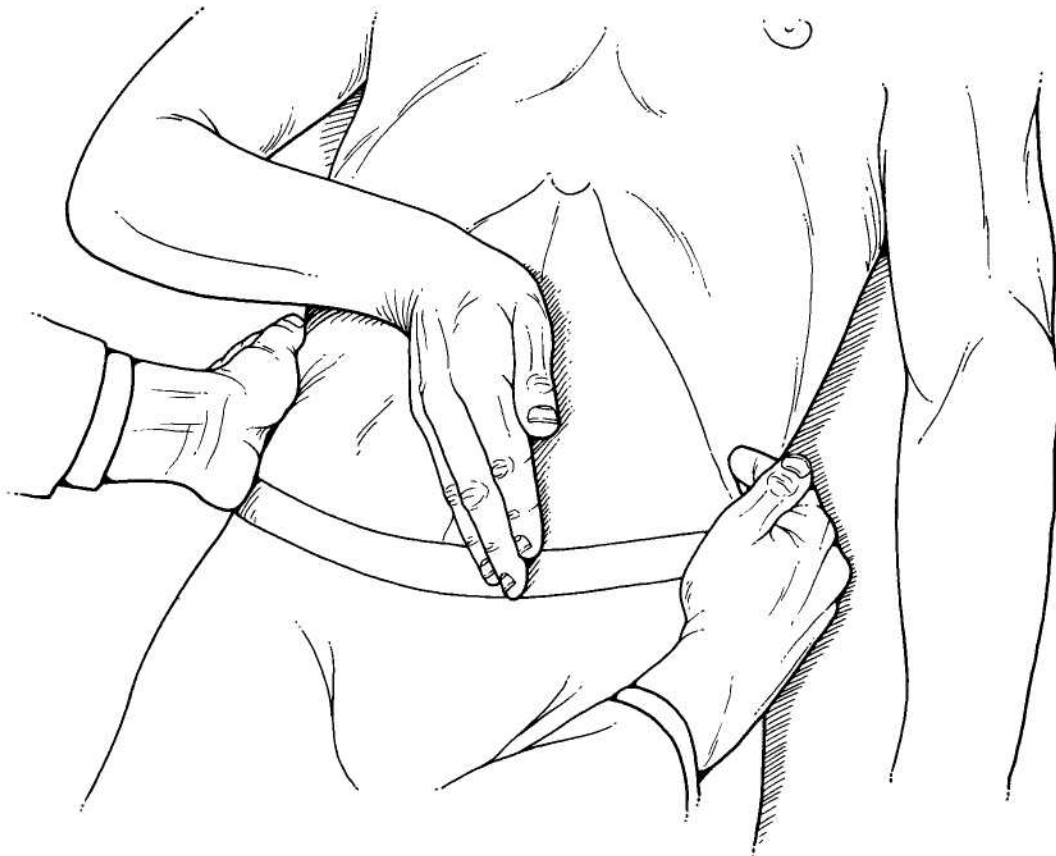


Figure 80.12
Percussion of fluid wave. See text for explanation.

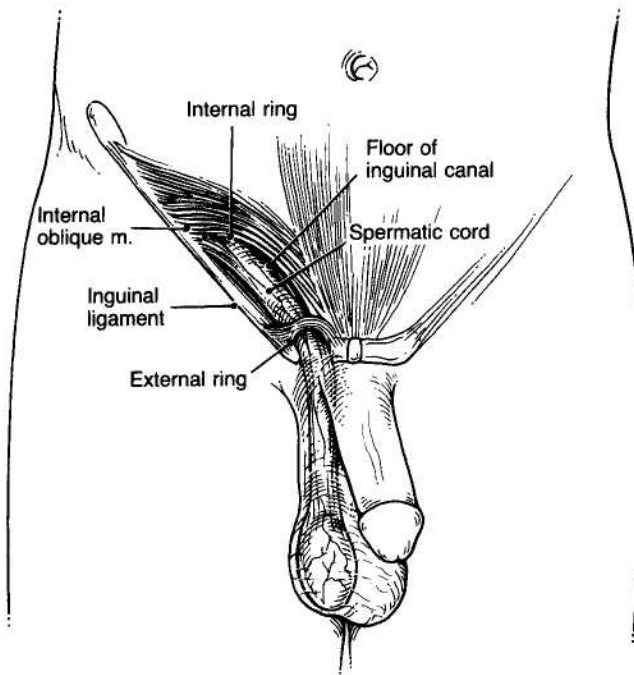


Figure 80.13
Normal inguinal anatomy.

Inguinal Region

Examination of the inguinal region is best performed by having the patient stand erect facing the examiner who is seated on a stool. The examiner should inspect the inguinal region for evidence of abnormal protrusions or masses along the course of the spermatic cord into the scrotum (Figure 80.13). If a suspicious mass is detected on inspection, the patient should be asked to cough to see if any additional impulse occurs. He should be asked to attempt to reduce the mass himself if that is possible.

If no mass is evident, the examiner should palpate the inguinal regions. This is best done by inserting the index finger along the spermatic cord inverting the scrotal skin to the pubic tubercle and then sweeping laterally to identify the external ring (Figure 80.14). The subject is then instructed to cough, and if an indirect inguinal hernia is present, the examiner should detect an impulse as the sac proceeds along the inguinal canal to exit at the external ring. If a general bulge is detected in the medial inguinal region, differentiation between direct and indirect inguinal hernia occasionally can be made on physical examination by pressing directly over the internal ring and thereby arresting descent of the indirect hernia (Figure 80.15). If the subject then coughs again and the same protrusion occurs with the internal ring occluded, one can assume that the hernia is a direct hernia through the lower abdominal wall.

One must keep in mind the possibility of femoral hernias in this region. They exit through the femoral canal and present as a bulge below the inguinal ligament. Occasionally a femoral hernia loops cephalad over the inguinal ligament, presenting as a direct or indirect inguinal hernia. Palpation over the femoral canal should confirm the femoral origination of the hernia.

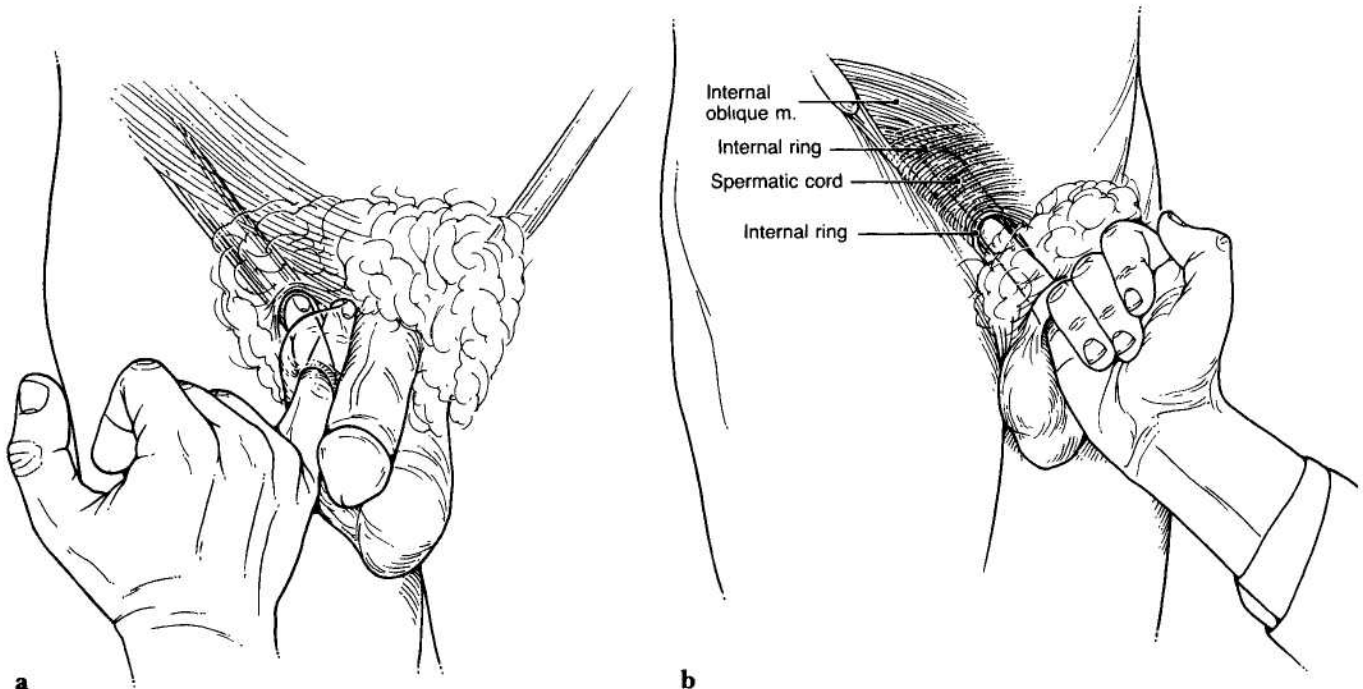


Figure 80.14
Palpation of the inguinal region. (a) The examiner inverts scrotal skin to palpate the inguinal canal. (b) With the finger in the internal ring and inguinal canal, the patient is asked to cough, to check for herniation.

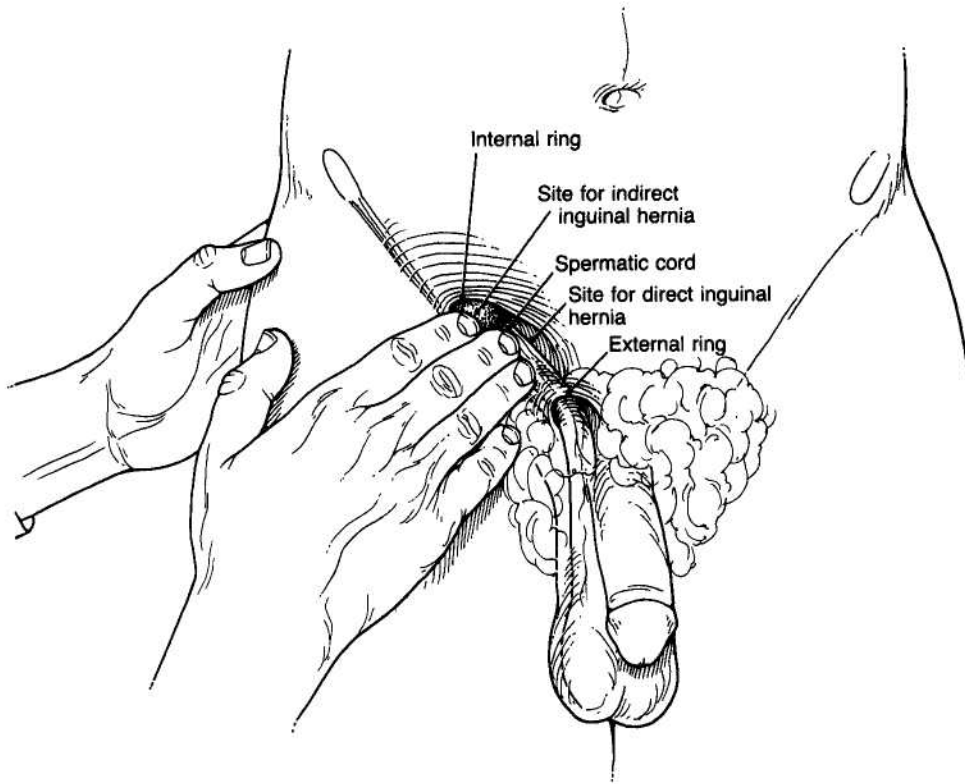


Figure 80.15
Direct compression of the inguinal region to determine site of herniation.