



## TEK-Related Venous Malformations

Emmanuel Seront, MD, PhD,<sup>1</sup> Laurence M Boon, MD, PhD,<sup>2</sup> and Miikka Vikkula, MD, PhD<sup>3</sup>

Created: September 18, 2008; Updated: March 2, 2023.

### Summary

#### Clinical characteristics

*TEK*-related venous malformations (VM) encompass a range of phenotypes. Following the International Society for the Study of Vascular Anomalies (ISSVA) classification, these include common VM (unifocal/isolated VM or multifocal sporadic VM [MSVM]), multiple cutaneous and mucosal VM (VMCM), and blue rubber bleb nevus (BRBN) syndrome. VM are usually present at birth and grow with time, and new lesions can appear over time in individuals with MSVM, VMCM, and BRBN syndrome. Small lesions are usually asymptomatic; larger lesions can extend into other tissues, including subcutaneous tissues and muscles, causing pain and functional limitations. Malignant transformation has not been reported in *TEK*-related VM to date.

#### Diagnosis/testing

The diagnosis of *TEK*-related VM is established in a proband with suggestive findings and either a heterozygous germline gain-of-function pathogenic variant (VMCM) or a somatic (mosaic) gain-of-function pathogenic variant (unifocal VM, MSVM, BRBN syndrome) identified by molecular genetic testing.

#### Management

*Treatment of manifestations:* Sclerotherapy, alone or in combination with plastic and reconstructive surgery, depending on the size and location of the lesions. Low-molecular-weight heparin (LMWH) should be administered prior to any invasive procedure (sclerotherapy and/or surgery) to avoid disseminated intravascular coagulopathy. If D-dimers are elevated and fibrinogen levels are low, LMWH should be initiated one to two weeks before surgery, depending on severity of coagulation abnormality, and continued for two weeks after surgery. If fibrinogen levels are normal, LMWH can be initiated the day before surgery. If lesions are painful and D-dimers are elevated, LMWH can also be used to treat the associated pain. For gastrointestinal VM, endoscopic evaluations with abdominal imaging are needed. Sirolimus has been recently used with some success

**Author Affiliations:** 1 Institut Roi Albert II, Department of Medical Oncology, Cliniques universitaires Saint-Luc, Université catholique de Louvain, Brussels, Belgium; Email: [emmanuel.seront@saintluc.uclouvain.be](mailto:emmanuel.seront@saintluc.uclouvain.be). 2 Center for Vascular Anomalies, Division of Plastic Surgery, Cliniques universitaires Saint-Luc, Université catholique de Louvain, Brussels, Belgium; Email: [laurence.boon@saintluc.uclouvain.be](mailto:laurence.boon@saintluc.uclouvain.be). 3 Human Molecular Genetics, de Duve Institute, Université catholique de Louvain, Brussels, Belgium; Email: [miikka.vikkula@uclouvain.be](mailto:miikka.vikkula@uclouvain.be).

in individuals with *TEK*-related VM who do not respond to or are ineligible for surgery or sclerotherapy, and has been shown to reduce pain and functional complications.

*Surveillance:* Clinical reevaluation of *TEK*-related VM lesions annually and if symptoms arise. D-dimer levels should be measured every five years, if lesions become painful, and before any surgical and/or sclerotherapeutic procedure. Individuals on sirolimus should be closely followed at the beginning and throughout the course of their treatment, in order to modify the dosage as well as manage adverse events.

*Agents/circumstances to avoid:* Contraceptive pills with high estrogen concentration.

*Evaluation of relatives at risk:* Physical examination of at-risk neonates to identify those who can benefit from early treatment.

*Pregnancy management:* D-dimer levels should be evaluated every one to three months during pregnancy (depending on the symptoms) and prior to delivery to adjust LMWH therapy and to avoid abnormal bleeding during delivery.

## Genetic counseling

*TEK*-related VM are either inherited in an autosomal dominant fashion (*TEK*-related VMCM) or caused by somatic (mosaic) variants (*TEK*-related unifocal VM, MSVM, and BRBN syndrome).

For *TEK*-related VMCM, most individuals have an affected parent. The proportion of cases caused by a *de novo* pathogenic variant is unknown; none have been reported to date. In some affected individuals, lesions are small. Therefore, careful skin examination is needed in order to determine if a family member is affected. Each child of an individual with *TEK*-related VMCM has a 50% chance of inheriting the pathogenic variant. Prenatal testing for a pregnancy at increased risk is possible if the *TEK* pathogenic variant has been identified in an affected family member.

With regards to other *TEK*-related phenotypes, unifocal VM, MSVM, and BRBN syndrome are not known to be inherited, as identified pathogenic variants to date are somatic (mosaic). No confirmed vertical transmission or sib recurrence has been reported to date. The risk to sibs of a proband with somatic mosaicism for a pathogenic variant in *TEK* would be expected to be the same as in the general population. Due to mosaicism, the risk for transmission to offspring is expected to be less than 50%.

## GeneReview Scope

### GeneReview Scope: *TEK*-Related Venous Malformations

Pathology	Unifocal (Isolated) VM	Multifocal Sporadic VM (MSVM)	Multiple Cutaneous & Mucosal VM (VMCM)	Blue Rubber Bleb Nevus (BRBN) Syndrome
<b>ISSVA classification</b> <sup>1</sup>	Common VM		Familial VM cutaneous-mucosal	Blue rubber bleb nevus (Bean) syndrome
<b>Molecular etiology</b>	Somatic (mosaic) pathogenic variant	Somatic (mosaic) pathogenic variant + second somatic pathogenic variant	Germline (inherited) + somatic (mosaic) pathogenic variant	Somatic (mosaic) pathogenic variant + second somatic pathogenic variant
<b>Genetic counseling</b>	Risk for offspring presumed to be the same as general population risk	≤50% risk for offspring due to possibility of germline mosaicism	Autosomal dominant (50% risk for offspring)	Risk for offspring presumed to be the same as general population risk

VM = venous malformations

Adapted from Figure 4 in Soblet et al [2017] ([full text](#))

1. See [ISSVA Classification for Vascular Anomalies](#).

## Diagnosis

TEK-related venous malformations (VM) encompass a range of VM caused by germline (familial or inherited) or somatic (mosaic) pathogenic variants in *TEK*. Based on the phenotype and type of *TEK* variant, several phenotypes are delineated (see [GeneReview Scope](#)).

## Suggestive Findings

TEK-related VM **should be suspected** in a proband with the following clinical features, laboratory findings, and family history.

### Clinical Features

Cutaneous and/or mucosal bluish-purple VM can be either single or multiple, and can vary in size from a few millimeters in diameter to larger lesions affecting an entire extremity (see Figure 1 and Figure 2).

- Lesions are soft and usually compressible.
- Ultrasound examination reveals saccular compressible venous-like cavities and Doppler confirms slow blood flow.

In **multiple cutaneous and mucosal VM (VMCM)**, **multifocal sporadic VM (MSVM)**, and **unifocal/isolated VM**, lesions are predominantly cutaneous and mucosal, and rarely internal.

In **blue rubber bleb nevus (BRBN) syndrome**, affected individuals are often born with a large so-called dominant lesion, and numerous cutaneous and internal VM develop with time, with a predilection for the palms and soles. The VM in BRBN syndrome have a rubbery consistency with hyperkeratosis. Gastrointestinal lesions cause bleeding, iron deficiency, and intestinal complications (volvulus and infarction). Gastrointestinal VM are considered pathognomonic of BRBN syndrome.

### Laboratory Findings

Chronic consumptive coagulopathy (CCC) or localized intravascular coagulopathy (LIC) is frequent in *TEK*-related VM, ranging from 40% of individuals with isolated VM to more than 80% in individuals with MSVM, depending on the size and extent of the lesions [DompMartin et al 2008].

CCC/LIC is characterized by elevated D-dimer levels in the absence of other conditions associated with elevated D-dimers; levels of D-dimers are highly variable and can be more than three to five times the normal level (normal: <500 ng/mL).

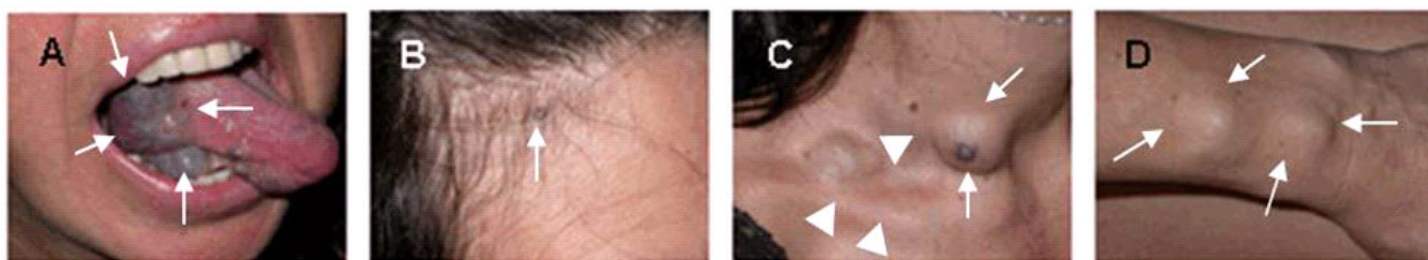Fibrinogen levels can be below the normal range (normal: 150-450 ng/mL) in cases of severe CCC/LIC. CCC/LIC is considered severe when high D-dimer levels ( $\geq 1,800$  ng/mL) are associated with low fibrinogen levels (<150 mg/dL).

Although not always present, CCC/LIC is pathognomonic of VM in general, and thus can help establish the diagnosis.

### Family History

A family history that is consistent with autosomal dominant inheritance (e.g., affected males and females in multiple generations) is suggestive of *TEK*-related VMCM. Absence of a known family history does not preclude the diagnosis.

Other *TEK*-related phenotypes (unifocal VM, MSVM, and BRBN syndrome) are caused by somatic (mosaic) pathogenic variants. Therefore, most probands represent a simplex case (i.e., a single occurrence in a family).



**Figure 1.** Multiple cutaneous and mucosal venous malformations (VMCM) (marked by arrows) in one affected individual

A. On the tongue

B. On the neck

C. In the supraclavicular area (scar of a resected VMCM, arrowheads)

D. On the distal forearm/wrist

## Establishing the Diagnosis

The diagnosis of *TEK*-related VM is **established** in a proband with suggestive findings and a heterozygous germline pathogenic (or likely pathogenic) variant in *TEK* (*TEK*-related VMCM) or a somatic pathogenic (or likely pathogenic) variant in *TEK* (unifocal VM, MSVM, and BRBN syndrome) identified by molecular genetic testing (see Table 1).

Note: (1) Per ACMG/AMP variant interpretation guidelines, the terms "pathogenic variant" and "likely pathogenic variant" are synonymous in a clinical setting, meaning that both are considered diagnostic and both can be used for clinical decision making [Richards et al 2015]. Reference to "pathogenic variant" in this section is understood to include any likely pathogenic variant. (2) Identification of a *TEK* variant of uncertain significance does not establish or rule out the diagnosis.

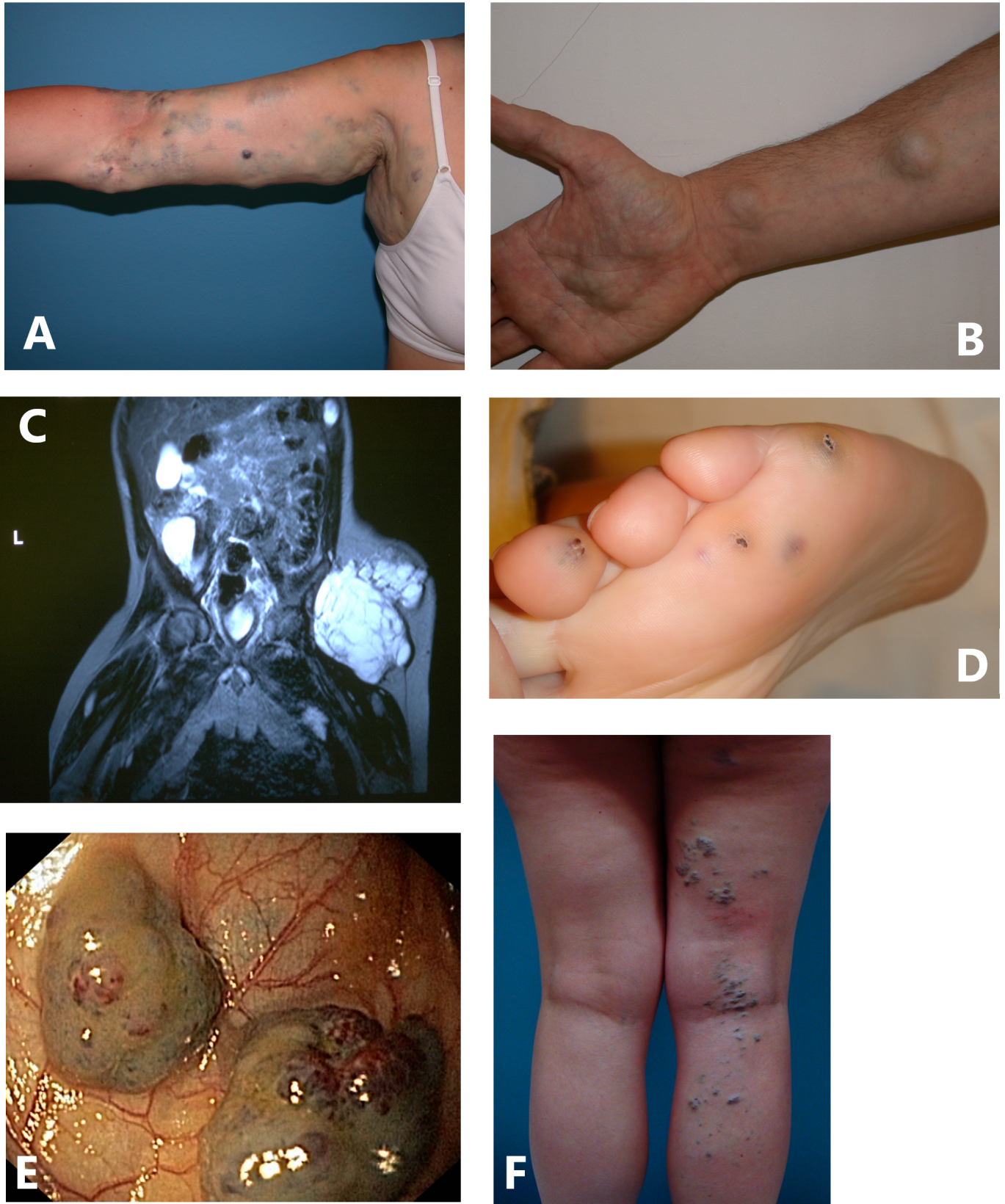
Molecular genetic testing approaches can include a combination of **gene-targeted testing** (single-gene testing, multigene panel) and **comprehensive genomic testing** (exome sequencing, genome sequencing) depending on the phenotype.

As many *TEK* pathogenic variants are postzygotic (or mosaic), deep sequencing as well as testing more than one tissue sample may need to be considered in the diagnostic workup of an affected individual.

Given the possibility of mosaicism, the following are considerations for molecular testing and sample selection:

- Sequence analysis of DNA derived from clinically affected tissue samples – preferably from the vascular lesion, requiring a surgical or skin biopsy – should be prioritized for genetic testing.
- The level of mosaicism for an activating *TEK* variant in affected tissues or cultured cells is highly variable. Variant allele fractions can be as low as 1% in some individuals.
- Testing peripheral blood or DNA isolated from blood alone is only recommended when a clear family history is present suggesting the diagnosis of *TEK*-related VMCM. In other instances, and as *TEK* pathogenic variants are often mosaic, testing vascular tissue is usually more helpful.

Gene-targeted testing requires that the clinician determines which gene(s) are likely involved, whereas genomic testing does not. Individuals with the distinctive findings described in Suggestive Findings are likely to be diagnosed using gene-targeted testing (see Option 1), whereas those with a phenotype indistinguishable from many other (inherited) disorders with vascular malformations are more likely to be diagnosed using genomic testing, if an appropriate sample is used (see Option 2).



**Figure 2.** Various venous malformations (VM)

Common sporadic VM of the arm (A); multifocal sporadic VM (MSVM) of the hand and forearm (B); in blue rubber bleb nevus (BRBN) syndrome, large "dominant" congenital VM of the buttock seen on MRI (C); multiple small and pathognomonic hyperkeratotic VM on sole (D); gastrointestinal VM (E); VM of the lower right extremity (F).

Note: On analysis of DNA derived from affected tissues, the method used for testing must be sensitive enough to detect low-level mosaicism of a pathogenic variant (see Molecular Pathogenesis).

## Option 1

When the phenotypic and laboratory findings suggest the diagnosis of *TEK*-related VM, molecular genetic testing approaches can include a **multigene panel** or **single gene** testing

- **A multigene panel** that includes *TEK*, *PIK3CA*, and other genes of interest (see Differential Diagnosis) on an appropriate sample is most likely to identify the genetic cause of the condition while limiting identification of variants of uncertain significance and pathogenic variants in genes that do not explain the underlying phenotype. Notes: (1) The genes included in the panel and the diagnostic sensitivity of the testing used for each gene vary by laboratory and are likely to change over time. (2) Some multigene panels may include genes not associated with the condition discussed in this *GeneReview*. (3) In some laboratories, panel options may include a custom laboratory-designed panel and/or custom phenotype-focused exome analysis that includes genes specified by the clinician. (4) Methods used in a panel may include sequence analysis, deletion/duplication analysis, and/or other non-sequencing-based tests.

For an introduction to multigene panels click [here](#). More detailed information for clinicians ordering genetic tests can be found [here](#).

- **Single-gene testing.** If the phenotype is highly suggestive, sequence analysis of *TEK* can be performed to detect missense, nonsense, splice site variants and small intragenic deletions/insertions. Note: (1) Mosaic pathogenic variants reported in *TEK* to date have been predominantly single-nucleotide variants associated with *TEK* gain of function, with no deletions/duplications detected in this spectrum. Therefore, gene-targeted deletion/duplication analysis is not recommended. (2) Failure to detect an activating *TEK* pathogenic variant does not exclude a diagnosis of *TEK*-related VM in individuals who meet the clinical diagnostic criteria, given that low-level mosaicism is observed in many affected individuals.

## Option 2

When the phenotype is indistinguishable from many other disorders characterized by VM, or if the individual has atypical features, **comprehensive genomic testing** on an appropriate sample can be performed to determine which gene is likely involved.

**Comprehensive genomic testing** does not require the clinician to determine which gene is likely involved. **Exome sequencing** is most commonly used; **genome sequencing** is also possible. Note: Given the high likelihood of mosaicism in vascular phenotypes, consideration needs to be given to obtaining deeper-coverage exome or genome sequencing. Experience suggests that the yield from these methods is improved with at least >500 times depth of coverage for exome sequencing, if available.

For an introduction to comprehensive genomic testing click [here](#). More detailed information for clinicians ordering genomic testing can be found [here](#).

**Table 1.** Molecular Genetic Testing Used in *TEK*-Related Venous Malformations

Gene <sup>1</sup>	Method	Proportion of Probands with a Pathogenic Variant <sup>2</sup> Detectable by Method
<i>TEK</i>	Sequence analysis <sup>3, 4</sup>	~100% <sup>5</sup>
	Deletion/duplication <sup>4</sup>	None detected <sup>4, 5</sup>

1. See Table A. Genes and Databases for chromosome locus and protein.

2. See Molecular Genetics for information on variants detected in this gene.

3. Sequence analysis detects variants that are benign, likely benign, of uncertain significance, likely pathogenic, or pathogenic. Variants may include small intragenic deletions/insertions and missense, nonsense, and splice site variants; typically, exon or whole-gene deletions/duplications are not detected. For issues to consider in interpretation of sequence analysis results, click [here](#).

4. Gene-targeted deletion/duplication analysis is not indicated as most identified pathogenic *TEK* variants to date are single-nucleotide variants.

5. Vikkula et al [1996], Calvert et al [1999], Wouters et al [2010], and data derived from the subscription-based professional view of Human Gene Mutation Database [Stenson et al 2020]

## Clinical Characteristics

### Clinical Description

*TEK*-related venous malformations (VM) encompass several phenotypes including isolated (or unifocal) VM, multifocal sporadic VM (MSVM), multiple cutaneous and mucosal VM (VMCM), and blue rubber bleb nevus (BRBN) syndrome.

**Table 2.** *TEK*-Related Venous Malformations: Comparison of Phenotypes by Select Features

Feature	Unifocal (Isolated) VM	MSVM	VMCM	BRBN Syndrome
<b>VM</b>	<ul style="list-style-type: none"> <li>Slow-flow blood vascular lesion</li> <li>Light-to-dark skin discoloration overlying soft, often compressible mass that develops primarily in cutaneous, subcutaneous, or mucosal tissues</li> </ul>	Light-to-dark skin discoloration overlying soft, often non-compressible mass that develops primarily in cutaneous, subcutaneous, or mucosal tissues		<ul style="list-style-type: none"> <li>Nipple-like bluish nodules w/rubbery consistency</li> <li>Tend to aggregate &amp; become hyperkeratotic w/ time</li> </ul>
<b>Proportion of VM</b>	>90% of VM	Rare; estimated to be ~1% of VM		
<b>Uni-/multifocal</b>	Unifocal	Multifocal		
<b>Location</b>	<ul style="list-style-type: none"> <li>40% on extremities</li> <li>40% on cervicofacial area</li> <li>20% on trunk</li> </ul>	<ul style="list-style-type: none"> <li>All over body</li> <li>Skin &amp; oral mucosa</li> <li>Rarely on palms &amp; soles</li> </ul>	<ul style="list-style-type: none"> <li>All over body</li> <li>Skin &amp; oral mucosa</li> <li>Rarely on palms &amp; soles</li> </ul>	<ul style="list-style-type: none"> <li>All over body</li> <li>Skin &amp; mucosa</li> <li>Predilection for palms &amp; soles</li> <li>Typically, large dominant lesion present at birth</li> </ul>
<b>Size</b>	Highly variable	<5 cm		<2 cm

Table 2. continued from previous page.

Feature	Unifocal (Isolated) VM	MSVM	VMCM	BRBN Syndrome
<b>GI lesions</b>	May or may not occur		Rare	<ul style="list-style-type: none"> <li>Multiple VM located in small intestines (pathognomonic)</li> <li>Can cause bleeding &amp; chronic anemia</li> <li>Complications incl intussusception, volvulus, &amp; intestinal infarction</li> </ul>
<b>Coagulopathy</b>	Approximately 40% of affected persons (depending on size & extent of lesion[s])		Common (≥80% of affected persons)	

BRBN = blue rubber bleb nevus; GI = gastrointestinal; MSVM = multifocal sporadic venous malformations; VM = venous malformation; VMCM = multiple cutaneous and mucosal venous malformations

1. For other causes of venous malformations, see Differential Diagnosis.

## Venous Malformations

*TEK*-related venous malformations (VM) include slow-flow venous lesions that appear as light-to-dark skin discoloration overlying a soft compressible mass and develop primarily in cutaneous, subcutaneous, or mucosal tissues. VM can affect any tissue or organ, including muscles, joints, viscera, and the central nervous system. They are usually present at birth. They grow and slowly expand over time [Dompmartin et al 2010]. Palpation can reveal pathognomonic phleboliths that develop due to long-standing localized thrombosis. Rapid expansion in the size of the lesions can be observed after trauma or hormonal modulation (e.g., during puberty or pregnancy).

Based on the focality (unifocal or multifocal) and the location of the lesions, there are several types of *TEK*-related VM.

**Unifocal (Isolated) VM.** The vast majority of VM are unifocal, developing as an isolated lesion, affecting any tissue or organ. Approximately 40% of VM occur on the extremities, 40% in the cervicofacial area, and 20% on the trunk. The clinical presentation is variable depending on the size, location, and mass effect on adjacent organs. The most frequent complications of unifocal VM include aesthetic deformation and chronic pain attributed to joint, tendon, or muscle involvement.

Depending on the organ or area involved, functional limitations range from muscle weakness and limb length discrepancy to difficulties feeding, speaking, and breathing, as well as physical deformities. Other symptoms include bleeding and, in combined venolymphatic malformations, recurrent infections and oozing. In some cases, VM can be life-threatening due to expansion or obstruction of vital structures such as the airways [Dompmartin et al 2010, Boon et al 2011a, Vogel et al 2013].

**Multiple cutaneous and mucosal VM (VMCM).** The most typical finding in VMCM is the presence of small multifocal cutaneous and/or oromucosal VM that are bluish in color [Wouters et al 2008, Dompmartin et al 2010, Wouters et al 2010, Boon et al 2011b, Boon & Vikkula 2012, Boon & Vikkula 2013]. The malformations range in size from 1 mm to 1 cm. Small millimetric lesions are usually asymptomatic but can cause cosmetic concern. They do not usually bleed or ulcerate. Larger lesions (up to a few centimeters in diameter) can invade subcutaneous muscles and cause pain. The size, number, and localization of lesions vary within and among families. Often one individual in a family has more extensive lesions than other family members; conversely, some family members may have only a few small and clinically insignificant lesions. These types of VM are randomly located throughout the body and affect the oral mucosa; in rare instances, they can affect the



gastrointestinal and/or anal mucosa [Vikkula et al 1996, Brouillard & Vikkula 2007, Wouters et al 2010, Boon & Vikkula 2012]. Malignant transformation has not been reported to date.

**Multifocal sporadic VM (MSVM).** MSVM represent a sporadic form of multifocal VM caused by pathogenic variants in *TEK*. MSVM is clinically very similar to VMCM, but without a family history of VM. Lesions are usually present as multiple small (<5 cm in diameter), raised lesions of various hues of blue involving the skin and oral mucosa and, occasionally, the subcutaneous tissues and skeletal muscles. MSVM are more frequently located in the cervicofacial area and extremities, typically have a hemispheric shape, are soft to touch, and are rarely emptied by external pressure. Due to their small size, they are usually asymptomatic [Soblet et al 2017].

**Blue rubber bleb nevus (BRBN) syndrome.** BRBN (also called Bean) syndrome is a rare congenital sporadically occurring disorder characterized by numerous, diffuse, cutaneous, and internal VM. Cutaneous VM in BRBN are characterized by small (<1-2 cm), dome-shaped, nipple-like bluish nodules with a rubbery consistency. They occur on any surface of the skin and mucosa and tend to aggregate and become hyperkeratotic, with a predilection for the palms and soles. Hundreds of lesions can be found over time. Affected individuals often have a congenital single large VM, a so-called dominant VM (>10 times the area of all other visible lesions), which represents the first manifestation of BRBN syndrome.

Gastrointestinal lesions (grape-like mucosal venous nodules), documented by endoscopy, colonoscopy, or magnetic resonance imaging, are pathognomonic of BRBN syndrome. These are commonly located in the small intestine and can cause hemorrhage, intussusception, volvulus, and intestinal infarction [Beluffi et al 2004, Ballieux et al 2015]. Bleeding from intestinal lesions causes chronic iron deficiency and anemia, requiring repeated iron supplementation or blood transfusions [Deshpande et al 2014, Wonaga et al 2014].

## Coagulopathy

All *TEK*-related VM, including unifocal VM, MSVM, VMCM, and BRBN syndrome, can present with chronic consumptive coagulopathy (CCC) and elevated D-dimer levels (normal: <500 ng/mL). Affected individuals with a VM frequently present with elevated D-dimer levels without any concurrent disease that may induce an increase in D-dimer levels. This elevation of D-dimers is observed in approximately 40% of individuals with isolated VM and in more than 80% of individuals with VMCM and BRBN syndrome. The elevated D-dimers in association with or without low fibrinogen levels (normal: 150-450 ng/mL) reflect a localized intravascular coagulopathy (LIC), which is pathognomonic of VM within vascular anomalies.

The palpation of phleboliths that develop due to stagnation of blood flow is also pathognomonic of VM. Normal D-dimer levels do not rule out a VM, as small VM may have limited intravascular clotting.

D-dimer levels are also helpful in differentiating between different types of VM, as more than 95% of individuals with multifocal glomuvenous malformations have normal D-dimer levels (see Differential Diagnosis) [Domp Martin et al 2008, Domp Martin et al 2010, Wouters et al 2010, Boon et al 2011b].

The risk of disseminated intravascular coagulopathy (DIC) caused by elevated D-dimer concentration is low unless the affected individual undergoes an intervention, such as a surgical procedure or sclerotherapy (see Treatment of Manifestations).

## Histologic Findings

Enlarged venous-like channels with walls of smooth muscle of variable thickness are observed in *TEK*-related VM [Vikkula et al 1996]. The endothelium is flattened but continuous. If rounded mural cells (glomus cells) are observed, the diagnosis is glomuvenous malformation [Boon et al 2004, Brouillard et al 2005, Brouillard et al 2008, Brouillard et al 2013] (see Differential Diagnosis).

## Genotype-Phenotype Correlations

The phenotypic spectrum of individuals with somatic pathogenic variants in *TEK* is broader than in individuals with germline pathogenic variants in *TEK*, as somatic mosaicism implies that the percentage, type, and location of cells affected by a pathogenic variant vary between affected individuals.

Some *TEK* pathogenic variants are more likely to be associated with a specific subtype of *TEK*-related VM. For example, c.2545C>T (p.Arg849Trp) is the most common variant detected in *TEK*-related VMCM, while c.2740C>T (p.Leu914Phe) is the most common variant detected in *TEK*-related unifocal VM and has not been observed in VMCM, MSVM, or BRBN syndrome [Vikkula et al 1996, Wouters et al 2010, Boon et al 2011a].

See the Molecular Pathogenesis section for information regarding types of genetic variants seen in different types of *TEK*-related venous malformations.

## Penetrance

Approximately 90% of individuals who have a germline pathogenic gain-of-function variant in *TEK* (*TEK*-related VMCM) develop mucocutaneous VM by age 20 years; conversely, approximately 10% of individuals with a germline pathogenic gain-of-function variant in *TEK* are clinically unaffected [Boon et al 2004, Wouters et al 2010]. Reduced penetrance can be explained by the need to acquire a second, somatic pathogenic gain-of-function variant either in the normal allele or the allele with the pathogenic variant, or loss of the normal allele, in the target cell(s) in order to develop a lesion(s) [Limaye et al 2009, Soblet et al 2017].

The penetrance of other *TEK*-related phenotypes (unifocal VM, MSVM, BRBN syndrome) is currently unknown. It is hard to estimate, as many *TEK* pathogenic variants may elude detection due to mosaicism. Data suggest that pathogenic variants in *TEK* are sufficient to cause the phenotype, but some individuals with pathogenic variants in more than one gene (e.g., *TEK* and *PIK3CA*) have been described [M Vikkula, personal communication].

## Nomenclature

The title of this *GeneReview*, *TEK*-related venous malformations (VM), is based on the dyadic naming approach proposed by Biesecker et al [2021] to delineate mendelian genetic disorders. Therefore, this term encompasses all known *TEK*-related VM phenotypes reported to date, including multiple cutaneous and mucosal VM (VMCM), multifocal sporadic VM (MSVM), unifocal (isolated) VM, and blue rubber bleb nevus (BRBN) syndrome.

Terms used previously to describe VM include "cavernous angioma" and "cavernous hemangioma." The term "mucocutaneous venous malformation" was coined by Boon et al [1994] for the lesions identified in a large multigenerational family from the United States in which the *TEK* locus was first identified.

## Prevalence

VM are often considered the most common subtype of vascular malformations seen in specialty clinics, with an incidence between 1:2,000 and 1:5,000 live births. More than 90% of VM are sporadic and isolated [Wassef et al 2015].

Although unknown, the prevalence of *TEK*-related VM, such as MSVM, VMCM and BRBN syndrome, remains much lower than sporadic unifocal VM; VMCM is estimated to account for fewer than 1% of individuals with venous anomalies followed in multidisciplinary centers specializing in vascular anomalies [Boon et al 2004]. BRBN syndrome is rarely reported, with around 250 individuals reported to date [Soblet et al 2017]. The low incidence of these phenotypes could be due to their rarity or underdiagnosis.

## Genetically Related Disorders

**Bockenheimer disease** is a VM involving most of the length of an extremity and affecting all tissue planes, from the skin to the bone. This progressive disease causes significant morbidity, including pain, swelling, discoloration, ulceration, bleeding, localized intravascular coagulopathy, pathologic fractures, and functional limitations [Kubiena et al 2006]. In a small series of nine individuals with Bockenheimer disease, the *TEK* variant c.2740C>T (p.Leu914Phe) was identified in all affected individuals [Ali et al 2020].

**Primary congenital glaucoma.** Heterozygous germline loss-of-function pathogenic variants in *TEK* are known to be associated with primary congenital glaucoma.

## Differential Diagnosis

**Table 3.** Genes of Interest in the Differential Diagnosis of *TEK*-Related Venous Malformations

Gene	Disorder	MOI	Phenotype	Comment
<i>GLMN</i>	Glomuvenous malformations (OMIM 138000)	AD <sup>1, 2</sup>	<p>Similar to VMCM:</p> <ul style="list-style-type: none"> <li>Inherited</li> <li>Multifocal</li> <li>Small cutaneous venous-like lesions</li> <li>Most lesions located on extremities</li> </ul> <p>Unlike VMCM:</p> <ul style="list-style-type: none"> <li>Not usually seen on mucous membranes</li> <li>Cobblestone appearance</li> </ul>	<ul style="list-style-type: none"> <li>Deeper purple in color than VMCM</li> <li>Painful on palpation</li> <li>Less invasive than sporadic VM</li> </ul>
<i>PIK3CA</i>	<i>PIK3CA</i> -related vascular malformations (See <a href="#">PIK3CA-Related Overgrowth Spectrum</a> .)	Mosaic (not known to be inherited) <sup>3</sup>	<ul style="list-style-type: none"> <li>GoF of <i>PIK3CA</i> in 20% of isolated VM</li> <li><i>PIK3CA</i>-mutated VM do not typically extend to cutaneous surface.</li> </ul>	A pathogenic variant in <i>PIK3CA</i> is observed in various <i>PIK3CA</i> -related overgrowth syndromes, in which combined vascular malformations are assoc w/ hypertrophy of soft tissues & often involve the skeleton.
<i>KRIT1 (CCM1)</i> <i>CCM2</i> <i>CCM3</i>	Cerebral cavernous malformation (CCM) (OMIM 116860)	Sporadic or AD (20% of CCM) <sup>4</sup>	<ul style="list-style-type: none"> <li>9% of persons w/CCM have cutaneous vascular malformations, incl nodular cutaneous VM</li> <li>Single or multiple nodules, typically all over body</li> <li>Most lesions are not present at birth, &amp; new lesions may emerge into adulthood.</li> <li>Size ranges from 1 mm to &lt;5 cm.</li> </ul>	<ul style="list-style-type: none"> <li>CCM affects up to 0.5% of population.</li> <li>Vascular lesions typically arise in central nervous system.</li> <li>CCM usually manifests between age 20-30 years, but clinical manifestations can occur at any age.</li> </ul>

Table 3. continued from previous page.

Gene	Disorder	MOI	Phenotype	Comment
<i>MAP3K3</i>	Verrucous VM (VVM)	Mosaic (not known to be inherited) <sup>5</sup>	<ul style="list-style-type: none"> <li>VVM present at birth or early during infancy.</li> <li>Most commonly affecting lower limbs</li> <li>Well-circumscribed purple &amp; hyperkeratotic linear plaques</li> <li>Size ranges from 2 to 20 cm.</li> </ul>	Very similar lesions, called hyperkeratotic cutaneous capillary-venous malformations (HCCVM), can occur in CCM, mostly in CCM1.

GoF = gain of function; VM = venous malformations; VMCM = multiple cutaneous and mucosal venous malformations

1. Inheritance is autosomal dominant, although the pathophysiologic mechanism is recessive at the cellular level (i.e., disease caused by presence of a germline pathogenic variant on one allele and an acquired somatic pathogenic variant on the other allele), most frequently due to an acquired uniparental isodisomy [Brouillard et al 2002, Amyere et al 2013].

2. Boon et al [2004], Mallory et al [2006], Brouillard et al [2013]

3. Limaye et al [2015]

4. Sirvente et al [2009], Ren et al [2021]

5. Couto et al [2015]

## Management

No clinical practice guidelines for *TEK*-related venous malformations (VM) have been published. However, diagnostic and management recommendations have been proposed by the European Reference Network on Rare Multisystemic Vascular Diseases (VASCERN) [DompMartin et al 2023] ([full text](#)).

## Evaluations Following Initial Diagnosis

To establish the extent of disease and management needs in an individual diagnosed with *TEK*-related VM, the evaluations summarized in Table 4 (if not performed as part of the evaluation that led to the diagnosis) are recommended.

**Table 4.** Recommended Evaluations Following Initial Diagnosis in Individuals with *TEK*-Related Venous Malformations

System/Concern	Evaluation	Comment
<b>Isolated VM</b>	<ul style="list-style-type: none"> <li>Eval by vascular anomalies specialist</li> <li>MRI of affected area</li> </ul>	To evaluate extension into underlying tissue when planning mgmt <sup>1</sup>
<b>Multifocal VM</b>	<ul style="list-style-type: none"> <li>Eval by vascular anomalies specialist</li> <li>Consider whole-body MRI.</li> </ul>	To evaluate risk of internal lesions
<b>Gastrointestinal VM</b>	Endoscopic eval & abdominal imaging	To evaluate risk of bleeding, obstruction, involvement, occlusion
<b>Coagulopathy</b>	<ul style="list-style-type: none"> <li>D-dimer level</li> <li>Fibrinogen level</li> </ul>	To evaluate risk for CCC or LIC <sup>2</sup>
<b>Genetic counseling</b>	By genetics professionals <sup>3</sup>	To inform affected persons & their families re nature, MOI, & implications of <i>TEK</i> -related VM to facilitate medical & personal decision making

Table 4. continued from previous page.

System/Concern	Evaluation	Comment
<b>Family support &amp; resources</b>	Assess need for: <ul style="list-style-type: none"> <li>• Community or online resources such as <a href="#">Parent to Parent</a>;</li> <li>• Social work involvement for parental support;</li> <li>• Home nursing referral.</li> </ul>	

CCC = chronic consumptive coagulopathy; LIC = localized intravascular coagulopathy; MRI = magnetic resonance imaging; MOI = mode of inheritance; VM = venous malformations

1. Domp Martin et al [2010], Boon et al [2011b], Boon & Vikkula [2012]

2. Domp Martin et al [2008]

3. Medical geneticist, certified genetic counselor, certified advanced genetic nurse

## Treatment of Manifestations

Treatment is required for any symptomatic VM. Management depends largely on the size and location of the lesions. Small lesions can be surgically resected or treated with sclerotherapy with very favorable outcomes (often complete cure). However, in many instances complete resection or embolization is not possible.

If affected individuals are asymptomatic, with no lesion that may cause severe or life-threatening complications (e.g., medullary compression, pathologic bone fracture, airway compression), it is preferable to delay any therapeutic intervention and clinically monitor the individual over time.

Treatment of *TEK*-related VM ideally involves multidisciplinary care by specialists in vascular anomalies, interventional radiology, surgery, oncology, hematology, and genetics (see Table 5).

Table 5. Treatment of Manifestations in Individuals with *TEK*-Related Venous Malformations

Manifestation/Concern	Treatment	Considerations/Other
<b>VM</b>	Sclerotherapy (treatment of choice); foam aethoxysclerol & bleomycin are preferentially used as sclerosing agents	<ul style="list-style-type: none"> <li>• Mgmt depends largely on size &amp; location of lesion(s).</li> <li>• Although sclerotherapy is the treatment of choice, sclerosing agents are not specific &amp; can lead to ulceration if the VM is mucosal or involves the epidermis. <sup>1</sup></li> </ul>
	Surgical resection	<ul style="list-style-type: none"> <li>• More effective for well delineated &amp;/or small lesions</li> <li>• For large VM, surgical resection gives better long-term result if performed after sclerotherapy.</li> </ul>
	Sirolimus <sup>2</sup> (See Table 6 & Targeted Off-label Therapies.)	May be considered in persons w/VM that are refractory to sclerotherapy &/or surgery, or in persons who are ineligible for surgery/sclerotherapy
<b>GI lesions</b>	<ul style="list-style-type: none"> <li>• Iron replacement or transfusions in case of anemia from chronic bleeding</li> <li>• Other treatment options incl endoscopic sclerotherapy, band ligation, laser photocoagulation, &amp; surgical resection.</li> </ul>	Sirolimus (see Targeted Off-label Therapies) significantly ↓s bleeding in cases of VM & BRBN syndrome.

Table 5. continued from previous page.

Manifestation/Concern	Treatment	Considerations/Other
<b>Coagulopathy</b>	<p>Low-molecular-weight heparin (LMWH):</p> <ul style="list-style-type: none"> <li>If D-dimers are ↑ &amp; fibrinogen levels are low, LMWH should be initiated 1-2 weeks before surgery, depending on severity of coagulation abnormality, &amp; continued for 2 weeks after surgery to reduce pre- and post-operative bleeding.</li> <li>If fibrinogen levels are normal, LMWH can be initiated the day before surgery.</li> <li>If lesions are painful &amp; D-dimers are ↑ (higher than 2x normal range), LMWH can be used to alleviate pain.<sup>3</sup></li> </ul>	<ul style="list-style-type: none"> <li>Should be administered prior to any invasive procedure (i.e., surgery &amp;/or sclerotherapy) to ↓ risk of DIC.</li> <li>D-dimer levels can be used to evaluate efficacy of sclerotherapy &amp; LMWH treatments, as levels will ↓ w/reduction of lesion size.</li> </ul>
<b>Family/Community</b>	<ul style="list-style-type: none"> <li>Ensure appropriate social work involvement to connect families w/local resources, despite, &amp; support.</li> <li>Coordinate care to manage multiple subspecialty appointments, equipment, medications, &amp; supplies.</li> </ul>	<ul style="list-style-type: none"> <li>Ongoing assessment of need for palliative care involvement and/or home nursing</li> <li>Consider involvement in adaptive sports or Special Olympics.</li> </ul>

DIC = disseminated intravascular coagulopathy; GI = gastrointestinal; LMWH = low-molecular-weight heparin; VM = venous malformation(s)

1. Hammer et al [2001], Domp martin et al [2010], Boon et al [2011b]

2. Sirolimus has not been approved by the FDA or EMA for the treatment of VM, and thus despite its efficacy it remains an off-label treatment to date.

3. Domp martin et al [2008]

## Sclerotherapy and Surgery

Sclerotherapy is the first-line treatment for VM. It is performed to decrease the volume of the VM before surgery or as monotherapy in individuals in whom surgery is not technically feasible.

If the lesion is small and complete resection is possible without anatomic or functional consequences, surgical excision should be performed as the treatment of choice. However, these approaches have limitations, including inaccessibility and failure to completely cure the VM.

## Targeted Off-label Therapies

**MTOR inhibitors.** Small molecule inhibitors are an emerging line of therapy in many disorders. In recent years, multiple trials have reported on the efficacy of using mammalian target of rapamycin (MTOR) inhibitors, including sirolimus, in the treatment of slow-flow vascular malformations (see Table 6 and Therapies Under Investigation).

Sirolimus has been shown to reduce pain and functional limitations due to VM [Boscolo et al 2015, Adams et al 2016, Hammer et al 2018, Ji et al 2021, Maruani et al 2021], as well as improve gastrointestinal bleeding in BRBN syndrome, with fast recovery of hemoglobin levels. It is therefore currently considered the best therapeutic option when there is multiorgan involvement in BRBN syndrome [Zhou et al 2021].

**Table 6.** Targeted Off-label Treatment of *TEK*-Related Venous Malformations

Treatment	Starting Daily Dosage	Indication
<b>Sirolimus</b> <sup>1, 2</sup>	<ul style="list-style-type: none"> <li>Adults: 2 mg 1x/day</li> <li>Children age &lt;18 yrs: 0.8 mg/m<sup>2</sup> 2x/day</li> </ul> <p>These dosages must be adapted based on tolerance, efficacy, &amp; serum levels.</p>	<ul style="list-style-type: none"> <li>Persons w/VM who are refractory to sclerotherapy &amp;/or surgery, or for persons who are ineligible for surgery &amp;/or sclerotherapy.</li> <li>Sirolimus has been shown to ↓ pain, improve quality of life &amp; functional limitations, &amp; ↓ bleeding.</li> </ul>

VM = venous malformations

1. The decision to treat VM using sirolimus should be initiated by a vascular anomalies expert.

2. Sirolimus has not been approved by the FDA or EMA for the treatment of VM, and thus despite its efficacy remains an off-label treatment. A large prospective Phase III trial (VASE) studying the efficacy of sirolimus in VM is ongoing. Side effects with sirolimus therapy have been reported in many individuals. For details, see Therapies Under Investigation.

## Surveillance

To monitor existing manifestations of *TEK*-related VM, the individual's response to treatment, and the emergence of new manifestations, the evaluations in Table 7 are recommended.

**Table 7.** Recommended Surveillance for Individuals with *TEK*-Related Venous Malformations

System/Concern	Evaluation	Frequency
<b>VM</b>	Eval by vascular anomalies specialist	<ul style="list-style-type: none"> <li>Annually or as needed (esp around puberty or other hormonal changes, as VM can become painful)</li> <li>Lesions can ↑ in size over time &amp; become painful or symptomatic.</li> </ul>
<b>GI lesions</b>	<ul style="list-style-type: none"> <li>CBC incl Hgb &amp; hematocrit level</li> <li>Iron levels (incl serum iron, serum ferritin, &amp; transferrin levels)</li> <li>Endoscopy</li> </ul>	<ul style="list-style-type: none"> <li>Annually or more frequently in case of symptoms (fatigue, bloody stools)</li> <li>Consider endoscopy based on blood results.</li> </ul>
<b>Coagulopathy/Bleeding</b>	D-dimer & fibrinogen levels	<p>Should be checked:</p> <ul style="list-style-type: none"> <li>Every 5 yrs;</li> <li>If lesions become painful;</li> <li>Before any surgical &amp;/or sclerotherapeutic procedure.</li> </ul>
<b>Treatment w/sirolimus</b>	See Table 8.	See Table 8.

CBC = complete blood count; GI = gastrointestinal; Hgb = hemoglobin; VM = venous malformations

For individuals on MTOR inhibitor therapy such as sirolimus, a targeted off-label therapy, several surveillance guidelines are recommended (see Table 8).

**Table 8.** Recommended Surveillance: Targeted Off-label Therapy for *TEK*-Related Venous Malformations

Treatment	Evaluation	Frequency
<b>Sirolimus</b> <sup>1, 2</sup>	Eval by vascular anomalies specialist	<ul style="list-style-type: none"> <li>Based on the VASE study (see Therapies Under Investigation), persons should be evaluated every mo for 1st 3 mos to adjust daily dosage, &amp; then every 3 mos for duration of treatment.</li> <li>The optimal treatment duration is at treating clinician's discretion. After 2 yrs of treatment, frequency of consultation is at treating clinician's discretion.</li> </ul>
	Eval for dose modification in case of adverse events	
	Laboratory tests: <ul style="list-style-type: none"> <li>Hemogram (Hgb, leukocytes, platelets)</li> <li>Thyroid function tests (TSH, T4) to exclude reversible causes of fatigue</li> <li>Cholesterol level</li> <li>Fasting blood glucose level</li> <li>Renal function tests</li> <li>Liver function tests</li> </ul>	

Hgb = hemoglobin; T4 = thyroxine; TSH = thyroid-stimulating hormone

1. The decision to treat VM using sirolimus should be initiated by a vascular anomalies expert.

2. Sirolimus has not been approved by the FDA or EMA for treatment of VM, and thus despite its efficacy remains an off-label therapy. A large prospective Phase III trial (VASE) studying the efficacy of sirolimus in VM is ongoing (see Therapies Under Investigation).

## Agents/Circumstances to Avoid

Contraceptive pills with high estrogen concentration should be avoided, as VM are estrogen responsive. VM can increase in size and become symptomatic, especially at the initiation of estrogen-based contraception. In some but not all instances stabilization of a VM lesion and diminution of pain may be observed after three months of contraceptive pill use.

## Evaluation of Relatives at Risk

**Relatives of a proband with inherited *TEK*-related VM or VMCM.** Evaluating at-risk neonates by physical examination is appropriate to identify those who may benefit from early treatment.

Lesions arising after infancy usually stay small and therefore are rarely symptomatic. If no lesions are seen at birth, a second evaluation should be done around puberty.

Once a germline *TEK* pathogenic variant has been identified in the family, molecular genetic testing can be used to evaluate at-risk relatives.

See Genetic Counseling for issues related to testing of at-risk relatives for genetic counseling purposes.

## Pregnancy Management

During pregnancy, affected women may develop new small lesions; in addition, existing lesions may increase in size and become painful.

If D-dimer levels are high, low-molecular-weight heparin may be used to alleviate pain.

D-dimer levels should be evaluated every one to three months during pregnancy depending on the symptoms and before delivery to adjust medication and avoid abnormal bleeding during delivery.

In individuals on sirolimus, avoiding pregnancy and lactation is recommended, as this drug is classified as an FDA category C drug in pregnancy and lactation.

See [MotherToBaby](#) for further information on medication use during pregnancy.



## Therapies Under Investigation

In recent years, multiple trials have reported on the efficacy of MTOR inhibitors in the treatment of slow-flow vascular malformations. A pilot study on rapamycin therapy for venous malformations (VM) reported beneficial results, especially regarding pain reduction and improvement in quality of life [Boscolo et al 2015]. Several Phase II trials showed improvement in symptoms such as pain, bleeding, and functional limitation and improvement in quality of life [Boscolo et al 2015, Adams et al 2016, Hammer et al 2018, Ji et al 2021, Maruani et al 2021].

A prospective multicentric Phase III trial (VASE) is currently evaluating the efficacy and safety of sirolimus in slow-flow vascular anomalies that are refractory to standard care (NCT02638389). This study started in January 2016 and has enrolled the intended 250 patients (as of January 2023). In the VASE trial, enrolled individuals receive sirolimus for two years at a starting daily dose of 2 mg for adults and 0.8 mg/m<sup>2</sup> twice daily for children younger than age 18 years. Individuals are evaluated every month for three months and then every three months for the treatment duration. Sirolimus is discontinued after two years and can be reintroduced in case of symptom recurrence. Preliminary results from the first 132 enrolled individuals (including 76 with VM) who were followed for at least 12 months showed that 87% of had less pain and functional limitation [Seront et al, unpublished data].

Adverse events were frequent, occurring in 96% of individuals receiving sirolimus therapy, but were most commonly mild, with the majority being grade 1 and 2 in severity and thus easily manageable. The most common toxicities were asthenia (70% grade 1-2, 4% grade 3-4), mucositis (66% grade 1-2, 8% grade 3-4), diarrhea (40% grade 1-2, 2% grade 3-4), headache (25% grade 1-2, 5% grade 3-4), cutaneous rash (31% grade 1-2, 1% grade 3-4), and pyrosis (21% grade 1-2, 0% grade 3-4). These results are consistent with other previous reports, highlighting the efficacy and safety of sirolimus in VM [Seront et al, unpublished data]. Sirolimus has also shown to improve gastrointestinal bleeding in BRBN syndrome, with fast recovery of hemoglobin levels, and is currently considered the best therapeutic option when there is multiorgan involvement in BRBN syndrome [Zhou et al 2021].

Search [ClinicalTrials.gov](https://clinicaltrials.gov) in the US and [EU Clinical Trials Register](https://clinicaltrialsregister.eu) in Europe for access to information on clinical studies for a wide range of diseases and conditions.

## Genetic Counseling

*Genetic counseling is the process of providing individuals and families with information on the nature, mode(s) of inheritance, and implications of genetic disorders to help them make informed medical and personal decisions. The following section deals with genetic risk assessment and the use of family history and genetic testing to clarify genetic status for family members; it is not meant to address all personal, cultural, or ethical issues that may arise or to substitute for consultation with a genetics professional. —ED.*

## Mode of Inheritance

TEK-related venous malformations (VM) include:

- The autosomal dominant disorder multiple cutaneous and mucosal venous malformations (VMCM), caused by germline heterozygous *TEK* pathogenic variants;
- The sporadic (or mosaic) disorders unifocal/isolated VM, multifocal sporadic VM (MSVM), and blue rubber bleb nevus (BRBN) syndrome, caused by postzygotic (mosaic) *TEK* pathogenic variants.

Molecular genetic testing of leukocyte DNA from the proband is necessary to distinguish between these categories of *TEK*-related VM and to establish reliable recurrence risk.

## VMCM – Risk to Family Members

### Parents of a proband

- Most individuals diagnosed with VMCM have an affected parent.
- To date, VMCM caused by a *de novo* germline *TEK* pathogenic variant has not been reported.
- If the proband appears to be the only affected family member (i.e., neither parent of the proband has clinical evidence of VMCM on dermatologic evaluation), molecular genetic testing is recommended for the parents of the proband to confirm their genetic status and to allow reliable recurrence risk counseling.
- If the pathogenic variant identified in the proband is not identified in either parent and parental identity testing has confirmed biological maternity and paternity, the following possibilities should be considered:
  - The proband has a *de novo* pathogenic variant.
  - The proband inherited a pathogenic variant from a parent with germline (or somatic and germline) mosaicism. Note: Testing of parental leukocyte DNA may not detect all instances of somatic mosaicism and will not detect a pathogenic variant that is present in the germ cells only.
- The family history of some individuals diagnosed with VMCM may appear to be negative because of a milder phenotypic presentation, reduced penetrance, early death of the parent before the onset of symptoms, or late onset of the disease in the affected parent. Therefore, an apparently negative family history cannot be confirmed unless molecular genetic testing has demonstrated that neither parent is heterozygous for the *TEK* pathogenic variant that was identified in the proband.

**Sibs of a proband.** The risk to the sibs of the proband depends on the genetic status of the proband's parents:

- If a parent of the proband is affected and/or known to have the *TEK* pathogenic variant identified in the proband, the risk to the sibs of inheriting the pathogenic variant is 50%.
  - Approximately 90% of individuals who inherit a germline pathogenic gain-of-function variant in *TEK* develop mucocutaneous venous malformations by age 20 years (see Penetrance).
  - The size, number, and localization of lesions vary between family members with the same *TEK* pathogenic variant. Often one individual in a family has more extensive lesions than other family members; conversely, some family members may have only a few small, clinically insignificant lesions.
- If the *TEK* pathogenic variant identified in the proband cannot be detected in the leukocyte DNA of either parent, the recurrence risk to the sibs is estimated to be 1% because of the theoretical possibility of parental gonadal mosaicism [Rahbari et al 2016].
- If the parents have not been tested for the *TEK* pathogenic variant but are clinically unaffected, sibs of a proband are still at increased risk for VMCM because of the possibility of reduced penetrance in a parent (10% of individuals with a *TEK* pathogenic variant will not have findings of VMCM) and the theoretic possibility of parental germline mosaicism.

**Offspring of a proband.** Each child of an individual with VMCM has a 50% chance of inheriting the *TEK* pathogenic variant.

**Other family members.** The risk to other family members depends on the status of the proband's parents: if a parent has the *TEK* pathogenic variant, the parent's family members may be at risk.

## Unifocal VM, MSVM, and BRBN Syndrome – Risk to Family Members

**Parents of a proband.** Parents of children with a postzygotic (mosaic) *TEK* pathogenic variant(s) have not been reported to have any significant distinctive manifestations of the disorder, nor would such findings be expected given the somatic nature of these genetic alterations.

**Sibs of a proband.** Given the somatic mutational mechanism of *TEK*-related unifocal VM, MSVM, and BRBN syndrome, the risk for an affected sib would be expected to be the same as in the general population.

**Offspring of a proband.** There are no instances of vertical transmission of *TEK*-related unifocal VM, MSVM, or BRBN syndrome.

**Other family members.** The risk to other family members is the same as that in the general population.

## Related Genetic Counseling Issues

See Management, Evaluation of Relatives at Risk for information on evaluating at-risk relatives of a proband with *TEK*-related VMCM for the purpose of early diagnosis and treatment.

**Considerations in families with an apparent postzygotic (mosaic) *TEK* pathogenic variant(s).** Counseling for recurrence risk in *TEK*-related unifocal VM, MSVM, and BRBN syndrome should emphasize that, while no pregnancy is at zero risk, all evidence suggests that the risk of recurrence for these disorders is not increased compared to the general population.

### Family planning

- The optimal time for determination of genetic risk is before pregnancy.
- It is appropriate to offer genetic counseling (including discussion of potential risks to offspring and reproductive options) to young adults who are affected.

## Prenatal Testing and Preimplantation Genetic Testing

### VMCM

- **Molecular genetic testing.** Once a germline heterozygous *TEK* pathogenic variant has been identified in a family member with VMCM, prenatal and preimplantation genetic testing are possible.
- **Imaging studies.** Prenatal diagnosis of VMCM using imaging studies such as Doppler ultrasonography and/or MRI has not been reported. The number and size of fetal lesions are variable and unpredictable. Doppler ultrasonography may be used to evaluate for fetal lesions in those fetuses at increased risk for VMCM, but the small size of the lesions makes them difficult to detect.

**Unifocal VM, MSVM, and BRBN syndrome.** As these disorders are not inherited, prenatal testing is not indicated.

Differences in perspective may exist among medical professionals and within families regarding the use of prenatal testing. While most centers would consider use of prenatal testing to be a personal decision, discussion of these issues may be helpful.

## Resources

*GeneReviews staff has selected the following disease-specific and/or umbrella support organizations and/or registries for the benefit of individuals with this disorder and their families. GeneReviews is not responsible for the information provided by other organizations. For information on selection criteria, click [here](#).*

- **Foundation for Faces of Children**  
**Phone:** 617-355-8299  
**Email:** [info@facesofchildren.org](mailto:info@facesofchildren.org)  
[Vascular Malformations](#)
- **MedlinePlus**  
[Multiple cutaneous and mucosal venous malformations](#)

- **European Reference Network on Rare Multisystemic Vascular Diseases (VASCERN)**  
**Email:** [contact@vascern.eu](mailto:contact@vascern.eu)  
[VASCERN Patient Group \(ePAG\)](#)
- **International Society for the Study of Vascular Anomalies (ISSVA)**  
ISSVA list of Multidisciplinary Centers  
[Find a Multidisciplinary Team](#)
- **International Society for the Study of Vascular Anomalies (ISSVA)**  
ISSVA list of Patient Advocacy Organizations  
[Patient Advocacy Organizations](#)
- **Vascular Anomaly Patient Association (VASCAPA)**  
Belgium  
**Email:** [info@vascapa.org](mailto:info@vascapa.org)  
[www.vascapa.org](http://www.vascapa.org)

## Molecular Genetics

*Information in the Molecular Genetics and OMIM tables may differ from that elsewhere in the GeneReview: tables may contain more recent information.* —ED.

**Table A.** TEK-Related Venous Malformations: Genes and Databases

Gene	Chromosome Locus	Protein	Locus-Specific Databases	HGMD	ClinVar
<a href="#">TEK</a>	<a href="#">9p21.2</a>	<a href="#">Angiotensin-1 receptor</a>	<a href="#">TEK database</a>	<a href="#">TEK</a>	<a href="#">TEK</a>

Data are compiled from the following standard references: gene from [HGNC](#); chromosome locus from [OMIM](#); protein from [UniProt](#). For a description of databases (Locus Specific, HGMD, ClinVar) to which links are provided, click [here](#).

**Table B.** OMIM Entries for TEK-Related Venous Malformations ([View All in OMIM](#))

<a href="#">600195</a>	<a href="#">VENOUS MALFORMATIONS, MULTIPLE CUTANEOUS AND MUCOSAL; VMCM</a>
<a href="#">600221</a>	<a href="#">TEK TYROSINE KINASE, ENDOTHELIAL; TEK</a>

## Molecular Pathogenesis

*TEK* encodes the angiotensin-1 receptor (TIE2), a dimeric receptor tyrosine kinase mostly expressed on vascular endothelial cells. TIE2 binds the ligands angiotensin 1, 2, and 4. Binding of growth factors, such as angiotensin 1 (ANGPT1), results in TIE2 phosphorylation, which leads to activation of the canonical phosphatidylinositol-3 kinase (PI3K) / protein B (AKT) / mammalian target of rapamycin (mTOR) signaling pathway. Its function is important for endothelial cell proliferation, survival, and migration during angiogenesis, and later for vascular stability.

Most *TEK* pathogenic variants associated with venous malformations (VM) are located within the kinase domain and cause a gain of function that in turn causes ligand-independent increased phosphorylation, activating the PI3K-AKT-FOXO1 pathway and leading to reduced PDGF-beta production [Uebelhoer et al 2013]. STAT1 signaling is also activated [Korpelainen et al 1999, Limaye et al 2009, Boon et al 2011b]. Loss of the normal allele at the cellular level (i.e., presence of a germline gain-of-function pathogenic variant on one allele and an acquired somatic pathogenic event on the other allele) may be the mechanism of disease in *TEK*-related multiple cutaneous and mucosal VM (VMCM), as demonstrated by the somatic "second hit" identified in one VMCM tissue [Limaye et al 2009, Soblet et al 2017]. Other *TEK*-associated phenotypes, including multifocal

sporadic VM (MSVM), unifocal VM, and blue rubber bleb nevus (BRBN) syndrome are caused by mosaic variants in *TEK* (see Table 9). While sporadic or isolated VM need only one variant to develop, MSVM and BRBN syndrome most often contain two somatic variants in *TEK*.

Although all VM-associated *TEK* pathogenic variants result in ligand-independent phosphorylation of TIE2, the levels of hyperphosphorylation of germline and somatic variants are variable [Wouters et al 2010], which may contribute to the significant intra- and interfamilial variability. Uebelhoer et al [2013] and Nätyнки et al [2015] have reported that TIE2 phosphorylation, localization, trafficking, and cellular phenotype differ by variant type.

Gain-of-function mutations in *TEK* are detected in the majority of sporadically occurring unifocal and multifocal VM (unifocal VM and MSVM, respectively) and in BRBN syndrome, as well as in inherited VMCM (see [GeneReview Scope](#)).

**Table 9.** *TEK*-Related Venous Malformations: Molecular Pathogenesis

Phenotype	Types of genetic variants
<b>VMCM</b>	Germline (inherited) pathogenic <i>TEK</i> variant in addition to a somatic (mosaic) pathogenic variant <sup>1, 2</sup>
<b>MSVM</b>	Double pathogenic variants. <sup>3</sup> Affected persons typically acquire an initial mosaic activating pathogenic <i>TEK</i> variant & subsequently acquire a second mosaic activating pathogenic variant (or a "second hit"). The second pathogenic variant may vary among lesions from the same person.
<b>Unifocal VM</b>	In ~60% of affected persons, isolated VM are caused by a somatic pathogenic variant in <i>TEK</i> . <sup>2</sup>
<b>BRBN syndrome</b>	Unlike VMCM-causing pathogenic variants, BRBN syndrome-causing pathogenic variants typically occur on the same allele (i.e., double [ <i>cis</i> ] pathogenic variants [>83%]). The same double ( <i>cis</i> ) pathogenic variants are seen in multiple lesions from the same person, suggesting a common cellular ancestor for the lesion. <sup>3</sup>

BRBN = blue rubber bleb nevus; MSVM = multifocal sporadic venous malformations; VM = venous malformation; VMCM = multiple cutaneous and mucosal venous malformations

1. Wouters et al [2010]

2. Limaye et al [2009], Soblet et al [2013]

3. Soblet et al [2017]

### **Mechanism of disease causation.** Gain of function

***TEK*-specific laboratory technical considerations.** Both germline and mosaic variants are seen in *TEK*-related VM. Mosaic genetic variants in *TEK* can have low variant allele fractions and therefore elude detection using standard sequencing methods. Using sequencing methods with a higher depth of coverage for the detection of pathogenic *TEK* variants is recommended.

**Table 10.** Notable *TEK* Pathogenic Variants

Reference Sequences	DNA Nucleotide Change	Predicted Protein Change	Comment [Reference]
NM_000459.5 NP_000450.3	c.2545C>T	p.Arg849Trp	Common variant detected in 6 families w/VMCM [Vikkula et al 1996, Wouters et al 2010, Boon et al 2011b]; also proposed to require a 2nd pathogenic variant to cause VM [Limaye et al 2009]
	c.2740C>T	p.Leu914Phe	Most common variant in unifocal VM (mosaic)
	c.2690A>G	p.Tyr897Cys	Most common first mosaic "hit" or variant in MSVM
	c.3314C>A	p.Thr1105Asn	Most common somatic doublet variants (or "double hits") in BRBN syndrome [Soblet et al 2017] <sup>1</sup>
	c.3316A>C	p.Thr1106Pro	

BRBN = blue rubber bleb nevus; MSVM = multifocal sporadic venous malformations; VM = venous malformation; VMCM = multiple cutaneous and mucosal venous malformations

Variants listed in the table have been provided by the authors. *GeneReviews* staff have not independently verified the classification of variants.

*GeneReviews* follows the standard naming conventions of the Human Genome Variation Society ([varnomen.hgvs.org](http://varnomen.hgvs.org)). See [Quick Reference](#) for an explanation of nomenclature.

1. The allele NM\_000459.4:c.[3314C>A;3316A>C], NP\_000450.2:p.[(Thr1105Asn;Thr1106Pro)] is recurrent (57% of individuals with molecularly confirmed BRBN syndrome); the published nomenclature of the allele is T1105N-T1106P [Soblet et al 2017]. The remainder are largely double (*cis*) pathogenic variants containing NM\_000459.4:c.2690A>G (pTyr897Cys) with different combinations [Soblet et al 2013, Soblet et al 2017].

## Chapter Notes

### Author Notes

Center for Vascular Anomalies, Cliniques Universitaires St Luc, Brussels, Belgium

Coordinator: Prof Laurence M Boon, plastic surgeon

#### VASCERN-VASCA

Co-Chairs: Profs Miikka Vikkula and Laurence M Boon

Prof Vikkula, [de Duve Institute](#), Clinical Geneticist, WELBIO Investigator at the WEL Research Institute

Google Scholar [profile](#) (M Vikkula)

Google Scholar [profile](#) (L Boon)

**Prof Miikka Vikkula, MD, PhD** (1992-1993, Helsinki, Finland), is a professor of genetics who became interested in vascular anomalies during his postdoctoral training at Harvard Medical School (1993-1997). Together with his wife, **Prof Laurence M Boon, MD, PhD**, Coordinator of the Center for Vascular Anomalies (Brussels), he has unraveled some key concepts in the pathophysiology of vascular anomalies. The couple discovered *TIE2* for familial venous malformation (in 1996), as well as many other genes since, and have demonstrated "second hits" in multiple cutaneous and mucosal venous malformations (VMCM) and glomuvenous malformations, identified novel clinical entities (such as CM-AVM1 and 2) and made the pivotal demonstration that somatic mutations explain sporadically occurring vascular anomalies (in 2009). With collaborative efforts to generate the first ever animal model for venous malformations, and the proof of concept for treatment with rapamycin, a small molecular inhibitor of VM, the couple is at the forefront of developing

novel targeted therapies based on genetic and pathophysiologic discoveries. Clinical trials are now being conducted with various molecules in some countries. Moreover, off-label use of sirolimus has become a reference treatment for VM. Profs Boon and Vikkula are well-known internationally as major contributors to the understanding of the molecular basis of vascular anomalies, with >200 peer-reviewed publications, >50 reviews and chapters in major medical textbooks, and with >14,000 citations and an H-index of 59 (Google Scholar) for Prof Boon, and >23,000 citations and an H-index of 77 (Google Scholar) for Prof Vikkula. They have received numerous honors such as the Inbev-Baillet Latour Clinical Prize and, for Prof Vikkula, the 1st Generet Award 1 MEUR (in 2019). Prof Vikkula is also the recipient of the Earl Benditt Award 2023 by NAVBO (North American Vascular Biology Organization). They are both Full Members of the Royal Belgian Academy of Medicine. Prof Vikkula is also a WELBIO Investigator at the WEL Research Institute.

**Dr Emmanuel Seront, MD, PhD** (2013) is a medical oncologist who focused his PhD thesis on the mTOR signaling pathway in urologic cancers. He has since worked in close collaboration with the Boon-Vikkula team in order to conduct the large Phase III clinical trial (VASE) using sirolimus in slow-flow vascular malformations. Other trials evaluating new targeted agents are currently ongoing, based on genetic and pathophysiologic discoveries. Dr Seront is a member of the multidisciplinary Center for Vascular Anomalies, Brussels, Belgium (a VASCERN-VASCA reference center) and many oncologic societies (Belgian Society of Medical Oncology, European Society of Medical Oncology, American Society of Clinical Oncology).

All authors are actively involved in clinical research regarding individuals with *TEK*-related VMCM. They would be happy to communicate with persons who have any questions regarding diagnosis of *TEK*-related VMCM or other considerations.

Contact Prof Miikka Vikkula to inquire about *TEK* variants of uncertain significance.

All authors are also interested in hearing from clinicians treating families affected by VMCM in whom no causative variant has been identified through molecular genetic testing of the genes known to be involved in this group of disorders.

## Acknowledgments

All three authors of this publication are members of the Vascular Anomaly Working Group (VASCA) of the European Reference Network for Rare Multisystemic Vascular Diseases (VASCERN), Project ID: 769036.

We are grateful to all the affected individuals and their family members for their invaluable participation during the years of our research studies. Our studies have been financially supported by the Fonds de la Recherche Scientifique – FNRS Grants, most recently by T.0026.14 and T.0247.19 (to MV), T.0146.16 and P.C013.20 (to LMB), the Fund Generet managed by the King Baudouin Foundation (Grant 2018-J1810250-211305) (to MV), and by the Walloon Region through the FRFS-WELBIO strategic research program (WELBIO-CR-2019C-06) (to MV). Our work has also been funded by the MSCA-ITN network VA Cure No 814316 (to MV), the Lymphatic Malformation Institute (LMI), USA (to MV), and the Leducq Foundation Networks of Excellence Program grant "ReVAMP" (LFCR Grant 21CVD03). Our groups have also been funded by the Swiss National Science Foundation under the Sinergia project no. CRSII5\_193694 (LB/MV), and by a continued Pierre M fellowship. We also thank the National Lottery, Belgium, and the Foundation against Cancer (2010-101), Belgium, for their support to the Genomics Platform of Université catholique de Louvain and de Duve Institute, as well as the Fonds de la Recherche Scientifique – FNRS Equipment Grant U.N035.17 for the "Big Data Analysis Cluster for NGS at UCLouvain."

## Revision History

- 2 March 2023 (gm) Comprehensive update posted live
- 17 May 2018 (ma) Comprehensive update posted live

- 29 January 2015 (me) Comprehensive update posted live
- 23 August 2012 (me) Comprehensive update posted live
- 18 September 2008 (me) Review posted live
- 17 January 2008 (mv) Original submission

## References

### Literature Cited

- Adams DM, Trenor CC 3rd, Hammill AM, Vinks AA, Patel MN, Chaudry G, Wentzel MS, Mobberley-Schuman PS, Campbell LM, Brookbank C, Gupta A, Chute C, Eile J, McKenna J, Merrow AC, Fei L, Hornung L, Seid M, Dasgupta AR, Dickie BH, Elluru RG, Lucky AW, Weiss B, Azizkhan RG. Efficacy and safety of sirolimus in the treatment of complicated vascular anomalies. *Pediatrics*. 2016;137:e20153257. PubMed PMID: 26783326.
- Ali B, Panossian A, Taghinia A, Mulliken JB, Alomari A, Adams DM, Fishman SJ, Upton J 3rd. Diffuse venous malformations of the upper extremity (Bockenheimer disease): diagnosis and management. *Plast Reconstr Surg*. 2020;146:1317–24. PubMed PMID: 33234962.
- Amyere M, Aerts V, Brouillard P, McIntyre BA, Duhoux FP, Wassef M, Enjolras O, Mulliken JB, Devuyt O, Antoine-Poirel H, Boon LM, Vikkula M. Somatic uniparental isodisomy explains multifocality of glomuvenous malformations. *Am J Hum Genet*. 2013;92:188–96. PubMed PMID: 23375657.
- Ballieux F, Boon LM, Vikkula M. Blue bleb rubber nevus syndrome. *Handb Clin Neurol*. 2015;132:223–30. PubMed PMID: 26564083.
- Beluffi G, Romano P, Matteotti C, Minniti S, Ceffa F, Morbini P. Jejunal intussusception in a 10-year-old boy with blue rubber bleb nevus syndrome. *Pediatr Radiol*. 2004;34:742–5. PubMed PMID: 15105976.
- Biesecker LG, Adam MP, Alkuraya FS, Amemiya AR, Bamshad MJ, Beck AE, Bennett JT, Bird LM, Carey JC, Chung B, Clark RD, Cox TC, Curry C, Dinulos MBP, Dobyns WB, Giampietro PF, Girisha KM, Glass IA, Graham JM Jr, Gripp KW, Haldeman-Englert CR, Hall BD, Innes AM, Kalish JM, Keppler-Noreuil KM, Kosaki K, Kozel BA, Mirzaa GM, Mulvihill JJ, Nowaczyk MJM, Pagon RA, Retterer K, Rope AF, Sanchez-Lara PA, Seaver LH, Shieh JT, Slavotinek AM, Sobering AK, Stevens CA, Stevenson DA, Tan TY, Tan WH, Tsai AC, Weaver DD, Williams MS, Zackai E, Zarate YA. A dyadic approach to the delineation of diagnostic entities in clinical genomics. *Am J Hum Genet*. 2021;108:8–15. PubMed PMID: 33417889.
- Boon LM, Ballieux F, Vikkula M. Pathogenesis of vascular anomalies. *Clin Plast Surg*. 2011a;38:7–19. PubMed PMID: 21095468.
- Boon LM, Enjolras O, Mulliken JB, Vikkula M. Vascular malformations. In: Irvine A, Hoeger P, Yan A, eds. *Harper's Textbook of Pediatric Dermatology*. 3 ed. Wiley-Blackwell; 2011b:112.1-112.24.
- Boon LM, Mulliken JB, Enjolras O, Vikkula M. Glomuvenous malformation (glomangioma) and venous malformation: distinct clinicopathologic and genetic entities. *Arch Dermatol*. 2004;140:971–6. PubMed PMID: 15313813.
- Boon LM, Mulliken JB, Vikkula M, Watkins H, Seidman J, Olsen BR, Warman ML. Assignment of a locus for dominantly inherited venous malformations to chromosome 9p. *Hum Mol Genet*. 1994;3:1583–7. PubMed PMID: 7833915.
- Boon LM, Vikkula M. Molecular genetics of vascular malformations. In: Mulliken JB, Burrown PE, Fishman SJ, eds. *Mulliken and Young's Vascular Anomalies: Hemangiomas and Malformations*. 2 ed. New York, NY: Oxford University Press; 2013:327-75.
- Boon LM, Vikkula M. Vascular anomalies. In: *Fitzpatrick's Dermatology in General Medicine*. 8 ed. New York, NY: McGraw-Hill Professional Publishing; 2012.



- Boscolo E, Limaye N, Huang L, Kang KT, Soblet J, Uebelhoer M, Mendola A, Natynki M, Seront E, Dupont S, Hammer J, Legrand C, Brugnara C, Eklund L, Vikkula M, Bischoff J, Boon LM. Rapamycin improves TIE2-mutated venous malformation in murine model and human subjects. *J Clin Invest*. 2015;125:3491–504. PubMed PMID: 26258417.
- Brouillard P, Boon LM, Mulliken JB, Ghassibé M, Warman ML, Tan OT, Olsen BR, Vikkula M. Mutations in a novel factor, glomulin, are responsible for glomuvenous malformations ("glomangiomas"). *Am J Hum Genet*. 2002;70:866–74. PubMed PMID: 11845407.
- Brouillard P, Boon LM, Revencu N, Berg J, Domp Martin A, Dubois J, Garzon M, Holden S, Kangesu L, Labrèze C, Lynch SA, McKeown C, Meskuskas R, Quere I, Syed S, Vabres P, Wassef M, Mulliken JB, Vikkula M, et al. Genotypes and phenotypes of 162 families with a glomulin mutation. *Mol Syndromol*. 2013;4:157–64. PubMed PMID: 23801931.
- Brouillard P, Enjolras E, Boon LM, Vikkula M. Glomulin and glomuvenous malformation. In: Epstein CJ, Erickson RP, Wynshaw-Boris A, eds. *Inborn Errors of Development*. New York, NY: Oxford University Press; 2008.
- Brouillard P, Ghassibé M, Penington A, Boon LM, Domp Martin A, Temple IK, Cordisco M, Adams D, Piette F, Harper JJ, Syed S, Boralevi F, Taïeb A, Danda S, Baselga E, Enjolras O, Mulliken JB, Vikkula M. Four common glomulin mutations cause two thirds of glomuvenous malformations ("familial glomangiomas"): evidence for a founder effect. *J Med Genet*. 2005;42:e13. PubMed PMID: 15689436.
- Brouillard P, Vikkula M. Genetic causes of vascular malformations. *Hum Mol Genet*. 2007;16:R140–9. PubMed PMID: 17670762.
- Calvert JT, Riney TJ, Kontos CD, Cha EH, Prieto VG, Shea CR, Berg JN, Nevin NC, Simpson SA, Pasyk KA, Speer MC, Peters KG, Marchuk DA. Allelic and locus heterogeneity in inherited venous malformations. *Hum Mol Genet*. 1999;8:1279–89. PubMed PMID: 10369874.
- Couto JA, Vivero MP, Kozakewich HP, Taghinia AH, Mulliken JB, Warman ML, Greene AK. A somatic MAP3K3 mutation is associated with verrucous venous malformation. *Am J Hum Genet*. 2015;96:480–6. PubMed PMID: 25728774.
- Deshpande GA, Samarasam I, George SV, Chandran S. Blue rubber bleb nevus syndrome: a rare cause of chronic gastrointestinal bleed in adults. *Singapore Med J*. 2014;55:e175–6. PubMed PMID: 25631979.
- Domp Martin A, Acher A, Domp Martin A, Acher A, Thibon P, Tourbach S, Hermans C, Deneys V, Pocock B, Lequerrec A, Labbé D, Barrellier M-T, Vanwijck R, Vikkula M, Boon LM. Association of localized intravascular coagulopathy with venous malformations. *Arch Dermatol*. 2008;144:873–7. PubMed PMID: 18645138.
- Domp Martin A, Baselga E, Boon LM, Diociaiuti A, Dvorakova V, El Hachem M, Gasparella P, Haxhija E, Ghaffarpour N, Kyrklund K, Irvine AD, Kapp FG, Rößler J, Salminen P, van den Bosch C, van der Vleuten C, Schultze Kool L, Vikkula M. The VASCERN-VASCA Working Group diagnostic and management pathways for venous malformations. *J Vasc Anom (Phila)*. 2023;4:e064. PubMed PMID: 37332880.
- Domp Martin A, Vikkula M, Boon LM. Venous malformation: update on aetiopathogenesis, diagnosis and management. *Phlebology*. 2010;25:224–35. PubMed PMID: 20870869.
- Hammer FD, Boon LM, Mathurin P, Vanwijck RR. Ethanol sclerotherapy of venous malformations: evaluation of systemic ethanol contamination. *J Vasc Interv Radiol*. 2001;12:595–600. PubMed PMID: 11340138.
- Hammer J, Seront E, Duez S, Dupont S, Van Damme A, Schmitz S, Hoyoux C, Chopinet C, Clapuyt P, Hammer F, Vikkula M, Boon LM. Sirolimus is efficacious in treatment for extensive and/or complex slow-flow vascular malformations: a monocentric prospective phase II study. *Orphanet J Rare Dis*. 2018;13:191. PubMed PMID: 30373605.

- Ji Y, Chen S, Yang K, Zhou J, Zhang X, Jiang X, Xu X, Lu G, Qiu L, Kong F, Zhang Y. A prospective multicenter study of sirolimus for complicated vascular anomalies. *J Vasc Surg*. 2021;74:1673–81.e3. PubMed PMID: 34082006.
- Korpelainen EI, Karkkainen M, Gunji Y, Vikkula M, Alitalo K. Endothelial receptor tyrosine kinases activate the STAT signaling pathway: mutant Tie-2 causing venous malformations signals a distinct STAT activation response. *Oncogene*. 1999;18:1–8. PubMed PMID: 9926914.
- Kubiena HF, Liang MG, Mulliken JB. Genuine diffuse phlebectasia of Bockenheimer: dissection of an eponym. *Pediatr Dermatol*. 2006;23:294–7. PubMed PMID: 16780484.
- Limaye N, Kangas J, Mendola A, Godfraind C, Schlögel MJ, Helaers R, Eklund L, Boon LM, Vikkula M. Somatic activating PIK3CA mutations cause venous malformation. *Am J Hum Genet*. 2015;97:914–21. PubMed PMID: 26637981.
- Limaye N, Wouters V, Uebelhoer M, Tuominen M, Wirkkala R, Mulliken JB, Eklund L, Boon LM, Vikkula M. Somatic mutations in angiopoietin receptor gene TEK cause solitary and multiple sporadic venous malformations. *Nat Genet*. 2009;41:118–24. PubMed PMID: 19079259.
- Mallory SB, Enjolras O, Boon LM, Rogers E, Berk DR, Blei F, Baselga E, Ros AM, Vikkula M. Congenital plaque-type glomuvenous malformations presenting in childhood. *Arch Dermatol*. 2006;142:892–6. PubMed PMID: 16847206.
- Maruani A, Tavernier E, Boccara O, Mazereeuw-Hautier J, Leducq S, Bessis D, et al. Sirolimus (rapamycin) for slow-flow malformations in children: the observational-phase randomized clinical PERFORMUS trial. *JAMA Dermatol*. 2021;157:1289–98. PubMed PMID: 34524406.
- Nätyнки M, Kangas J, Miinalainen I, Sormunen R, Pietilä R, Soblet J, Boon LM, Vikkula M, Limaye N, Eklund L. Common and specific effects of TIE2 mutations causing venous malformations. *Hum Mol Genet*. 2015;24:6374–89. PubMed PMID: 26319232.
- Rahbari R, Wuster A, Lindsay SJ, Hardwick RJ, Alexandrov LB, Turki SA, Dominiczak A, Morris A, Porteous D, Smith B, Stratton MR, Hurles ME, et al. Timing, rates and spectra of human germline mutation. *Nat Genet*. 2016;48:126–33. PubMed PMID: 26656846.
- Ren AA, Snellings DA, Su YS, Hong CC, Castro M, Tang AT, Detter MR, Hobson N, Girard R, Romanos S, Lightle R, Moore T, Shenkar R, Benavides C, Beaman MM, Müller-Fielitz H, Chen M, Mericko P, Yang J, Sung DC, Lawton MT, Ruppert JM, Schwaninger M, Körbelin J, Potente M, Awad IA, Marchuk DA, Kahn ML. PIK3CA and CCM mutations fuel cavernomas through a cancer-like mechanism. *Nature*. 2021;594:271–6. PubMed PMID: 33910229.
- Richards S, Aziz N, Bale S, Bick D, Das S, Gastier-Foster J, Grody WW, Hegde M, Lyon E, Spector E, Voelkerding K, Rehm HL, et al. Standards and guidelines for the interpretation of sequence variants: a joint consensus recommendation of the American College of Medical Genetics and Genomics and the Association for Molecular Pathology. *Genet Med*. 2015;17:405–24. PubMed PMID: 25741868.
- Sirvente J, Enjolras O, Wassef M, Tournier-Lasserre E, Labauge P. Frequency and phenotypes of cutaneous vascular malformations in a consecutive series of 417 patients with familial cerebral cavernous malformations. *J Eur Acad Dermatol Venereol*. 2009;23:1066–72. PubMed PMID: 19453802.
- Soblet J, Kangas J, Nätyнки M, Mendola A, Helaers R, Uebelhoer M, Kaakinen M, Cordisco M, Dompmartin A, Enjolras O, Holden S, Irvine AD, Kangesu L, Léauté-Labrèze C, Lanoel A, Lokmic Z, Maas S, McAleer MA, Penington A, Rieu P, Syed S, van der Vleuten C, Watson R, Fishman SJ, Mulliken JB, Eklund L, Limaye N, Boon LM, Vikkula M. Blue rubber bleb nevus (BRBN) syndrome is caused by somatic TEK (TIE2) mutations. *J Invest Dermatol*. 2017;137:207–216. PubMed PMID: 27519652.
- Soblet J, Limaye N, Uebelhoer M, Boon LM, Vikkula M. Variable somatic TIE2 mutations in half of sporadic venous malformations. *Mol Syndromol*. 2013;4:179e83.

- Stenson PD, Mort M, Ball EV, Chapman M, Evans K, Azevedo L, Hayden M, Heywood S, Millar DS, Phillips AD, Cooper DN. The Human Gene Mutation Database (HGMD®): optimizing its use in a clinical diagnostic or research setting. *Hum Genet.* 2020;139:1197–207. PubMed PMID: 32596782.
- Uebelhoer M, Nätyнки M, Kangas J, Mendola A, Nguyen HL, Soblet J, Godfraind C, Boon LM, Eklund L, Limaye N, Vikkula M. Venous malformation-causative TIE2 mutations mediate an AKT-dependent decrease in PDGFB. *Hum Mol Genet.* 2013;22:3438–48. PubMed PMID: 23633549.
- Vikkula M, Boon LM, Carraway KL III, Calvert JT, Diamonti AJ, Goumnerov B, Pasyk KA, Marchuk DA, Warman ML, Cantley LC, Mulliken JB, Olsen BR. Vascular dysmorphogenesis caused by an activating mutation in the receptor tyrosine kinase TIE2. *Cell.* 1996;87:1181–90. PubMed PMID: 8980225.
- Vogel SA, Hess CP, Dowd CF, Hoffman WY, Kane AJ, Rajaii R, Frieden IJ. Early versus later presentations of venous malformations: where and why? *Pediatr Dermatol.* 2013;30:534–40. PubMed PMID: 23679583.
- Wassef M, Blei F, Adams D, Alomari A, Baselga E, Berenstein A, Burrows P, Frieden IJ, Garzon MC, Lopez-Gutierrez JC, Lord DJ, Mitchel S, Powell J, Prendiville J, Vikkula M, et al. Vascular anomalies classification: recommendations from the International Society for the Study of Vascular Anomalies. *Pediatrics.* 2015;136:e203–14. PubMed PMID: 26055853.
- Wonaga A, Fernández JL, Barsanti A, Viola LA. An infrequent cause of iron-deficiency anemia: blue rubber bleb nevus syndrome. *Rev Gastroenterol Mex.* 2014;79:151–2. PubMed PMID: 24861528.
- Wouters V, Boon LM, Vikkula M. TIE2 and cutaneomucosal venous malformation. In: Epstein CJ, Erickson RP, Wynshaw-Boris A, eds. *Inborn Errors of Development.* New York, NY: Oxford University Press; 2008.
- Wouters V, Limaye N, Uebelhoer M, Irrthum A, Boon LM, Mulliken JB, Enjolras O, Baselga E, Berg J, Domp Martin A, Ivarsson SA, Kangesu L, Lacassie Y, Teebi AS, Pennington A, Rieu P, Vikkula M. Hereditary cutaneomucosal venous malformations are caused by TIE2 mutations with widely variable hyperphosphorylating effects. *Eur J Hum Genet.* 2010;18:414–20. PubMed PMID: 19888299.
- Zhou J, Zhao Z, Sun T, Liu W, Yu Z, Liu J, Yu Y, Ning S, Zhang H. Efficacy and safety of sirolimus for blue rubber bleb nevus syndrome: a prospective study. *Am J Gastroenterol.* 2021;116:1044–52. PubMed PMID: 33416235.

## License

GeneReviews® chapters are owned by the University of Washington. Permission is hereby granted to reproduce, distribute, and translate copies of content materials for noncommercial research purposes only, provided that (i) credit for source (<http://www.genereviews.org/>) and copyright (© 1993-2024 University of Washington) are included with each copy; (ii) a link to the original material is provided whenever the material is published elsewhere on the Web; and (iii) reproducers, distributors, and/or translators comply with the [GeneReviews® Copyright Notice and Usage Disclaimer](#). No further modifications are allowed. For clarity, excerpts of GeneReviews chapters for use in lab reports and clinic notes are a permitted use.

For more information, see the [GeneReviews® Copyright Notice and Usage Disclaimer](#).

For questions regarding permissions or whether a specified use is allowed, contact: [admasst@uw.edu](mailto:admasst@uw.edu).