



## Congenital Contractural Arachnodactyly

Synonyms: Beals-Hecht Syndrome, Beals Syndrome

Bert Callewaert, MD, PhD<sup>1</sup>

Created: January 23, 2001; Revised: July 14, 2022.

### Summary

#### Clinical characteristics

Congenital contractural arachnodactyly (CCA) appears to comprise a broad phenotypic spectrum. Classic CCA is characterized by arachnodactyly; flexion contractures of multiple joints including elbows, knees, hips, ankles, and/or fingers; kyphoscoliosis (usually progressive); a marfanoid habitus (a long and slender build, dolichostenomelia, pectus deformity, muscular hypoplasia, highly arched palate); and abnormal "crumpled" ears. At the mildest end, parents who are diagnosed retrospectively upon evaluation of their more severely affected child may show a lean body build, mild arachnodactyly, mild contractures without impairment, and minor ear abnormalities. At the most severe end is "severe CCA with cardiovascular and/or gastrointestinal anomalies," a rare phenotype in infants with pronounced features of CCA (severe crumpling of the ears, arachnodactyly, contractures, congenital scoliosis, and/or hypotonia) and severe cardiovascular and/or gastrointestinal anomalies. Phenotypic expression can vary within and between families.

#### Diagnosis/testing

The diagnosis of CCA can be established in a proband with suggestive findings and a heterozygous *FBN2* pathogenic variant identified by molecular genetic testing; however, locus heterogeneity is likely given that only 25%-75% of individuals with clinically diagnosed CCA have an identifiable *FBN2* pathogenic variant. Because CCA can be difficult to diagnose clinically, a clinical scoring system based on presence or absence of crumpled ears, musculoskeletal findings, highly arched palate, and micrognathia can be used.

#### Management

*Treatment of manifestations of classic CCA:* Standard management of contractures, clubfeet, kyphoscoliosis including surgical intervention as needed; early physical therapy to improve mobility and occupational therapy to improve camptodactyly. Aortic root dilatation, correction of refractive errors, and palatal abnormalities are managed in a standard manner.

*Surveillance for classic CCA:* Annual evaluation for kyphosis/scoliosis if not present at initial evaluation; routine measurement of aortic root diameter for evidence of aortic dilatation; routine assessment of visual acuity and refractive error; annual assessment of orthodontic needs after age eight years.

*Agents/circumstances to avoid:* Contact sports and activities that stress joints; LASIK eye surgery, which may increase the risk for keratoconus in those with predisposing ocular conditions.

*Evaluation of relatives at risk:* Clarification of the genetic status of apparently asymptomatic or self-reportedly asymptomatic at-risk relatives by molecular genetic testing if the familial *FBN2* variant is known, otherwise by clinical examination to identify those with a low – but potential – risk for aortic and/or ocular complications.

*Pregnancy management:* Although no complications related to pregnancy or delivery have been reported in women with CCA, it is advisable to perform an echocardiography preconceptually and to increase cardiac surveillance during pregnancy in women with dilatation of the aortic root.

## Genetic counseling

CCA is inherited in an autosomal dominant manner. While many individuals with CCA have an affected parent, as many as 50% may have a *de novo* *FBN2* pathogenic variant. If a parent of a proband has clinical features of CCA and/or is known to have the *FBN2* pathogenic variant identified in the proband, the risk to sibs of the proband is 50%. Because intrafamilial clinical variability is observed in CCA, a heterozygous sib may have a more or less severe phenotypic presentation than the proband. Once the *FBN2* pathogenic variant has been identified in an affected family member, prenatal testing and preimplantation genetic testing are possible.

## Diagnosis

Formal diagnostic criteria for congenital contractural arachnodactyly (CCA) have not been established.

## Suggestive Findings

Classic CCA **should be suspected** in individuals with the following:

- Arachnodactyly with positive wrist and thumb sign
- Flexion contractures of multiple joints including elbows, knees, hips, ankles, and/or fingers
- Kyphoscoliosis (usually progressive)
- Abnormal pinnae ("crumpled" outer helices)
- A marfanoid habitus (a long and slender build, dolichostenomelia, pectus deformity, muscular hypoplasia, highly arched palate)

On rare occasions, infants were reported with the clinical findings of classic CCA as well as the following anomalies [Lipson et al 1974, Currarino & Friedman 1986, Macnab et al 1991, Wang et al 1996, Snape et al 2006]:

- **Cardiovascular.** Interrupted aortic arch and atrial or ventricular septal defects, and/or severe aortic root dilatation (rare)
- **Gastrointestinal.** Duodenal or esophageal atresia and/or intestinal malrotation

Although this phenotype has been referred to as "severe/lethal CCA," its molecular basis has not been unequivocally established and a lethal outcome is not certain; the term "severe CCA with cardiovascular and/or gastrointestinal anomalies" more accurately describes this disorder [Author, personal observation].

## Establishing the Diagnosis

The diagnosis of CCA is **established** in a proband with suggestive findings and a heterozygous *FBN2* pathogenic (or likely pathogenic) variant identified by molecular genetic testing (Table 1). However, locus heterogeneity is likely, given that only 25%-75% of individuals clinically diagnosed with CCA have an identifiable *FBN2* pathogenic variant [Gupta et al 2002; Callewaert et al 2009; Nishimura et al 2007; Meerschaut et al 2020; Callewaert et al, unpublished data]. Because CCA is difficult to diagnose clinically, Meerschaut et al [2020] developed a **clinical scoring system** to facilitate the clinical diagnosis of CCA (Table 2).

Note: Per ACMG variant interpretation guidelines, the terms "pathogenic variants" and "likely pathogenic variants" are synonymous in a clinical setting, meaning that both are considered diagnostic and both can be used for clinical decision making. Reference to "pathogenic variants" in this section is understood to include any likely pathogenic variants.

**Molecular genetic testing** approaches can include a combination of **gene-targeted testing** (single-gene testing, multigene panel) and **comprehensive genomic testing** (exome sequencing, genome sequencing) depending on the phenotype.

Gene-targeted testing requires that the clinician determine which gene(s) are likely involved, whereas genomic testing does not. Because the phenotype of congenital contractural arachnodactyly is broad, individuals with the distinctive findings described in Suggestive Findings are likely to be diagnosed using gene-targeted testing (see Option 1), whereas those in whom the diagnosis of CCA has not been considered because of atypical findings are more likely to be diagnosed using genomic testing (see Option 2).

### Option 1

**Single-gene testing.** Sequence analysis of *FBN2* detects small intragenic deletions/insertions and missense, nonsense, and splice site variants; typically, exon or whole-gene deletions/duplications are not detected. Perform sequence analysis first. If no pathogenic variant is found, perform gene-targeted deletion/duplication analysis to detect intragenic deletions or duplications.

**A multigene panel** that includes *FBN2* and other genes of interest (see Differential Diagnosis) is most likely to identify the genetic cause of the condition while limiting identification of variants of uncertain significance and pathogenic variants in genes that do not explain the underlying phenotype. Note: (1) The genes included in the panel and the diagnostic sensitivity of the testing used for each gene vary by laboratory and are likely to change over time. (2) Some multigene panels may include genes not associated with the condition discussed in this *GeneReview*. Since the differential diagnosis of CCA includes [Marfan syndrome](#) and [Loeys-Dietz syndrome](#), clinicians requesting a panel including genes for heritable thoracic aortic aneurysms and dissections (HTAD) should be aware that *FBN2* may not be included in some panels based on recent recommendations for HTAD genetic testing [Renard et al 2018]. (3) In some laboratories, panel options may include a custom laboratory-designed panel and/or custom phenotype-focused exome analysis that includes genes specified by the clinician. (4) Methods used in a panel may include sequence analysis, deletion/duplication analysis, and/or other non-sequencing-based tests. For CCA a multigene panel that also includes deletion/duplication analysis is recommended (see Table 1).

For an introduction to multigene panels click [here](#). More detailed information for clinicians ordering genetic tests can be found [here](#).

### Option 2

When the diagnosis of CCA is not considered because an individual has atypical phenotypic features, **comprehensive genomic testing** (which does not require the clinician to determine which gene[s] are likely

involved) is an option. **Exome sequencing** is currently the most commonly used genomic testing method; **genome sequencing** is also possible.

If exome sequencing is not diagnostic, **exome array** (when clinically available) may be considered to detect (multi)exon deletions or duplications that cannot be detected by sequence analysis.

For an introduction to comprehensive genomic testing click [here](#). More detailed information for clinicians ordering genomic testing can be found [here](#).

**Table 1.** Molecular Genetic Testing Used in Congenital Contractural Arachnodactyly

Gene <sup>1</sup>	Proportion of CCA Attributed to Pathogenic Variants in Gene <sup>2</sup>	Method	Proportion of <i>FBN2</i> Pathogenic Variants <sup>3</sup> Detectable by Method
<i>FBN2</i>	25%-75%	Sequence analysis <sup>4</sup>	~93%
		Gene-targeted deletion/duplication analysis <sup>5</sup>	~7% <sup>6</sup>
Unknown	25%-75%	NA	

1. See Table A. Genes and Databases for chromosome locus and protein.

2. Because the detection rate for *FBN2* pathogenic or likely pathogenic variants is low in individuals with a clinically convincing diagnosis of CCA, genetic heterogeneity is likely [Gupta et al 2002; Nishimura et al 2007; Callewaert et al 2009; Meerschaut et al 2020; Callewaert et al, unpublished data].

3. See Molecular Genetics for information on allelic variants detected in this gene.

4. Sequence analysis detects variants that are benign, likely benign, of uncertain significance, likely pathogenic, or pathogenic. Variants may include small intragenic deletions/insertions and missense, nonsense, and splice site variants; typically, exon or whole-gene deletions/duplications are not detected. For issues to consider in interpretation of sequence analysis results, click [here](#).

5. Gene-targeted deletion/duplication analysis detects intragenic deletions or duplications. Methods used may include a range of techniques such as quantitative PCR, long-range PCR, multiplex ligation-dependent probe amplification (MLPA), and a gene-targeted microarray designed to detect single-exon deletions or duplications. Gene-targeted deletion/duplication testing will detect deletions ranging from a single exon to the whole gene; however, breakpoints of an entire *FBN2* deletion and/or deletion of adjacent genes (e.g., those described by Inbar-Feigenberg et al [2014]) may not be detected by these methods.

6. Five known deletion/duplication pathogenic variants include a mosaic deletion of exons 7-34 [Lavillaureix et al 2017], a duplication of exon 23 [Gupta et al 2002], and a deletion of exons 38-48, 43-48, and 45-48 [Meerschaut et al 2020].

## Clinical Scoring System

In the absence of a pathogenic or likely pathogenic *FBN2* variant and in the absence of intellectual disability, progressive aortic root dilatation, and/or ectopia lentis, a clinical score of  $\geq 7/20$  is suggestive for CCA (sensitivity 95.5%; specificity 17.1%) and a score of  $\geq 11/20$  makes the diagnosis of CCA likely (sensitivity 75%; specificity 60%) [Meerschaut et al 2020].

**Table 2.** Clinical Scoring System

Clinical Feature	Points	Comments
Crumpled ears	3	<ul style="list-style-type: none"> <li>In neonates: a "crumpled ear" often shows underdevelopment &amp; folding of the upper part of the helix w/a prominent helical crus &amp; inferior crus of the antihelix.</li> <li>In older children / adults: ear may "unfold" but the prominence of the crura remains, giving a "tram track" appearance to the ear (see Figure 1).</li> </ul>

Table 2. continued from previous page.

Clinical Feature	Points	Comments
Arachnodactyly	3	<ul style="list-style-type: none"> <li>Assessed by evaluating the wrist sign <sup>1</sup> and the thumb sign <sup>2</sup></li> <li>Both signs should be present before arachnodactyly is confirmed.</li> </ul>
Camptodactyly	3	
Large-joint contractures	3	
Pectus deformity	2	
Dolichostenomelia	2	Defined as presence of: <ul style="list-style-type: none"> <li>↓ US/LS ratio (for white adults &lt;0.85; &lt;0.78 in black adults; no data assessed in Asians); AND</li> <li>↑ arm-span-to-height ratio (for adults &gt;1.05) w/no significant scoliosis [Loeys et al 2010]</li> </ul>
Kyphoscoliosis	1	<ul style="list-style-type: none"> <li>Scoliosis can be diagnosed clinically <sup>3</sup> or by radiograph. <sup>4</sup></li> <li>Kyphosis = exaggerated thoracolumbar kyphosis [Loeys et al 2010]</li> </ul>
Muscle hypoplasia	1	
Highly arched palate	1	
Micrognathia	1	

Based on Loeys et al [2010]

US/LS = upper segment to lower segment

1. Positive wrist sign: the tip of the thumb covers the entire fingernail of the fifth finger when wrapped around the contralateral wrist [Loeys et al 2010].

2. Positive thumb sign: the entire distal phalanx of the adducted thumb extends beyond the ulnar border of the palm with or without the assistance of the patient or examiner to achieve maximal adduction [Loeys et al 2010].

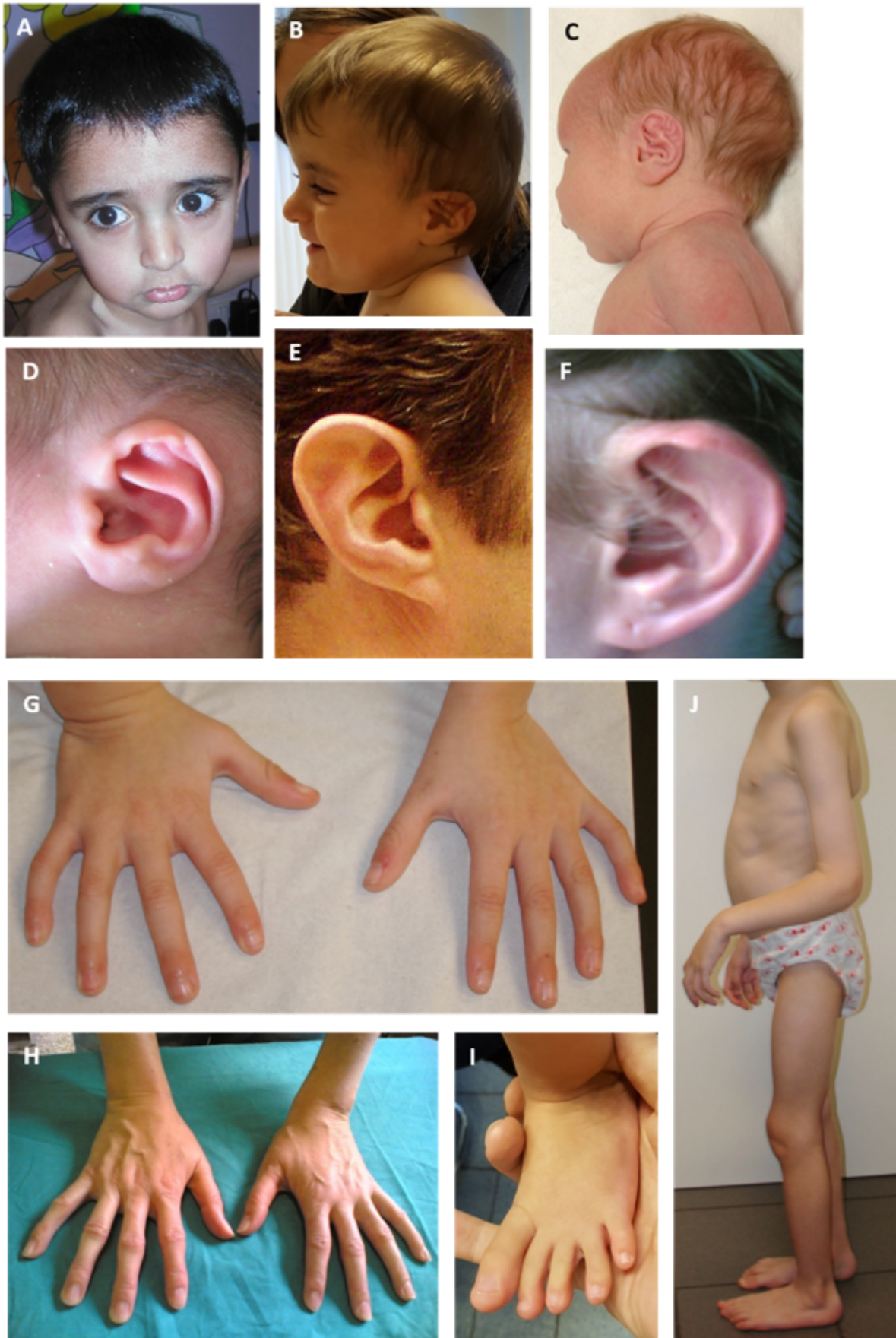
3. Clinical diagnosis: on bending forward, a vertical difference of  $\geq 1.5$  cm between the ribs of the left and right hemithorax is observed [Loeys et al 2010].

4. Radiographic: a Cobb's angle (angle between a line drawn along the superior-end plate of the superior-end vertebra and a second line drawn along the inferior-end plate of the inferior-end vertebra of the scoliosis measured on anterior-posterior view of the spine) of  $\geq 20^\circ$  is seen [Loeys et al 2010].

## Clinical Characteristics

### Clinical Description

Congenital contractural arachnodactyly (CCA) appears to comprise a broad phenotypic spectrum. Phenotypic expression is variable within and between families. At the mildest end, parents who are diagnosed retrospectively upon evaluation of their more severely affected child may show a lean body build, mild arachnodactyly, prominent anterior crus of the antihelix, and/or mild contractures without impairment. At the most severe end is "severe CCA with cardiovascular and/or gastrointestinal anomalies," a rare phenotype in infants with pronounced features of CCA (severe crumpling of the ears, arachnodactyly, contractures, congenital scoliosis, and/or hypotonia) and severe cardiovascular and/or gastrointestinal anomalies. Only one child with the severe form of CCA has been confirmed to have an *FBN2* pathogenic variant [Wang et al 1996], but it remains unclear if additional variants affecting other genes could account for this phenotype.



**Figure 1.** Features of CCA

- A. Facial characteristics in a child age two years: midface hypoplasia and micrognathia
- B, C. Facial characteristics in a child age one year (B) and a child age five months (C) showing dolichocephaly, flat midface, micrognathia, and crumpled ear
- D. Crumpled ear in a neonate
- E, F. External ear anomalies in adults showing that the ear has "unfolded," but the helical crus and inferior crus of the antihelix remain prominent and parallel giving a "tram track" appearance
- G, H. Arachnodactyly of the fingers in a child age four years (G) and an adult (H) showing mild contractures of the proximal interphalangeal joints
- I. Arachnodactyly of the toes and a long and slender foot in a child age one year
- J. Muscular hypoplasia and contractures of the knees in a child age four years
- Images published with family consent.

## Classic CCA

**Table 3.** Selected Clinical Features in Classic Congenital Contractural Arachnodactyly by Frequency

Clinical Feature	Frequency <sup>1, 2</sup>
Arachnodactyly	98%
Small-joint contractures	92%
Large-joint contractures	88%
Crumpled ears	78%
Kyphosis/scoliosis	62%
Muscle hypoplasia	55%
Dolichostenomelia	50%
Pectus deformity	41%
Highly arched palate	67%
Micrognathia	34%

1. Features are ordered by frequency.

2. %s are based on individuals with a confirmed (likely) *FBN2* pathogenic variant [Meerschaut et al 2020].

### Features seen in individuals with CCA

- **Arachnodactyly** (long slender fingers and toes) caused by overgrowth of the phalanges (Figure 1)
- **Joint contractures**
  - Camptodactyly. Contractures of the small joints (metacarpo/tarsophalangeal, proximal, and distal interphalangeal joints)
  - Large-joint contractures. Limited movement of hips, knees, ankles (clubfoot), shoulders, elbows, and wrists

Contractures of small and large joints usually improve with time, but some limited restriction often remains. Careful assessment is therefore necessary in (older) children and adults.

- **"Crumpled" ears.** Hearing is normal in individuals with CCA.
- **Kyphosis/scoliosis.** Scoliosis can be congenital or develop/worsen during periods of fast growth (6 months – 2 years, pubertal growth spurt), and may cause significant morbidity in CCA.

- **Muscle hypoplasia.** A thin body habitus with relative underdevelopment of the muscular reliefs with reference to age, activity level, and nutritional status. Of note, muscular hypoplasia was more frequently reported in individuals suspected with CCA without a (likely) pathogenic *FBN2* variant (65%) [Meerschaut et al 2020]. However, this feature is likely underreported (Figure 1).
- **Dolichostenomelia.** A tall and slender habitus with long-bone overgrowth evoking a marfanoid habitus
- **Pectus deformity** (most frequently pectus excavatum). Due to overgrowth of the ribs, the sternum and anterior thoracic wall are pushed in (pectus excavatum) or out (pectus carinatum).
- **Craniofacial abnormalities**
  - Dolichocephaly (long, narrow skull)
  - Enophthalmia and mildly downslanting palpebral fissures (rare)
  - Flat midface
  - Highly arched palate
  - Micrognathia. Although more often reported in individuals with CCA without a (likely) pathogenic *FBN2* variant [Meerschaut et al 2020], it may be underassessed.

#### Other features, not routinely assessed in case reports of CCA

- **Aortic root dilatation** had been documented in individuals with CCA with a confirmed *FBN2* pathogenic variant [Park et al 1998, Carmical et al 1999, Gupta et al 2002, Snape et al 2006, Callewaert et al 2009, Takeda et al 2015, Meerschaut et al 2020] and may be present in up to 10%-15% of individuals with CCA harboring a (likely) pathogenic *FBN2* variant. Progression of aortic dilatation and aortic dissection was reported in one family [Takeda et al 2015] and in one nine-month-old child with CCA [Siddiqui & Panesar 2019]. Therefore, the presence of progressive aortic root dilatation does not eliminate the possibility of CCA, but clinicians should also consider other diagnoses that could account for this rare finding in CCA (see Differential Diagnosis).
- **Ocular features.** Myopia is frequently reported, but unlikely to be more common than in the general population. Keratoconus has been noted in two individuals [Callewaert et al 2009]. Of note, ectopia lentis has never been reported in persons with a confirmed (likely) pathogenic *FBN2* variant.
- **Bowed long bones.** Incidental reports, but rarely assessed as it requires radiographs
- **Recurrent patellar dislocations** can be disabling [Callewaert et al 2009].
- **Congenital diaphragmatic hernia.** Reported in one individual [Meerschaut et al 2020]
- **Cervical anomalies** including a narrowed foramen magnum and C2-C3 fusion have been reported in one individual with a clinical, but not molecular, diagnosis of CCA [Meena et al 2015].

#### Severe CCA with Cardiovascular and/or Gastrointestinal Anomalies

In addition to the typical skeletal findings in CCA, a few infants with multiple cardiovascular and/or gastrointestinal anomalies requiring surgical correction as early as the first week of life have been reported [Lipson et al 1974, Currarino & Friedman 1986, Macnab et al 1991, Wang et al 1996]. The most common cardiovascular anomalies include interrupted aortic arch and atrial or ventricular septal defects. Gastrointestinal anomalies include esophageal or duodenal atresia and/or intestinal malrotation.

The age of death has ranged from eight days to 11.5 months. Respiratory complications including tracheomalacia and respiratory infections have been the cause of death in most.

#### Somatic Mosaicism

Somatic mosaicism has been reported in the following instances:



- A mother with somatic mosaicism for an *FBN2* variant had features of classic CCA. Her daughter, who inherited the *FBN2* pathogenic variant, had severe CCA with cardiovascular and gastrointestinal anomalies [Wang et al 1996].
- A likely in-frame mosaic intragenic deletion from exons 7-34 spanning the central region of the gene (exons 24-23) that harbors most pathogenic variants was associated with a severe phenotype [Lavillaureix et al 2017].
- Somatic and germline mosaicism were reported in the asymptomatic father of two affected children [Putnam et al 1997].

## Genotype-Phenotype Correlations

No genotype-phenotype correlations have been documented to date.

Some case reports claim a more severe phenotype for deletions [Lavillaureix et al 2017] or splice site variants in the central region of the gene (exons 24-35) (this remains unconfirmed) [Wang et al 1996]. In addition, phenotypic variability between and within families is wide, independent of the variant type (splice site or missense) [Callewaert et al 2009].

Meerschaut et al [2020] state that individuals with a confirmed *FBN2* (likely) pathogenic variant have a higher clinical score (Table 2) than those without an *FBN2* (likely) pathogenic variant ( $P < 0.001$ ). Nevertheless, persons without an *FBN2* (likely) pathogenic variant but with a clinical score as high as 19 have been reported, making it impossible to clinically differentiate between individuals with and without an *FBN2* (likely) pathogenic variant.

## Penetrance

The penetrance for CCA is likely up to 100%, but some disease manifestations, including the ear and joint manifestations, may become less obvious with age. Nevertheless, upon careful examination, less than 1.2% of the variability of the clinical score (Table 2) could be attributed to age [Meerschaut et al 2020]. Indeed, a previous report indicates that the diagnosis was often retrospectively made in one parent of a proband due to mild features still evident in adulthood (mild contractures without any functional impairment and/or prominent helical crus and anterior antihelical crus ["tram track" ears]) [Callewaert et al 2009]. In addition, long-bone overgrowth and scoliosis may become more prominent with age.

Clinical manifestations are the same in males and females.

## Nomenclature

Congenital contractural arachnodactyly (CCA) has been referred to as distal arthrogyrosis type 9 (OMIM 121050). This term should be avoided as it puts too much emphasis on the distal contractures while minimizing the significance of other manifestations, including marfanoid habitus, proximal contractures, and aortic and ocular involvement.

## Prevalence

The prevalence is not known. To date about 70 probands with CCA have been described. Most described individuals are white, but this likely represents an ascertainment bias [Author, personal observation]. There is no reason to assume that CCA shows any specific geographic or ethnic predilection. Indeed, affected individuals from China [Chen et al 2009, Liu et al 2015, Guo et al 2016], Japan [Takeda et al 2015], India, and the Middle East [Callewaert et al 2009, Mehar et al 2014, Meerschaut et al 2020] have been described.

## Genetically Related (Allelic) Disorders

Rare contiguous gene deletions that include *FBN2* have been reported in children with variable phenotypic findings that include features of CCA in addition to failure to thrive, developmental delay, and anomalies of the central nervous system, eyes, and kidneys, and urinary tract (e.g., see Courtens et al [1998], Garcia-Miñaur et al [2005], Inbar-Feigenberg et al [2014]).

No other highly penetrant phenotypes are known to be caused by heterozygous *FBN2* pathogenic variants. Because all *FBN2* variants that cause CCA are clustered in a rather limited region of *FBN2*, one can hypothesize that pathogenic variants outside this region may cause disorders or syndromes not yet attributed to *FBN2*, or may have no phenotypic effect.

The following association remains to be confirmed: One individual homozygous for the *FBN2* variant c.41T>G (p.Leu14Arg) had clubfeet, obesity, myopathy, mild joint contractures, patellar dislocations, and gynecomastia. Creatinine kinase was normal [Monies et al 2017].

## Differential Diagnosis

Disorders with features that overlap with those of congenital contractural arachnodactyly (CCA) are summarized in Table 4.

**Table 4.** Disorders to Consider in the Differential Diagnosis of Congenital Contractural Arachnodactyly (CCA)

Differential Diagnosis Disorder	Gene	MOI	Clinical Features of Differential Diagnosis Disorder	
			Overlapping w/CCA	Distinguishing from CCA
Marfan syndrome	<i>FBN1</i>	AD	<ul style="list-style-type: none"> <li>Marfanoid habitus, dolichostenomelia</li> <li>Arachnodactyly</li> <li>Pectus deformity, kyphoscoliosis</li> <li>Muscle hypoplasia</li> <li>Large-joint contractures (mainly elbows)</li> <li>Severe Marfan syndrome<sup>1</sup> may be mistaken for severe CCA as both may have crumpled ears, contractures, &amp; cardiovascular abnormalities.<sup>2</sup></li> </ul>	<ul style="list-style-type: none"> <li>Lens (sub)luxation</li> <li>High myopia</li> <li>Progressive aortic root dilatation</li> <li>Absence of crumpled ears &amp; joint contractures<sup>3</sup></li> <li>Neonates w/severe Marfan syndrome are usually very hypotonic &amp; have valvular anomalies ("floppy valves") &amp;/or aortic root dilatation, rather than the septal defects or interrupted aortic arch in severe CCA.</li> <li>Differentiating Marfan syndrome &amp; CCA is most important given the severe cardiovascular complications &amp; cardiac monitoring essential in individuals w/Marfan syndrome.</li> </ul>
Loeys-Dietz syndrome	<i>SMAD2</i> <i>SMAD3</i> <i>TGFB2</i> <i>TGFB3</i> <i>TGFBR1</i> <i>TGFBR2</i>	AD	<ul style="list-style-type: none"> <li>Arachnodactyly</li> <li>Pectus deformity</li> </ul>	<ul style="list-style-type: none"> <li>Joint laxity</li> <li>Thin skin</li> <li>Hypertelorism, bifid uvula, cleft palate</li> <li>Pectus deformity, scoliosis</li> <li>(Progressive) aortic root dilatation – patent ductus arteriosus</li> </ul>

Table 4. continued from previous page.

Differential Diagnosis Disorder	Gene	MOI	Clinical Features of Differential Diagnosis Disorder	
			Overlapping w/CCA	Distinguishing from CCA
Stickler syndrome	<i>COL2A1</i> <i>COL9A1</i> <i>COL9A2</i> <i>COL9A3</i> <i>COL11A1</i> <i>COL11A2</i>	AD AR <sup>4</sup>	Marfanoid body habitus (in some affected individuals), but usually secondary to a shortened trunk, rather than long-bone overgrowth	<ul style="list-style-type: none"> <li>Joint laxity</li> <li>Early-onset &amp; rapidly progressive myopia w/↑ risk of cataract, &amp; retinal detachment</li> <li>Hearing loss (both conductive &amp; sensorineural)</li> <li>Midfacial underdevelopment &amp; cleft palate</li> <li>Mild spondyloepiphyseal dysplasia &amp;/or precocious arthritis</li> </ul>
Homocystinuria	<i>CBS</i>	AR	<ul style="list-style-type: none"> <li>Limited joint mobility</li> <li>Dolichostenomelia</li> <li>Arachnodactyly</li> <li>Kyphoscoliosis</li> </ul>	<ul style="list-style-type: none"> <li>Lens (sub)luxation</li> <li>Osteoporosis</li> <li>DD in some</li> <li>Predisposition to thromboembolism</li> </ul>
Distal arthrogryposes (DA) (OMIM <a href="#">PS108120</a> )	<i>ECEL1</i> <i>MYBPC1</i> <i>MYH3</i> <i>MYH8</i> <i>PIEZO2</i> <i>TNNI2</i> <i>TNNT3</i> <i>TPM2</i>	AD AR <sup>5</sup>	<ul style="list-style-type: none"> <li>Medially overlapping fingers</li> <li>Clenched fists</li> <li>Ulnar deviation of fingers</li> <li>Campodactyly</li> <li>Positional foot deformities</li> <li>Clubfoot</li> <li>Scoliosis</li> </ul>	<ul style="list-style-type: none"> <li>Absence of marfanoid habitus, arachnodactyly, contractures of knees &amp; elbows, &amp; crumpled ears</li> <li>Additional features depending on DA subtype</li> <li>Often pursed lips</li> </ul>
Bethlem myopathy (See <a href="#">Collagen Type VI-Related Disorders</a> & OMIM <a href="#">616471</a> .)	<i>COL6A1</i> <i>COL6A2</i> <i>COL6A3</i> <i>COL12A1</i>	AD AR	<ul style="list-style-type: none"> <li>Joint contractures</li> <li>Muscular hypoplasia</li> </ul>	Absence of marfanoid habitus, arachnodactyly, & crumpled ears
Van den Ende - Gupta syndrome (OMIM <a href="#">600920</a> )	<i>SCARF2</i>	AR	<ul style="list-style-type: none"> <li>Contractures</li> <li>Arachnodactyly</li> <li>Pectus excavatum</li> <li>Femoral bowing</li> </ul>	<ul style="list-style-type: none"> <li>Normal ears</li> <li>Interdigital webbing</li> <li>Cleft palate</li> <li>Craniosynostosis</li> </ul>
Bruck syndrome (OMIM <a href="#">259450</a> & <a href="#">609220</a> )	<i>FKBP10</i> <i>PLOD2</i>	AR	<ul style="list-style-type: none"> <li>Contractures</li> <li>Pectus deformity</li> <li>Bowed long bones</li> <li>Clubfeet</li> </ul>	<ul style="list-style-type: none"> <li>Osteopenia – fractures</li> <li>Absence of arachnodactyly</li> <li>Pterygia</li> </ul>
Congenital contractures of the limbs & face, hypotonia & DD (OMIM <a href="#">616266</a> )	<i>NALCN</i>	AD	<ul style="list-style-type: none"> <li>Contractures</li> <li>Hypotonia</li> <li>Micrognathia</li> <li>Scoliosis</li> </ul>	<ul style="list-style-type: none"> <li>DD</li> <li>Umbilical hernia</li> </ul>

AD = autosomal dominant; AR = autosomal recessive; DD = developmental delay; MOI = mode of inheritance

1. Neonatal Marfan syndrome is at the most severe end of the spectrum of Marfan syndrome.

2. In neonatal Marfan syndrome, cardiovascular abnormalities include mitral and tricuspid valve anomalies and dilated aorta. In severe/lethal CCA, cardiovascular abnormalities include atrial and/or ventricular septal defects and interrupted aortic arch.

3. Joint contractures are seen at birth in individuals with CCA.

4. Stickler syndrome caused by pathogenic variants *COL2A1*, *COL11A1*, or *COL11A2* is inherited in an autosomal dominant manner; Stickler syndrome caused by pathogenic variants in *COL9A1*, *COL9A2*, or *COL9A3* is inherited in an autosomal recessive manner.

5. Distal arthrogryposes is inherited in an autosomal dominant manner with the exception of *ECEL1*-related distal arthrogryposis, which is inherited in an autosomal recessive manner.

**Fetal akinesia sequence.** Any disorder resulting in fetal akinesia either through severe (central) nervous system impairment or mechanical constraint will result in neonatal contractures. These individuals may have ear deformities and a small jaw, but usually do not present with arachnodactyly. Therefore, a pregnancy history (oligohydramnios) and workup with a brain MRI is necessary to differentiate between possible causes of the contractures.

## Management

### Evaluations Following Initial Diagnosis

To establish the extent of disease in an individual diagnosed with congenital contractural arachnodactyly (CCA), the evaluations summarized in Table 5 (if not performed as part of the evaluation that led to the diagnosis) are recommended.

**Table 5.** Recommended Evaluations Following Initial Diagnosis in Individuals with Classic Congenital Contractural Arachnodactyly

System/Concern	Evaluation	Comment
<b>Musculoskeletal</b>	Orthopedics: joint contractures, bowed long bones; kyphoscoliosis	Kyphoscoliosis may be congenital, is progressive, & warrants early eval.
	Assessment by physiatrist, OT/PT of fine motor & gross motor skills related to contractures & muscular hypotonia	
<b>Cardiovascular</b>	Assessment for aortic root dilatation	The risk for aortic root dilatation is low & progression uncommon; but assessing aortic root dilatation at an early stage is important for determining frequency of further cardiovascular follow up.
<b>Ophthalmologic</b>	Flat cornea / keratoconus	Low risk
<b>Orthodontic</b>	Highly arched palate, dental crowding	A highly arched palate is also assoc w/↑ incidence of middle ear infections.
<b>Miscellaneous/ Other</b>	Consultation w/clinical geneticist &/or genetic counselor	

OT = occupational therapy; PT = physical therapy

**Table 6.** Recommended Evaluations Following Initial Diagnosis in Infants with Severe Congenital Contractural Arachnodactyly

System/Concern	Evaluation	Comment
<b>Constitutional</b>	Assess nutritional status, growth.	
<b>Musculoskeletal</b>	Orthopedics: joint contractures, bowed long bones; kyphoscoliosis	Kyphoscoliosis is congenital, progressive, & warrants early eval.
	Assessment by physiatrist, OT/PT of fine motor & gross motor skills related to contractures & muscular hypotonia	
<b>Cardiovascular</b>	Assess for congenital heart disease.	Commonly atrial or ventricular septal defect, interrupted aortic arch; rarely aortic root dilatation. Valvular insufficiency may occur.
<b>Gastrointestinal/ Feeding</b>	Assess for GI malformation: a "double bubble" sign on abdominal ultrasound is indicative of a duodenal atresia/obstruction.	Duodenal or esophageal atresia & intestinal malrotation

Table 6. continued from previous page.

System/Concern	Evaluation	Comment
<b>Respiratory</b>	Assess for respiratory insufficiency.	Most common cause of death, often resulting from tracheomalacia (due to pressure from vascular anomalies) & respiratory infections. It is unclear if hypotonia, emphysema, &/or left-sided congestive heart failure may contribute to the respiratory problems.
<b>Ophthalmologic</b>	Flat cornea / keratoconus	Low risk
<b>Miscellaneous/ Other</b>	Consultation w/clinical geneticist &/or genetic counselor	

OT = occupational therapy; PT = physical therapy

## Treatment of Manifestations

Table 7. Treatment of Manifestations in Individuals with Classic Congenital Contractural Arachnodactyly

Manifestation/ Concern	Treatment	Considerations/Other
<b>Musculoskeletal</b>	By orthopedist	<ul style="list-style-type: none"> <li>Contractures may require surgical release.</li> <li>Clubfeet may require casting.</li> <li>Progressive kyphoscoliosis may require bracing &amp;/or surgical intervention.</li> </ul>
	By physiatrist, OT/PT	<ul style="list-style-type: none"> <li>Early PT in children helps ↑ joint mobility &amp; counteract muscle hypoplasia (usually calf muscles).</li> <li>Camptodactyly &amp; large-joint contractures may spontaneously improve over time.</li> <li>Swimming reinforces the musculature w/out taxing joints.</li> <li>Cycling may benefit those w/patellar hypermobility by ↓ risk for patellar luxation.</li> </ul>
<b>Cardiovascular</b>	By cardiologist/ cardiovascular surgeon	Aortic root dilatation is managed in a standard manner. See <a href="#">Marfan Syndrome</a> & Milewicz et al [2005] ( <a href="#">full text</a> ).
<b>Ophthalmologic</b>	By ophthalmologist	<ul style="list-style-type: none"> <li>Correction of refractive errors</li> <li>Keratoconus can be treated by scleral contact lenses. It is currently unknown if corneal crosslinking is safe &amp;/or useful in CCA.</li> </ul>
<b>Orthodontic</b>	By orthodontist/dentist	<ul style="list-style-type: none"> <li>Use of palatal expander may be indicated.</li> <li>Dental crowding may necessitate extraction of molars.</li> </ul>

OT = occupational therapy; PT = physical therapy

Table 8. Treatment of Manifestations in Individuals with Severe/Lethal CCA

Manifestation/ Concern	Treatment	Considerations/Other
<b>Musculoskeletal</b>	By orthopedist	<ul style="list-style-type: none"> <li>Contractures may require surgical release.</li> <li>Clubfeet may require casting.</li> <li>Progressive kyphoscoliosis may require bracing &amp;/or surgical intervention.</li> <li>Severe pectus excavatum may rarely cause restrictive lung disease or cardiac displacement &amp; thus require surgical treatment (Nüss procedure).</li> </ul>
	By physiatrist, OT/PT	<ul style="list-style-type: none"> <li>Early PT in children helps ↑ joint mobility &amp; improve muscle hypoplasia (usually calf muscles).</li> <li>Camptodactyly &amp; large-joint contractures may spontaneously improve over time.</li> </ul>

Table 8. continued from previous page.

Manifestation/Concern	Treatment	Considerations/Other
<b>Cardiovascular</b>	By cardiologist / cardiovascular surgeon	<ul style="list-style-type: none"> <li>Hypoplastic aortic arch or interrupted aortic arch, a ductus-dependent heart defect, requires intervention shortly after birth (incl prostaglandins while awaiting surgery).</li> <li>For septal defects, treatment is either conservative (by percutaneous closure) or surgical following standard guidelines.</li> <li>Aortic root dilatation is managed in a standard manner. See <a href="#">Marfan Syndrome &amp; Milewicz et al [2005]</a> (full text).</li> </ul>
<b>Gastrointestinal</b>	By abdominal/ pediatric surgeon	<ul style="list-style-type: none"> <li>Surgical correction of malrotation if symptomatic (vomiting)</li> <li>Surgical correction of esophageal or duodenal atresia</li> </ul>
<b>Ophthalmologic</b>	By ophthalmologist	<ul style="list-style-type: none"> <li>Correction of refractive errors</li> <li>Keratoconus can be treated by contact lenses. It is currently unknown if corneal crosslinking is safe &amp;/or useful in CCA.</li> </ul>
<b>Respiratory</b>	By neonatologist/ pulmonologist/ anesthesiologist	<ul style="list-style-type: none"> <li>Tracheomalacia requires bronchoscopy &amp;/or vascular imaging to determine cause &amp; best treatment options.</li> <li>Aggressive treatment of pulmonary infections</li> <li>Respiratory physiotherapy may be necessary in case of severe hypotonia &amp; reduced coughing.</li> <li>As it is unclear if pulmonary emphysema may develop, positive pressure ventilation should be kept to a minimum.</li> </ul>

OT = occupational therapy; PT = physical therapy

## Surveillance

Table 9. Recommended Surveillance for Individuals with Classic Congenital Contractural Arachnodactyly

System/Concern	Evaluation	Frequency
<b>Musculoskeletal</b>	If not present at initial eval: evaluate for kyphosis/scoliosis clinically.	At least annually
	If present at initial eval: monitor kyphosis/scoliosis (clinically &/or radiologically).	Per treating orthopedist
<b>Cardiovascular</b>	Measurement of aortic root diameter for evidence of aortic dilatation	Every 2 yrs until end of puberty; then every 3-5 yrs if aortic measurements are well below upper limit for age, sex, & body surface area (z-score <2) & no major valvular involvement (mitral valve prolapse)
<b>Ocular</b>	Visual acuity & assessment of refractive error	Upon clinical guidance (or at least every 2 yrs in young children)
	Keratometry	Every 3 yrs, especially in those w/difficult-to-correct refractive errors
<b>Orthodontic</b>	From age 8 yrs	Annually

## Agents/Circumstances to Avoid

Avoid contact sports and activities that stress joints. Individuals should remain active but avoid high-intensity aerobic activities.

LASIK eye surgery may increase the risk for keratoconus in individuals with predisposing ocular conditions.

## Evaluation of Relatives at Risk

It is appropriate to clarify the genetic status of apparently asymptomatic or self-reportedly asymptomatic at-risk relatives of an affected individual. Some parents have been unaware of their clinical status. In those individuals, evaluation of their status is necessary to reveal a low but potential risk for aortic and/or ocular complications.

Evaluations can include:

- Molecular genetic testing if the pathogenic variant in the family is known;
- Clinical evaluation if the pathogenic variant in the family is not known.

See Genetic Counseling for issues related to testing of at-risk relatives for genetic counseling purposes.

## Pregnancy Management

There are no reported complications related to pregnancy or delivery in females with CCA. It is advisable to perform an echocardiography preconceptually and to increase cardiac surveillance during pregnancy in women with dilatation of the aortic root.

## Therapies Under Investigation

Search [ClinicalTrials.gov](https://clinicaltrials.gov) in the US and [EU Clinical Trials Register](https://clinicaltrialsregister.eu) in Europe for access to information on clinical studies for a wide range of diseases and conditions. Note: There may not be clinical trials for this disorder.

## Genetic Counseling

*Genetic counseling is the process of providing individuals and families with information on the nature, mode(s) of inheritance, and implications of genetic disorders to help them make informed medical and personal decisions. The following section deals with genetic risk assessment and the use of family history and genetic testing to clarify genetic status for family members; it is not meant to address all personal, cultural, or ethical issues that may arise or to substitute for consultation with a genetics professional. —ED.*

## Mode of Inheritance

Congenital contractural arachnodactyly (CCA) is inherited in an autosomal dominant manner.

## Risk to Family Members

### Parents of a proband

- Many individuals diagnosed with CCA have an affected parent.
- A proband with CCA may have the disorder as the result of a *de novo* *FBN2* pathogenic variant. The proportion of cases caused by a *de novo* pathogenic variant is unknown but likely nears 50% [Callewaert et al 2009; Callewaert, unpublished data].
- Molecular genetic testing (if the *FBN2* pathogenic variant in the proband has been identified) and physical examination are recommended for the parents of a proband with an apparent negative family history.
- If the *FBN2* pathogenic variant found in the proband cannot be detected in the leukocyte DNA of either parent, possible explanations include a *de novo* pathogenic variant in the proband or somatic/germline mosaicism in a parent; somatic/germline mosaicism has been suggested or confirmed in three families [Wang et al 1996, Putnam et al 1997, Callewaert et al 2009]. In one family, an *FBN2* pathogenic variant identified in two sibs was detectable in DNA derived from buccal cells and hair bulbs from the father, but not in DNA derived from paternal leukocytes [Putnam et al 1997].

- The family history of some individuals diagnosed with CCA may appear to be negative because of failure to recognize the disorder in family members. Therefore, an apparently negative family history cannot be confirmed unless appropriate clinical evaluation and/or molecular genetic testing has been performed on the parents of the proband.
- Note: If the parent is the individual in whom the *FBN2* pathogenic variant first occurred, the parent may have somatic mosaicism for the variant and may have a less severe phenotypic presentation than the proband. In one report, a mother with somatic and germline mosaicism had features of classic CCA, while her daughter, who inherited the *FBN2* pathogenic variant, had severe CCA with cardiovascular and gastrointestinal anomalies [Wang et al 1996].

**Sibs of a proband.** The risk to the sibs of the proband depends on the clinical/genetic status of the parents:

- If a parent of the proband has clinical features of CCA and/or is known to have the *FBN2* pathogenic variant identified in the proband, the risk to the sibs is 50%. Because intrafamilial clinical variability is observed in CCA, a heterozygous sib may have a more or less severe phenotypic presentation than the proband (see Genotype-Phenotype Correlations).
- If neither parent is clinically affected and if the *FBN2* pathogenic variant identified in the proband cannot be detected in the leukocyte DNA of either parent, the recurrence risk to sibs is slightly greater than that of the general population because of the possibility of parental germline mosaicism (confirmed or suspected germline mosaicism has been reported in three unrelated families; in one family, an unaffected father had two children with CCA) [Putnam et al 1997].

**Offspring of a proband.** Each child of an individual with CCA has a 50% chance of inheriting the *FBN2* pathogenic variant.

**Other family members.** The risk to other family members depends on the status of the proband's parents: if a parent is affected or has an *FBN2* pathogenic variant, the parent's family members are at risk.

## Related Genetic Counseling Issues

**Considerations in families with an apparent *de novo* pathogenic variant.** When neither parent of a proband with an autosomal dominant condition has the pathogenic variant identified in the proband or clinical evidence of the disorder, the pathogenic variant is likely *de novo*. However, non-medical explanations including alternate paternity or maternity (e.g., with assisted reproduction) and undisclosed adoption could also be explored.

### Family planning

- The optimal time for determination of genetic risk and discussion of the availability of prenatal/preimplantation genetic testing is before pregnancy.
- It is appropriate to offer genetic counseling (including discussion of potential risks to offspring and reproductive options) to young adults who are affected or at risk.

**DNA banking.** Because it is likely that testing methodology and our understanding of genes, pathogenic mechanisms, and diseases will improve in the future, consideration should be given to banking DNA from probands in whom a molecular diagnosis has not been confirmed (i.e., the causative pathogenic mechanism is unknown).

## Prenatal Testing and Preimplantation Genetic Testing

**Molecular genetic testing.** Once the *FBN2* pathogenic variant has been identified in an affected family member, prenatal testing and preimplantation genetic testing are possible.



**Fetal ultrasound examination.** While joint contractures may be identified by ultrasound examination of an at-risk fetus, a normal fetal ultrasound examination does not exclude the diagnosis of CCA.

**Note:** Prenatal suspicion of contractures without a known familial history of CCA can be complemented by fetal brain MRI and or prenatal molecular testing in order to differentiate between possible causes of contractures, mostly with the purpose of excluding disorders with central nervous system involvement such as fetal akinesia deformation sequence.

Differences in perspective may exist among medical professionals and within families regarding the use of prenatal testing. While most centers would consider use of prenatal testing to be a personal decision, discussion of these issues may be helpful.

## Resources

*GeneReviews staff has selected the following disease-specific and/or umbrella support organizations and/or registries for the benefit of individuals with this disorder and their families. GeneReviews is not responsible for the information provided by other organizations. For information on selection criteria, click [here](#).*

- **National Library of Medicine Genetics Home Reference**  
[Congenital contractural arachnodactyly](#)
- **Genetic Aortic Disorders Association (GADA) Canada**  
Centre Plaza Postal Outlet  
128 Queen Street South  
PO Box 42257  
Mississauga Ontario L5M 4Z0  
Canada  
**Phone:** 866-722-1722 (toll free); 905-826-3223  
**Email:** [info@gadacanada.ca](mailto:info@gadacanada.ca)  
[www.gadacanada.ca](http://www.gadacanada.ca)
- **National Marfan Foundation (NMF)**  
22 Manhasset Avenue  
Port Washington NY 11050  
**Phone:** 800-862-7326 (toll-free); 516-883-8712  
**Fax:** 516-883-8040  
**Email:** [staff@marfan.org](mailto:staff@marfan.org)  
[www.marfan.org](http://www.marfan.org)

## Molecular Genetics

*Information in the Molecular Genetics and OMIM tables may differ from that elsewhere in the GeneReview: tables may contain more recent information. —ED.*

**Table A.** Congenital Contractural Arachnodactyly: Genes and Databases

Gene	Chromosome Locus	Protein	Locus-Specific Databases	HGMD	ClinVar
<a href="#">FBN2</a>	<a href="#">5q23.3</a>	<a href="#">Fibrillin-2</a>	<a href="#">FBN2 @ LOVD</a>	<a href="#">FBN2</a>	<a href="#">FBN2</a>

Data are compiled from the following standard references: gene from [HGNC](#); chromosome locus from [OMIM](#); protein from [UniProt](#). For a description of databases (Locus Specific, HGMD, ClinVar) to which links are provided, click [here](#).

**Table B.** OMIM Entries for Congenital Contractural Arachnodactyly ([View All in OMIM](#))

121050	CONTRACTURAL ARACHNODACTYLY, CONGENITAL; CCA
612570	FIBRILLIN 2; FBN2

## Molecular Pathogenesis

*FBN2* encodes fibrillin-2, a large extracellular matrix protein that multimerizes in linear structures, called microfibrils. These calcium-binding structures have some intrinsic stretchiness, and can further associate with elastin to form elastic fibers. Microfibrils provide support in both elastic and non-elastic connective tissue, are involved in cell-matrix communication, and contribute to extracellular growth factor sequestration and regulation.

Fibrillin-2 is homologous to fibrillin-1, encoded by *FBN1* (pathogenic variants in which cause [Marfan syndrome](#)), but its expression begins earlier in embryonic development. Mouse studies have shown that fibrillin-1 may partially compensate for fibrillin-2 deficiency [Carta et al 2006] during embryonic development, at least in the aorta. In mice, contractures disappear around the time that fetal *fbn2* expression is replaced by postnatal *fbn1* expression. *Fbn2* is involved in murine limb patterning, and both *FBN1* and *FBN2* are expressed in bone and tendons and control bone growth and density, suggesting overlapping and diverse roles for *FBN1* and *FBN2* in TGF $\beta$  and BMP growth factor sequestration and bioavailability [Nistala et al 2010, Smaldone et al 2011].

Of note, disease-associated variants in *FBN2* are located in the central region of the gene (exons 24-35) encoding a central stretch of calcium-binding epidermal growth factor-like (cbEGF-like) domains. Pathogenic variants in the homologous central region of *FBN1* (also called the "neonatal" region) typically cause a more severe [Marfan syndrome](#) phenotype [Faivre et al 2009]. In contrast to fibrillin-1, however, only one reported fibrillin-2 missense variant, p.Gly925Arg, located outside this region, caused a classic CCA phenotype [Meerschaut et al 2020].

**Mechanism of disease causation.** Both dominant-negative and loss-of-function mechanisms may be at play in the pathogenesis. Most disease-associated variants are missense or splice site variants that cluster in the central region of the gene (exons 24-35, which encode a stretch of calcium-binding epidermal growth factor-like [cbEGF-like] domains) and result in an in-frame mutated gene product. In addition, in-frame multiexon deletions outside the central region of *FBN2* produce stably expressed mRNA. Since fibrillin-2 multimerizes in microfibrils, this suggests that most phenotypic effects of *FBN2* pathogenic variants result from a dominant-negative effect.

Nevertheless, identification of an *FBN2* nonsense variant and the 5q23.3 microdeletion syndrome encompassing *FBN2* in individuals with features reminiscent of CCA suggest that a loss-of-function mechanism may contribute to the disease mechanism.

**Table 10.** Notable *FBN2* Pathogenic Variants

Reference Sequences	DNA Nucleotide Change	Predicted Protein Change	Comment [Reference]
NM_001999.3	c.4346-2A>T		Severe CCA in a proband w/this heterozygous variant whose mother had classic CCA w/ mosaicism for the variant [Wang et al 1996]
	c.2773G>A	p.Gly925Arg	Located outside the <i>FBN1</i> homologous region but assoc w/severe phenotype [Meerschaut et al 2020]

Variants listed in the table have been provided by the author. *GeneReviews* staff have not independently verified the classification of variants.

*GeneReviews* follows the standard naming conventions of the Human Genome Variation Society ([varnomen.hgvs.org](http://varnomen.hgvs.org)). See [Quick Reference](#) for an explanation of nomenclature.

## Chapter Notes

### Author Notes

Dr Bert Callewaert ([bert.callewaert@ugent.be](mailto:bert.callewaert@ugent.be)) is actively involved in clinical research regarding individuals with congenital contractural arachnodactyly. He would be happy to communicate with persons who have any questions regarding diagnosis of congenital contractural arachnodactyly or other considerations.

Contact Dr Callewaert at [bert.callewaert@ugent.be](mailto:bert.callewaert@ugent.be) to inquire about the interpretation of *FBN2* variants of uncertain significance.

Dr Callewaert ([bert.callewaert@ugent.be](mailto:bert.callewaert@ugent.be)) is also interested in hearing from clinicians treating families affected by congenital contractural arachnodactyly in whom no causative variant has been identified through molecular genetic testing.

### Author History

Bert Callewaert, MD, PhD (2019-present)

Maurice Godfrey, PhD; University of Nebraska Medical Center (2001-2019)

### Revision History

- 14 July 2022 (bc) Revision: contact information for questions about congenital contractural arachnodactyly added to Author Notes
- 21 October 2019 (bp) Comprehensive update posted live
- 23 February 2012 (me) Comprehensive update posted live
- 4 May 2007 (me) Comprehensive update posted live
- 5 April 2006 (cd) Revision: *FBN2* testing clinically available
- 29 December 2004 (me) Comprehensive update posted live
- 5 February 2003 (me) Comprehensive update posted live
- 23 January 2001 (me) Review posted live
- June 2000 (mg) Original submission

## References

### Literature Cited

Callewaert BL, Loeys BL, Ficcadenti A, Vermeer S, Landgren M, Kroes HY, Yaron Y, Pope M, Foulds N, Boute O, Galán F, Kingston H, Van der Aa N, Salcedo I, Swinkels ME, Wallgren-Pettersson C, Gabrielli O, De

- Backer J, Coucke PJ, De Paepe AM. Comprehensive clinical and molecular assessment of 32 probands with congenital contractural arachnodactyly: report of 14 novel mutations and review of the literature. *Hum Mutat.* 2009;30:334–41. PubMed PMID: 19006240.
- Carmical SG, Gupta P, Milewicz DM, Putnam EA. FBN2 mutations identified in congenital contractural arachnodactyly patients with aortic root dilatation. *Am J Hum Genet.* 1999;65S:A6.
- Carta L, Pereira L, Arteaga-Solis E, Lee-Arteaga SY, Lenart B, Starcher B, Merkel CA, Sukoyan M, Kerkis A, Hazeki N, Keene DR, Sakai LY, Ramirez F. Fibrillins 1 and 2 perform partially overlapping functions during aortic development. *J Biol Chem.* 2006;281:8016–23. PubMed PMID: 16407178.
- Chen Y, Lei YP, Zheng HX, Wang W, Cheng HB, Zhang J, Wang HY, Jin L, Li H. A novel mutation (C1425Y) in the FBN2 gene in a father and son with congenital contractural arachnodactyly. *Genet Test Mol Biomarkers.* 2009;13:295–300. PubMed PMID: 19473076.
- Courtens W, Tjalma W, Messiaen L, Vamos E, Martin JJ, Van Bogaert E, Keersmaekers G, Meulyzer P, Wauters J. Prenatal diagnosis of a constitutional interstitial deletion of chromosome 5 (q15q31.1) presenting with features of congenital contractural arachnodactyly. *Am J Med Genet.* 1998;77:188–97. PubMed PMID: 9605585.
- Currarino G, Friedman JM. A severe form of congenital contractural arachnodactyly in two newborn infants. *Am J Med Genet.* 1986;25:763–73. PubMed PMID: 3789025.
- Faivre L, Collod-Beroud G, Callewaert B, Child A, Binquet C, Gautier E, Loeys BL, Arbustini E, Mayer K, Arslan-Kirchner M, Stheneur C, Kiotsekoglou A, Comeglio P, Marziliano N, Wolf JE, Bouchot O, Khau-Van-Kien P, Beroud C, Claustres M, Bonithon-Kopp C, Robinson PN, Adès L, De Backer J, Coucke P, Francke U, De Paepe A, Jondeau G, Boileau C. Clinical and mutation-type analysis from an international series of 198 probands with a pathogenic FBN1 exons 24–32 mutation. *Eur J Hum Genet.* 2009;17:491–501. PubMed PMID: 19002209.
- Garcia-Miñaur S, Ramsay J, Grace E, Minns RA, Myles LM, FitzPatrick DR. Interstitial deletion of the long arm of chromosome 5 in a boy with multiple congenital anomalies and mental retardation: molecular characterization of the deleted region to 5q22.3q23.3. *Am J Med Genet A.* 2005;132A:402–10. PubMed PMID: 15742475.
- Guo X, Song C, Shi Y, Li H, Meng W, Yuan Q, Xue J, Xie J, Liang Y, Yuan Y, Yu B, Wang H, Chen Y, Qi L, Li X. Whole exome sequencing identifies a novel missense FBN2 mutation co-segregating in a four-generation Chinese family with congenital contractural arachnodactyly. *BMC Med Genet.* 2016;17:91. PubMed PMID: 27912749.
- Gupta PA, Putnam EA, Carmical SG, Kaitila I, Steinmann B, Child A, Danesino C, Metcalfe K, Berry SA, Chen E, Delorme CV, Thong MK, Ades LC, Milewicz DM. Ten novel FBN2 mutations in congenital contractural arachnodactyly: delineation of the molecular pathogenesis and clinical phenotype. *Hum Mutat.* 2002;19:39–48. PubMed PMID: 11754102.
- Inbar-Feigenberg M, Meirowitz N, Nanda D, Toi A, Okun N, Chitayat D. Beals syndrome (congenital contractural arachnodactyly): prenatal ultrasound findings and molecular analysis. *Ultrasound Obstet Gynecol.* 2014;44:486–90. PubMed PMID: 24585410.
- Lavillaureix A, Heide S, Chantot-Bastaraud S, Marey I, Keren B, Grigorescu R, Jouannic JM, Gelot A, Whalen S, Héron D, Siffroi JP. Mosaic intragenic deletion of FBN2 and severe congenital contractural arachnodactyly. *Clin Genet.* 2017;92:556–8. PubMed PMID: 28762477.
- Lipson EH, Viseskul C, Herrmann J. The clinical spectrum of congenital contractural arachnodactyly. A case with congenital heart disease. *Z Kinderheilkd.* 1974;118:1–8. PubMed PMID: 4432555.
- Liu W, Zhao N, Li XF, Wang H, Sui Y, Lu YP, Feng WH, Ma C, Han WT, Jiang M. A novel FBN2 mutation in a Chinese family with congenital contractural arachnodactyly. *FEBS Open Bio.* 2015;5:163–6. PubMed PMID: 25834781.

- Loeys BL, Dietz HC, Braverman AC, Callewaert BL, De Backer J, Devereux RB, Hilhorst-Hofstee Y, Jondeau G, Faivre L, Milewicz DM, Pyeritz RE, Sponseller PD, Wordsworth P, De Paepe AM. The revised Ghent nosology for the Marfan syndrome. *J Med Genet.* 2010;47:476–85. PubMed PMID: 20591885.
- Macnab AJ, D'Orsogna L, Cole DE, Baguley PE, Adderley RJ, Patterson MW. Cardiac anomalies complicating congenital contractural arachnodactyly. *Arch Dis Child.* 1991;66:1143–6. PubMed PMID: 1750764.
- Meena JP, Gupta A, Mishra D, Juneja M. Beals-Hecht syndrome (congenital contractural arachnodactyly) with additional craniospinal abnormality: a case report. *J Pediatr Orthop B.* 2015;24:226–9. PubMed PMID: 25493702.
- Meerschaut I, De Coninck S, Steyaert W, Barnicoat A, Bayat A, Benedicenti F, Berland S, Blair EM, Breckpot J, de Burca A, Destrée A, García-Miñaur S, Green AJ, Hanna BC, Keymolen K, Koopmans M, Lederer D, Lees M, Longman C, Lynch SA, Male AM, McKenzie F, Migeotte I, Mihci E, Nur B, Petit F, Piard J, Plasschaert FS, Rauch A, Ribai P, Pacheco IS, Stanzial F, Stolte-Dijkstra I, Valenzuela I, Varghese V, Vasudevan PC, Wakeling E, Wallgren-Pettersson C, Coucke P, De Paepe A, De Wolf D, Symoens S, Callewaert B. A clinical scoring system for congenital contractural arachnodactyly. *Genet Med.* 2020;22:124–31. PubMed PMID: 31316167.
- Mehar V, Yadav D, Kumar R, Yadav S, Singh K, Callewaert B, Pathan S, De Paepe A, Coucke PJ. Congenital contractural arachnodactyly due to a novel splice site mutation in the FBN2 gene. *J Pediatr Genet.* 2014;3:163–6. PubMed PMID: 27625873.
- Milewicz DM, Dietz HC, Miller DC. Treatment of aortic disease in patients with Marfan syndrome. *Circulation.* 2005;111:e150–7. PubMed PMID: 15781745.
- Monies D, Maddirevula S, Kurdi W, Alanazy MH, Alkhalidi H, Al-Owain M, Sulaiman RA, Faqeih E, Goljan E, Ibrahim N, Abdulwahab F, Hashem M, Abouelhoda M, Shaheen R, Arold ST, Alkuraya FS. Autozygosity reveals recessive mutations and novel mechanisms in dominant genes: implications in variant interpretation. *Genet Med.* 2017;19:1144–50. PubMed PMID: 28383543.
- Nishimura A, Sakai H, Ikegawa S, Kitoh H, Haga N, Ishikiriyama S, Nagai T, Takada F, Ohata T, Tanaka F, Kamasaki H, Saito H, Mizuguchi T, Matsumoto N. FBN2, FBN1, TGFBR1, and TGFBR2 analyses in congenital contractural arachnodactyly. *Am J Med Genet.* 2007;143A:694–8. PubMed PMID: 17345643.
- Nistala H, Lee-Arteaga S, Smaldone S, Siciliano G, Carta L, Ono RN, Sengle G, Arteaga-Solis E, Levasseur R, Ducy P, Sakai LY, Karsenty G, Ramirez F. Fibrillin-1 and -2 differentially modulate endogenous TGF- $\beta$  and BMP bioavailability during bone formation. *J Cell Biol.* 2010;190:1107–21. PubMed PMID: 20855508.
- Park ES, Putnam EA, Chitayat D, Child A, Milewicz DM. Clustering of FBN2 mutations in patients with congenital contractural arachnodactyly indicates an important role of the domains encoded by exons 24 through 34 during human development. *Am J Med Genet.* 1998;78:350–5. PubMed PMID: 9714438.
- Putnam EA, Park ES, Aalfs CM, Hennekam RC, Milewicz DM. Parental somatic and germ-line mosaicism for a FBN2 mutation and analysis of FBN2 transcript levels in dermal fibroblasts. *Am J Hum Genet.* 1997;60:818–27. PubMed PMID: 9106527.
- Renard M, Francis C, Ghosh R, Scott AF, Witmer PD, Adès LC, Andelfinger GU, Arnaud P, Boileau C, Callewaert BL, Guo D, Hanna N, Lindsay ME, Morisaki H, Morisaki T, Pachter N, Robert L, Van Laer L, Dietz HC, Loeys BL, Milewicz DM, De Backer J. Clinical validity of genes for heritable thoracic aortic aneurysm and dissection. *J Am Coll Cardiol.* 2018;72:605–15. PubMed PMID: 30071989.
- Siddiqui S, Panesar L. Persistent great artery dilatation in Beals syndrome: A novel finding. *Ann Pediatr Cardiol.* 2019;12:150–2. PubMed PMID: 31143044.
- Smaldone S, Carta L, Ramirez F. Establishment of fibrillin-deficient osteoprogenitor cell lines identifies molecular abnormalities associated with extracellular matrix perturbation of osteogenic differentiation. *Cell Tissue Res.* 2011;344:511–7. PubMed PMID: 21538048.

- Snape KM, Fahey MC, McGillivray G, Gupta P, Milewicz DM, Delatycki MB. Long-term survival in a child with severe congenital contractural arachnodactyly, autism and severe intellectual disability. *Clin Dysmorphol*. 2006;15:95–9. PubMed PMID: 16531736.
- Takeda N, Morita H, Fujita D, Inuzuka R, Taniguchi Y, Imai Y, Hirata Y, Komuro I. Congenital contractural arachnodactyly complicated with aortic dilatation and dissection: case report and review of literature. *Am J Med Genet A*. 2015;167A:2382–7. PubMed PMID: 25975422.
- Wang M, Clericuzio CL, Godfrey M. Familial occurrence of typical and severe lethal congenital contractural arachnodactyly caused by missplicing of exon 34 of fibrillin-2. *Am J Hum Genet*. 1996;59:1027–34. PubMed PMID: 8900230.

## License

GeneReviews® chapters are owned by the University of Washington. Permission is hereby granted to reproduce, distribute, and translate copies of content materials for noncommercial research purposes only, provided that (i) credit for source (<http://www.genereviews.org/>) and copyright (© 1993-2024 University of Washington) are included with each copy; (ii) a link to the original material is provided whenever the material is published elsewhere on the Web; and (iii) reproducers, distributors, and/or translators comply with the [GeneReviews® Copyright Notice and Usage Disclaimer](#). No further modifications are allowed. For clarity, excerpts of GeneReviews chapters for use in lab reports and clinic notes are a permitted use.

For more information, see the [GeneReviews® Copyright Notice and Usage Disclaimer](#).

For questions regarding permissions or whether a specified use is allowed, contact: [admasst@uw.edu](mailto:admasst@uw.edu).